

Microcystic Lymphatic Malformation of Tongue-A Case Report

Nishath Khanum, MDS^{1*}, Smitha JD, MDS² and Santosh Kanwar, MDS³

Affiliation:

¹Assistant Professor, Mustaqbal University, Saudi Arabia

²Senior Dental Health Officer, General Hospital, Gundlupet, India

³Senior Lecturer, Farooqia Dental College and Hospital, Mysore, India

*Corresponding Author: Nishath Khanum, MDS, Assistant Professor, Mustaqbal University, Saudi Arabia.

Received: February 25, 2021 Published: March 04, 2021

Abstract:

Lymphangiomas are benign malformations of the lymphatic system that show marked predilection for head and neck region and rarely occur in the oral cavity. The most common intraoral site of lymphatic malformations (LM) is the dorsum of tongue, where they often result in macroglossia leading to dysphagia, speech disturbances, difficulty in breathing and also mandibular prognathism and malocclusion. Though majority of cases can be initially diagnosed by a thorough history and examination, further investigations may be necessary to determine the extent of the disease. Here we report a case of superficial microcystic lymphatic malformation of the tongue in a 25-year-old female patient, which was associated with recurrent pain and swelling of the tongue. Magnetic Resonance Imaging (MRI) revealed the presence of another cystic lesion at the base of the tongue.

Keywords: Lymphatic malformation, Lymphangioma, tongue, macroglossia, MRI.

Introduction

Lymphangiomas are benign, malformations of the lymphatic system first described by Virchow in 1854. [1] The malformation arise from segregation of lymphatic tissue that do not communicate normally with the lymphatic system. [2] Lymphatic malformations can occur throughout the body, but are most common in the head and neck region. Depending on the location and extent of involvement of the local anatomic structure, the symptoms may include dysphagia, speech disturbances and airway obstruction. [3] Thorough evaluation and proper investigations are necessary to rule out the presence of deep-seated lesions that may pose a problem to the patient, as noted in the present case.

Case Report

A female patient aged about 25 years presented with a chief complaint of pain in her tongue since one month. Pain was mild, intermittent and localized and aggravated on consuming cold substances and relieved on taking medications prescribed by a general medical practitioner. Patient gave history of recurrent episodes of pain and swelling of her tongue since childhood. The swelling and pain initiate on consumption of cold substances, last for about 1 week and gradually subside after taking medications. Pain and swelling are associated with restricted tongue movements, difficulty in chewing and swallowing food, and difficulty in breathing. Patient also gave history of change in color of her tongue associated with the swelling. Her medical history was significant, in that she gave history of seizures since two years and was on Phenobarbitone 60 mg and Pregabid NT (Pregabalin 75mg, Nortriptyline 10mg) for the same. Patient also claimed that the last epileptic episode she had was around one-year ago. On physical examination, the patient was in good general condition and good nutrition state, without signs of obstruction of the superior respiratory tract.

On intraoral examination, a diffuse swelling was seen on the anterior 2/3rd of the tongue with numerous granular lesions, smooth, glossy, vesicle-like conglomerate affecting the anterior two third and posterior one third of the tongue including the tip, dorsal and lateral surfaces, with lesser involvement of the ventral surface.

The color of the lesions ranged from pale pink to purple. A linear fissure was seen in the centre of the anterior one third of the tongue (Figure – 1). Crenations were noted at the lateral borders and tip of the tongue, with no restrictions in the movement. On palpation, it was soft to firm in consistency, mildly tender with a pebbly surface and no discharge was elicited. Diascopy test performed on the lesion showed blanching, which suggested it to be of vascular origin. Based on the history and clinical examination a provisional diagnosis of Lymphatic malformation of tongue was made.

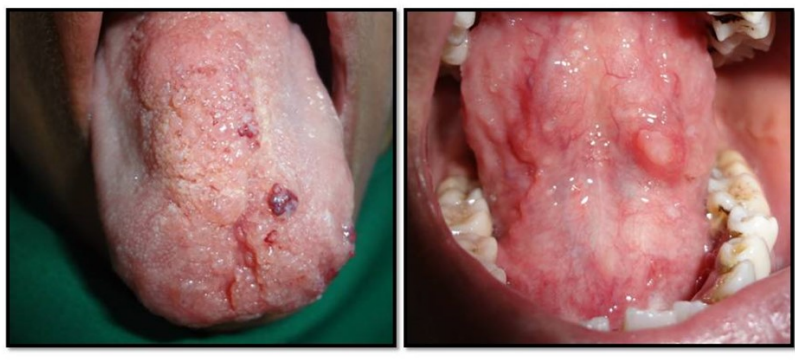

Figure – 1: Microcystic Lymphatic malformation involving the dorsal and ventral surface of the tongue.

Ultrasonograph of the tongue demonstrated the presence of a soft tissue mass situated within the submucosa of the dorsum of the tongue measuring about 2.6 X 0.7 cms with no evidence of vasculature noted within the mass (Figure – 2).

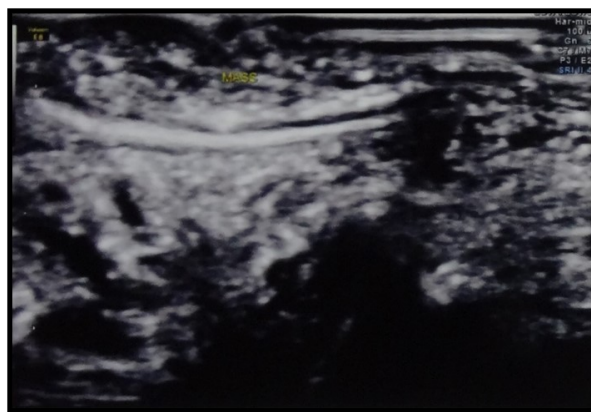


Figure – 2: Ultrasound image of the tongue showing the presence of soft tissue mass.

MRI showed mild soft tissue thickening of the dorsum of tongue, which appeared slightly hyperintense on T2 images. An irregular soft tissue mass measuring 2.2 X 2.1 cm was noted in the posterior ventral surface or base of the tongue, which appeared hypointense on T1 and hyperintense on T2 images (Figure – 3). This suggests the presence of microcystic lymphatic malformation of the dorsal surface of tongue along with the presence of a cystic lesion near the base of tongue.

The patient was not willing for any invasive treatment. During follow up, for a period of one year she had two episodes of pain and swelling in her tongue, which subsided on taking Cefpodoxime 100mg/5 ml oral suspension and cold syrup containing Chlorpheniramine maleate 2mg, Paracetamol 250mg, Phenylephrine 5mg /5 ml prescribed to her by a medical practitioner.

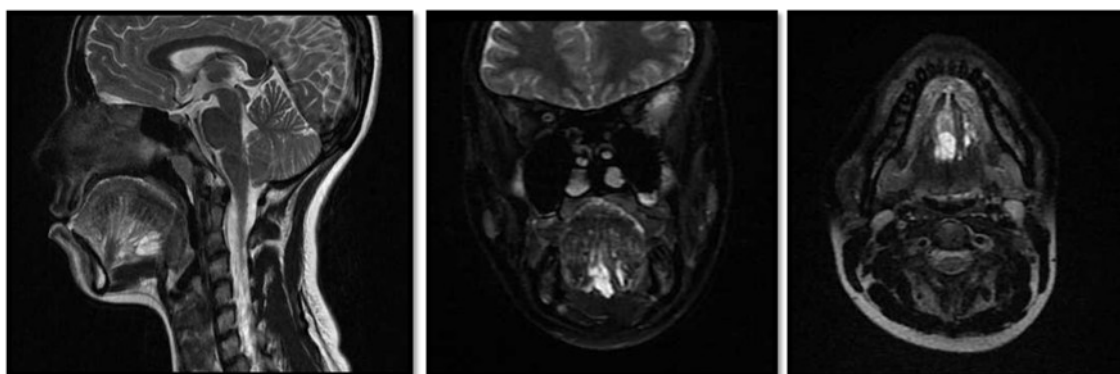


Figure –3: T2 weighted Sagittal, Coronal and Axial Images showing the dorsal thickening and presence of soft tissue mass near the base of the tongue.

Discussion and Conclusion

Lymphatic malformations represent developmental malformations of the lymphatic system that have a marked predilection for the head and neck, accounting for 50% to 75% of all cases. Based on histologic appearance four types of lymphangiomas have been described. [4]

- a) Lymphangioma simplex or capillary lymphangioma,
- b) Cavernous lymphangioma,
- c) Cystic lymphangioma or cystic hygroma and
- d) Benign lymphangi endothelioma or acquired progressive lymphangioma.

However, radiologically and histologically, they are characterized as microcystic (cavities less than 2cm³), macrocystic (cavities larger than 2cm³), or combined.[5] The microcystic LM were called lymphangiomas and macrocystic LM were called cystic hygromas, these terms are antiquated and should be avoided.[6]

Wiegand S et al [7] have classified the microcystic lymphatic malformations of the tongue into four stages depending on the extent of the lesion.

1. Stage I - Superficial microcystic lymphatic malformations of the tongue
2. Stage II - Lymphatic malformations of the tongue with muscle involvement
(Stage IIA, involving a part of the tongue; stage IIB, involving the entire tongue);
3. Stage III - Microcystic lymphatic malformations of the tongue and the floor of mouth
4. Stage IV - Extensive microcystic lymphatic malformations involving the tongue, floor of mouth, and further cervical structures.

Microcystic lymphatic malformations can occur at any site in the oral cavity, but most commonly involve the dorsum of the tongue, where they often result in macroglossia. They demonstrate a characteristic pebbly surface, resembling a cluster of translucent vesicles similar to the appearance of frog eggs or tapioca pudding. Deeper lesions present as soft, ill-defined masses. [2], [8] The other sites of involvement are the palate, buccal mucosa, gingiva and lip. Spontaneous regression of lymphangiomas is rare, and usually there is dilatation of the lymphatic channels with each episode of infection leading to progressive swelling of the tongue as seen in the present case.

Imaging of the superficial microcystic lymphatic malformations is also essential to rule out the presence of other deep seated macrocystic lesions such as that observed in our case. To determine the extent of the lesion magnetic resonance imaging is the method of choice. Lymphatic malformations demonstrate increased signal intensity on T2-weighted images, whereas their signal intensity is usually similar or slightly less than that of muscles in T1-weighted images. [7]

The management of microcystic lymphatic malformations of the tongue is challenging because of the increased incidence of postsurgical recurrence, and also the presence of combined lesions further complicates the treatment. The therapeutic goal should be to counter functional restrictions, avoid complications such as internal hemorrhage or super infections, and to achieve a satisfactory aesthetic result.

References

1. Usha V, Sivasankari T, Jeelani S, Asokan GS, Prathiban J. Lymphangioma of the tongue – A case report and review of literature. *J Clin Diagn Res* 2014; 8(9):12-14.
2. Neville BW, Damm DD, Allen CM, Bouquot JE. *Soft Tissue Tumors*. In: Neville BW (Ed). *Oral and Maxillofacial pathology*. 3rd edition. Philadelphia: W.B.Saunders 2009; pp547-549.
3. Cheng L-H, Lee J-C, Kao C-H, Shi Z-P, Lin Y-S. Lymphangiomatous macroglossia associated with extensive cervicome-diastinal cystic hygromas. *J Chin Med Assoc* 2013; 76:653-656.
4. Kheur SM, Routray S, Ingale Y, Desai RS. Lymphangioma of tongue: A rare entity. *IJDA* 2011; 3(3):635-637.
5. Ganesh C, Sangeetha GS, Narayanan V, Umamaheshwari TN. Lymphangioma Circumscriptum in an Adult: An Unusual Oral Presentation. *J Clin Imaging Sci* 2013; 3(4):1-4.
6. Marler JJ, Mulliken JB. Current management of hemangiomas and vascular malformations. *Clin Plastic Surg* 2005; 32:99 – 116.

7. Wiegand S, Eivazi B, Annette P, Zimmermann, Neff A, Barth PJ et al. Microcystic Lymphatic Malformations of the Tongue. Arch Otolaryngol Head Neck Surg 2009;135(10):976-983.
8. Sunil S, Gopakumar D, Sreenivasan BS. Oral Lymphangiomas – Case reports and review of literature. Contemp Clin Dent 2012; 3:116-8.

Citation: Nishath Khanum, Smitha JD, and Santosh Kanwar. “Microcystic Lymphatic Malformation of Tongue-A Case Report”. SVOA Dentistry 2:2 (2021) pages 67-70.

Copyright: © 2021 All rights reserved by Nishath Khanum, et al. This is an open access article distributed under the Creative Commons Attribution License, which permits unrestricted use, distribution, and reproduction in any medium, provided the original work is properly cited.