

# Immediate Implant Placement and Double Layer Socket Preservation Associated with Mix of Xenograft and Particulate Autogenous Bone Graft: A Case Report

Gabriel Marques Bezerra<sup>4</sup>, Bruno Santana Freitas<sup>4</sup>, Lucas Alves Ferreira<sup>3</sup>, Sergio Charifker Ribeiro Martins<sup>1</sup>, José Ricardo Mariano<sup>2</sup> and Leandro Lécio de Lima Sousa<sup>1</sup>

## Affiliation

<sup>1</sup> Universidade Guarulhos, Brazil

<sup>2</sup> Universidade São Leopoldo Mandic, Brazil

<sup>3</sup> Universidade Sete Lagoas - FACSET, Brazil

<sup>4</sup> Funorte - Faculdades Integradas do Norte de Minas, Brazil

**Corresponding Author:** Leandro Lécio de Lima Sousa, Rua Ernesto de Paula Santos, 187 - Segundo Andar, Edifício Empresarial Excelsior, Boa Viagem, Recife, Brazil- PE, Phone: 51021-030

**Received:** April 27, 2021 **Published:** May 08, 2021

## Abstract:

Alveolar preservation after tooth extraction is still one of the most important subjects in dentistry, due to the interest in future rehabilitations with or without implant-supported rehabilitation of missing elements. The present paper reports a case of failing right upper first bicuspid and immediate placement of dental implant, associated with graft and double layer membrane/barrier for the alveolar architecture maintenance. After tomographic analysis, it was chosen, in consensus with the patient, the removal of the failing tooth and immediate implantation and reconstruction with xenograft associated with autologous particulated graft. The use of xenograft associated with autologous bone promote both osseconduction and osseinduction, potentializing the neobone formation. The use of this graft mix under type III collagen membrane and dense polytetrafluoroethylene (d-PTFE) barrier, guarantee that inside the fresh alveolus will form a great quantity of bone. Following the results of studies and research on the subject of preservation of the alveolar ridge by the use of a double membrane, it is concluded that when this technique is applied, there is greater preservation of the alveolar bone ridge and maintenance of the bone volume, important factors for good peri-implant health and greater survival of the immediate implant.

**Keywords:** Ridge preservation; double layer; collagen membrane; d-PTFE; Immediate implants.

## Introduction

The search for alveolar preservation after extraction is still one of the subjects constantly researched in dentistry. Its importance is due to the search to reduce bone remodeling after extraction, since the interest in maintaining sufficient air-cabin for future re-habilitation through implant-supported restorations or not (Oliveira et al., 2018, Ashman, 1995 & Bartee, 2001).<sup>1, 2, 3</sup>

The resorption of the alveolus refers to the remodeling that occurs after the extraction of the dental element, this process of natural repair of the alveolus occurs when there is local tissue damage and, from this damage, there is a series of tissue changes causing a visible reduction in the volume of adjacent tissues and that are related to the loss of function of the alveolar bone. According to **Schropp and co-workers in 2003**, the first year after an extraction is the period of greatest bone resorption with dimensional changes of up to 50% of the alveolar bone crest, and the first three months of that year are those of greatest osteoclastic activity.<sup>4, 5, 6</sup>

Many researches papers describes that the resorption pattern does not occur equally or similarly in all regions of the maxilla or mandible. However, if we consider the bone characteristics of the anterior region of the maxilla, where we commonly find a thin buccal wall <1.0 mm, as well as its great aesthetic relevance, bone remodeling, although statistically smaller, would be critical, as it would interfere directly in the future rehabilitation with implant-supported restorations and in the white and pink aesthetics of the region. Moreover, important factors whether local or systemic, may alter the resorption process, with variations between patients, such as the presence of infections, previous periodontal disease, diabetes, problems of hematological origin, dental trauma injuries, para-functional habits, the reason for extraction or the buccal cortical bone integrity.<sup>5, 6, 7, 8, 9</sup>

In order to slow down the process of natural bone resorption after extraction, the term: "alveolar bone crest preservation" appeared, according to **Sciar, 2004**, to represent "all surgical techniques that aim to preserve the maximum volume and architecture of hard and soft tissues in the extraction site, in order to optimize the aesthetics and function of the future implant-supported restoration". **Weng et al., 2011**, reported that when the ridge preservation is not performed, we may face a smaller amount of healthy tissue present, inadequate aesthetics in the region and also a need for bone grafting, 10 times higher for a subsequent rehabilitation when the ridge is not preserved previously.<sup>10,11</sup>

The immediate installation of implants after extractions, when indicated, associating the use of biomaterials, has been presented as an excellent alternative for preservation of alveolar ridge dimensions and maintenance of underlying soft tissues, in view of its predictability, reduction in the number of necessary surgical interventions, decrease in morbidity by the patient and also the treatment time.<sup>12, 13, 14</sup>

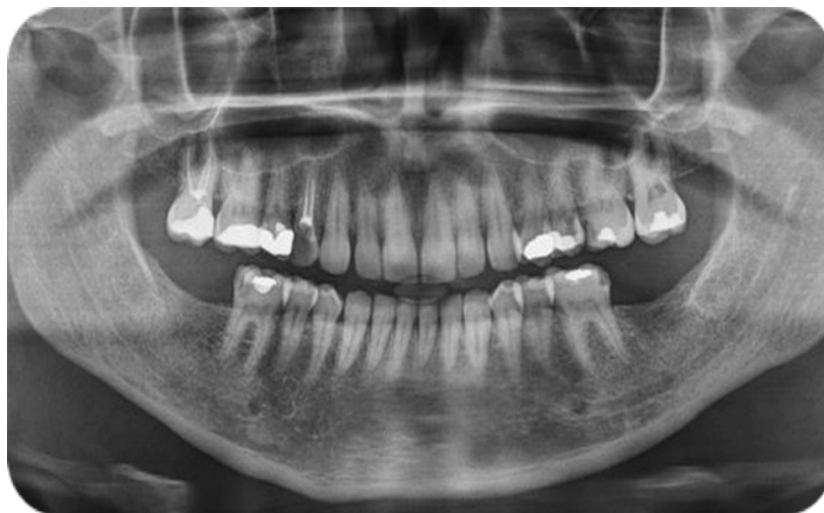The combination of biomaterials for bone grafting, being covered by absorbable or non-absorbable membranes, such as dense polytetrafluoroethylene membrane (d-PTFE), can be used as a technique of great efficiency and predictability in cases of alveolar preservation when associated or not to the immediate implant. Also according to **Dayube and co-workers in 2017**, besides working as an option for the technique of guided bone regeneration (GBR), the combination of d-PTFE membrane with bone grafting would provide a high regeneration of soft tissues after extraction.<sup>1, 15</sup>

The collagen resorbable membranes or non-absorbable expanded polytetrafluoroethylene (e-PTFE), although they have great results and proven effectiveness, cannot be used being exposed to the oral environment, this feature is of great relevance in cases where would be performed Guided Bone Regeneration (GBR) with dental extractions for example, because a large defect represented by the alveolus or extensive volumetric change makes limited availability of mucous tissue to cover them.<sup>16</sup>

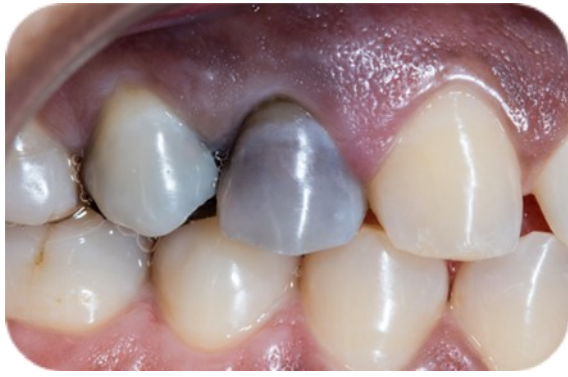The possibility of being exposed to the oral environment without the need for mucous tissue coverage is one of the great advantages of d-PTFE, since dense membranes have a very small and insufficient porosity for bacteria penetration.<sup>17, 18</sup>

## Case Report

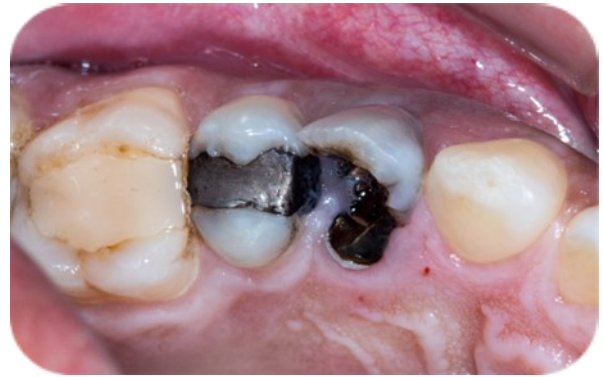Patient MAM, 41 years old, female, presents impairment of dental element 14. Complementary examinations were requested and no changes were observed.



**Figure 1:** Panorâmica X-ray

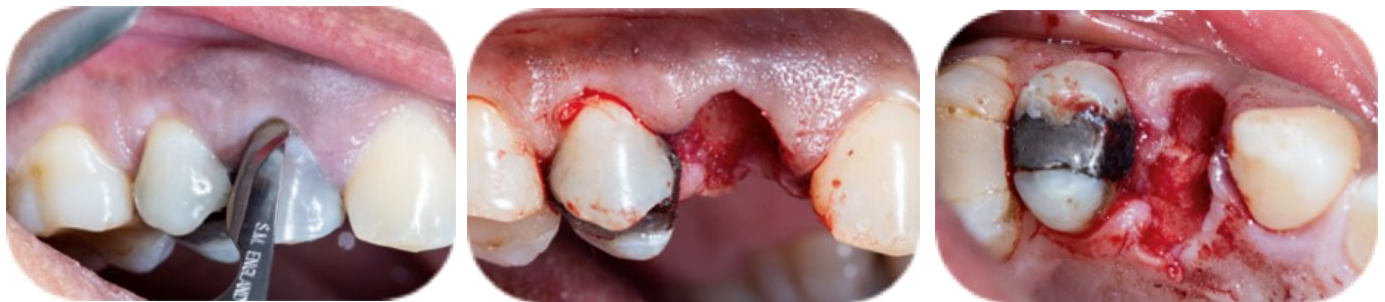

**Figure 2:** Initial Clinical Aspect (Vestibular View)



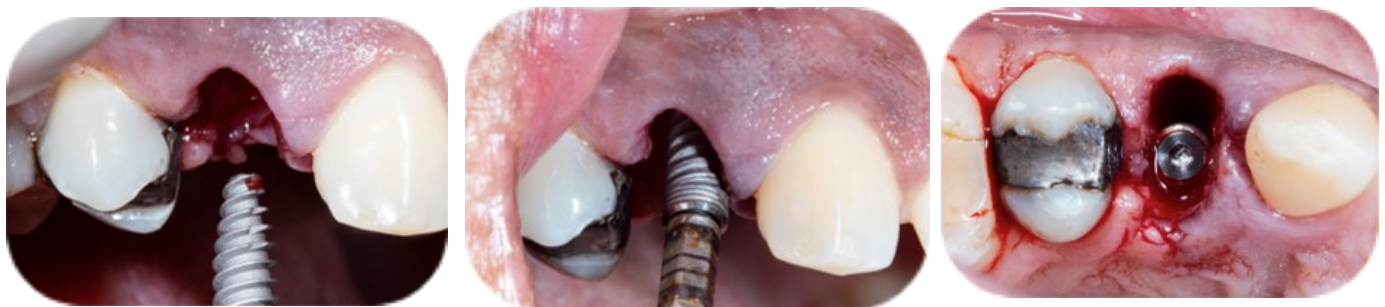**Figure 3:** Initial Clinical Aspect (Occlusal View)

During the exam and clinical analysis, there was indication for removal of tooth 14, where was offer the removal of the dental element (**Figure 4**) and immediate implantation, followed by reconstruction of the alveolus ridge with xenograft associated with particulated autologous graft (**Figure 9**).

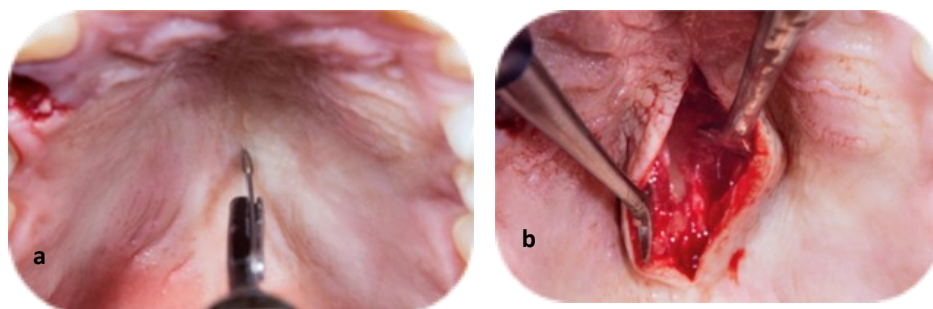


**Figure 4:** Atraumatic extraction process: (a) Intra sulcular incision; (b) Vestibular View After Atraumatic Extraction; (c) Occlusal View After Atraumatic Extraction

As planned, it was performed after extraction, immediate installation of titanium dental implant (Titanium Fix, Taubaté, SP - Brazil), Black Fix Profile line 13mm X 3.5mm (**Figure 5**), followed by placement of bone graft of heterogeneous origin (Lumina Porous Granulation Large - Criteria Biomaterials, São Carlos, SP - Brazil) associated with autologous graft removed (**Figure 6**) from the palate with trephine collector cutter (**Figure 7**) (Bullet Collector - Criteria Biomaterials, São Carlos, SP - Brazil), non-cross-linked bovine type 1 and 3 bonding membrane (**Figure 8**) (Criteria Biomaterials, São Carlos, SP - Brazil) in association with polyethylene fluoride barrier - PTFE (Lumina PTFE - Criteria Biomaterials, São Carlos, SP - Brazil)



**Figure 5:** , Immediate Installation of Titanium Dental Implant



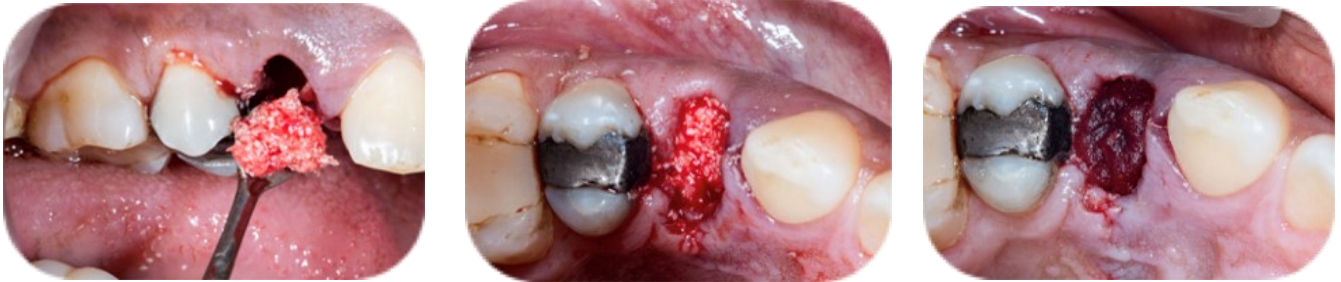**Figure 6:**Autologous Graft Removal (a) palatal incision; (b) palatal aperture



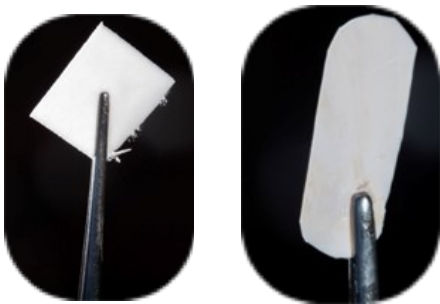**Figure 7:** Trephine Collector (Bullet Collector) Cutter



**Figure 8:** heterogeneous graft associated with autologous graft

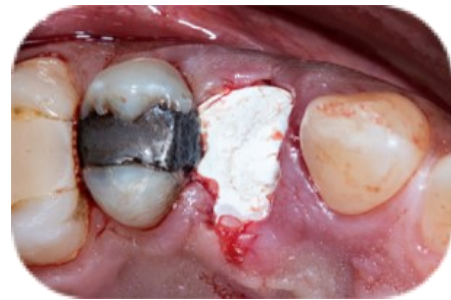

**Figure 9:** Alveolar Reconstruction: (a) Graft Placement; (b) positioned graft (Occlusal View); (c) Positioned Bonding Membrane

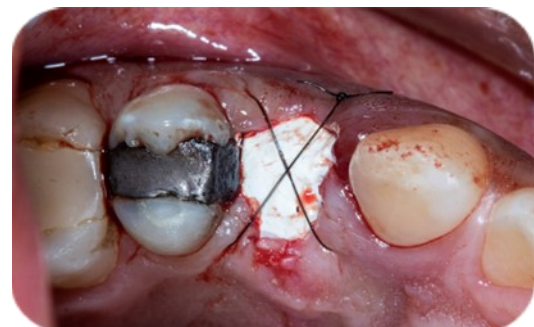
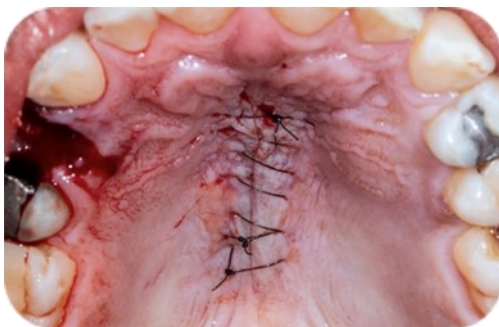
**Figure 10:** Non-Cross-Linked Bovine Type Bonding Fluoride

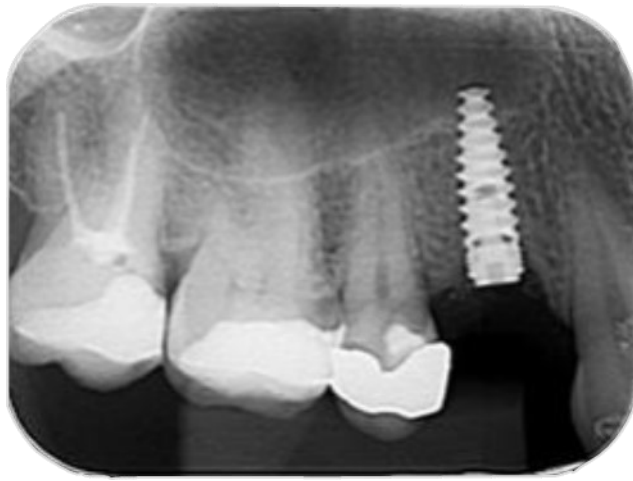
Membrane and Polyethylene Fluoride Barrier (PTFE)



**Figure 11:** Positioned Polyethene Barrier – PTFE (Occlusal view)



**Figure 12:** Sutures; (a) Palatal Simple Continuous Stitch Suture, (b) suture in point x to fix Polyethylene Fluoride Barrier



**Figure 13:** Radiograph aspect after 180 days postoperative

The patient was prescribed 2g of amoxicillin preoperatively, together with 4mg of dexamethasone, both 1 hour before the surgical procedure, as a preoperative prophylactic element.

Was proceeded extra-oral antiseptis with 2% clorhexidine and performed an infiltrative anesthetic technique with articaine anesthetic salt (dilution of 1:100.000). There was no need to open flaps, followed by tooth extraction using straight Seldin lifts, periosteal elevator and finally forceps (Quinelato - Rio Claro, SP - Brazil). After the removal of the root, curettage to remove any fragmentary residue, as well as stimulating bleeding of the alveolar process. The drilling of the alveolus was performed, with an initial 2.0 spear cutter, followed by a 2.0 mm thick helical cutter, and finally a 2.5 mm helical cutter, all using a 20:1 hand-piece at 1200 RPM and constant irrigation. A 2.8 mm thick conical cortical cutter in counterclockwise rotation at 50RPM, was used as directed by the implant manufacturer, to densify the alveolar bone. The implant was placed at the level of the alveolar ridge with a rotation of no more than 35 RPM and a torque of 40N.cm. Then, performed the filling of the alveolar space between the buccal wall and the implant with xenograft in association with autologous chips, removed from the palate (**Figure 6**), both being moistened by serum extracted from the supernatant of the platelet-rich fibrin membranes (**Figure 8**), processed prior to surgery through processing by venipuncture, using centrifugation protocol in a centrifuge (Biancolab - São Paulo, SP - Brazil), using the protocol in the following parameters: 2700RPM and 12 minutes, generating G-force around 400G, and type 1 and 3 bovine collagen membrane (**Figure 10**), with closure using PTFE barrier(**Figure 11**). Suturing was performed using 5-0 micro-nylon suture (Microsuture, São Paulo, SP - Brazil) in an X technique in the alveolus and continuous in the palate (**Figure 12**).

The PTFE barrier was removed at 28 days, and good postoperative clinical aspect was observed, showing tissue formation under the barrier, without infection signs, showing possible advantage in the application of the technique regarding the structural and volumetric maintenance of the tissues adjacent to the implant. Rx control was made after 180 days (**Figure 13**) and the patient was referred to prosthetic restoration.

## Discussion

Immediate rehabilitation is defined as the placement of an implant in the alveolus after extraction of the tooth and, according to *Lang et al., 2012*, the survival rate of immediate implantation is 97.3% to 99%. In contrast, more traditional guidelines emphasizes the need for complete bone healing of the alveolar system prior to implant installation in the tooth extraction site. This process, however, would usually require several months and without the use of an appropriate biomaterial, there would be the natural process of bone remodeling, loss of bone crest, as well as loss of support for the mucous tissue, which would interfere in a direct way in the future implant-supported restoration and in the white and pink aesthetics of the region as previously mentioned.<sup>8, 19, 20, 21</sup>

The application of xenograft in fresh extraction site promote the alveolar volume preservation and necessary amount of bone surrounding implant, but only with osseointegration property. Associating the xenograft with autogenous bone chips, in the authors point of view, could potentialize the bone formation boosting the graft with osseointegration property. The use of serum extracted from the supernatant of the platelet-rich fibrin membranes brings to the graft growth factors and serve as a agglutinating, facilitating the manipulation of the xenograft/autograft mix to the site of GBR. According to current studies, it is accepted that techniques of bone regeneration and guided tissue regeneration, can be used with success when utilizing both non-resorbable and absorbable membranes.<sup>1, 4, 15, 22, 23</sup>

Absorbable collagen membranes are traditionally used in guided bone regeneration protocols due to their hemostatic and chemotactic characteristics and high cellular adhesiveness; however, when exposed to the oral environment they present rapid resorption, which could lead to impairment of GBR.

The non-absorbable membranes of high-density polytetrafluorethylene (d-PTFE), present some advantages when used in the GBR, as they do not require primary closure, are generally easy to remove, without the need of additional surgical interventions and have an excellent marginal sealing against bacteria in the grafting area, besides being able to be exposed to the oral environment; However, a limitation of the d-PTFE is that the membrane presents low tissue adhesiveness when compared to the collagen membrane and when used individually, which can also sequentially compromise the GBR. <sup>24, 25, 26</sup>

In light of the benefits and limitations of both membranes, in **2015, Al-Hezaimi and colleagues** conducted an experiment in which both membranes (collagen and d-PTFE) were used simultaneously and through histological analyses could conclude that this association, as a double layer, would promote greater bone formation and graft stabilization at the defect site when compared to using them individually. This suggests that the d-PTFE membrane provides a reasonably bacteria-free environment for the underlying collagen membrane to facilitate its chemotactic and cell-adhesive properties. In a study by **Yun et al. (2011)**, through observation using scanning electron microscopy, the results observed was that a double layer of the membrane (d-PTFE placed on top of collagen membrane) is an effective way to maintain alveolar bone crest around immediate implants. <sup>26, 27, 28</sup>

Following the results of studies and research on the subject of alveolar bone preservation through the use of two different membranes, it was performed in this case report the technique of immediate implant installation after extraction associated with the use of double layer combined with biomaterials. Several studies have used similar techniques regarding the use of absorbable or non-absorbable membranes, associated to biomaterials for bone maintenance or augmentation of the region. In their results, as in the present case, this association promoted adequate healing, maintenance of the alveolar ridge volume, good maintenance of the bone crests and consequently the preservation of the papilla and keratinized tissue, and low risk of infection, since the dense membranes have a very small and insufficient porosity for bacteria penetration. The results found in the literature corroborate with those found in this case report, which would justify its use when considering post-extraction alveolar preservation. <sup>14, 26, 27, 28, 29, 30</sup>

## Conclusion

There can be suggest through this case report that when the double layer membrane technique is applied after tooth extraction, there is the preservation of the alveolar bone crest and maintenance of bone volume, important factors for good peri-implant health and greater survival of the immediate implant. It was also observed that this bone preservation obtained through the technique is of paramount importance for the support of the mucous tissue and maintenance of the papillae, enabling good aesthetic and functional results for the patient. Further studies on this technique are necessary to improve our understanding of the results obtained.

## Conflict of Interest

The authors declare no conflict of interest.

## References

1. Elson Tadeu Fernandes de Oliveira, R. H. B. de F. I. P. de M. (2018). Alveolar preservation in aesthetic area in a trauma victim: a case report. ARCHIVES OF HEALTH INVESTIGATION, 7. Recuperado de
2. Ashman A. Ridge preservation: the future practice of dentistry. Dental economics - oral hygiene. 1995 Ago; 85(8):80-3.
3. Barteo BK. Extraction site reconstruction for alveolar ridge preservation. Part 1: rationale and materials selection. Journal of Oral Implantology. 2001 Ago; 27(4):187-93.
4. Araujo MG, Lindhe J. Dimensional ridge alterations following tooth extraction. An experimental study in the dog. Journal of Clinical Periodontology. 2005 Feb; 32(2):212-8.
5. Araújo, M. G. et al. Ridge alterations following grafting of fresh extraction sockets in man: A randomized clinical trial. Clinical Oral Implants Research. 2015, v. 26, n. 4, p. 407-412.
6. Schropp L, Wenzel A, Kostopoulos L, Karring T. Bone healing and soft tissue contour changes following single-tooth extraction: a clinical and radiographic 12-month prospective study. Int J Periodontics Restorative Dent 2003; 23: 313-323.
7. Araujo MG, Silva CO, Misawa M, Sukekava F. Alveolar socket healing: what can we learn? Periodontol 2000 2015; 68: 122-134.
8. Misawa M, Lindhe J, Araujo MG. The alveolar process following single-tooth extraction: a study of maxillary incisor and premolar sites in man. Clin Oral Implants Res 2016; 27: 884-889.
9. Chappuis, V.; Araujo M.; Buser, D. Clinical relevance of dimensional bone and soft tissue alterations post-extraction in esthetic sites. Periodontology 2000, 2017, v.73, p. 73-83.

10. MacBeth, N. et al. Hard and soft tissue change following alveolar ridge preservation: a systematic review, *Clinical Oral Implants Research*, 2016, 28(8), pp. 982-1004.
11. Sclar AG. Strategies for management of single-tooth extraction sites in aesthetic implant therapy. *J Oral Maxillofac Surg*. 2004;62(9 suppl 2):90-105.
12. Weng D, Stock V, Schliephake H. Are socket and ridge preservation techniques at the day of tooth extraction efficient in maintaining the tissues of the alveolar ridge? Vol. 4. 2011. 59 p.
13. Shanaman RH. The use of guided tissue regeneration to facilitate ideal prosthetic placement of implants. *Int J Periodontics Restorative Dent* 1992;12(4): 256-65.
14. Richart D, Slater JJ, Meijer HJ, Vissink A, Raghoobar GM. Maxillary sinus lift with solely autogenous bone compared to a combination of autogenous bone and growth factors or (solely) bone substitutes. A systematic review. *Int J Oral Maxillofac Surg* 2012; 41(2):160-7.
15. Al-Sabbagh M, Kutkut A. Immediate implant placement: surgical techniques for prevention and management of complications. *Dent Clin North Am* 2015; 59(1):73-95.
16. Ulisses Ribeiro Campos Dayube , Thayane Silveira Mata Furtado, Diego Philipe Siqueira De Paula, Bruno Freitas Mello, João Paulo Abreu De Bortoli, Jamil Awad Shibli. Preservação do rebordo alveolar com perda óssea vestibular associada a biomaterial e membrana ptfе densa intencionalmente exposta ao meio bucal. *Terapia Aplicada. Caderno científico. INPerio* 2017;2(3):433-40.
17. Jung RE, Fenner N, HammerleCH, Zitzmann NU. Long-term outcome of implants placed with guided bone regeneration (GBR.I using resorbable and non-resorbable membranes after 12-14 years. *Clin Oral Implants Res* 2013;24(10.1:1065-73.
18. Krauser JT High-density PTFE membranes: uses with root-form implants. *Dent Implantol Update* 1996,7(9):65-9.
19. Barboza EP, Stutz B, Ferreira VF, Carvalho W. Guided bone regeneration using nonexpanded 17. polytetrafluorethylene membranes in preparation for dental implant placements-a report of 420 cases. *Implant Dent* 2010;19(1 j:2-7.
20. Lang NP, Pun L, Lau KY, et al. A systematic review on survival and success rates of implants placed immediately into fresh extraction sockets after at least 1 year. *Clin Oral Implants Res* 2012;23(Suppl 5):39-66.
21. Adell R, Lekholm U, Rockler B, et al. A 15-year study of osseointegrated implants in the treatment of the edentulous jaw. *Int J Oral Surg* 1981;10(6):387-416.
22. Albrektsson T, Zarb G, Worthington P, et al. The long-term efficacy of currently used dental implants: a review and proposed criteria of success. *Int J Oral Maxillofac Implants* 1986;1(1):11-25.
23. Anwandter A; Bohmann S; Nally M; Castro A B; Quirynen M; Pinto N. Dimensional changes of the post extraction alveolar ridge, preserved with Leukocyte- and Platelet Rich Fibrin: A clinical pilot study. *J Dent*. 2016 Sep;52:23-9.
24. Calvo-Guirado JL, Boquete-Castro A, Negri B, et al. Crestal bone reactions to immediate implants placed at different levels in relation to crestal bone. A pilot study in Foxhound dogs. *Clin Oral Implants Res* 2014;25(3):344-51.
25. Mardas N, D' Aiuto F, Mezzomo L, Arzoumanidi M, Donos N. Radiographic alveolar alterações ósseas após a preservação da crista com dois biomateriais diferentes. *Clin Oral Implants Res*. 2011; 22:416-423.
26. Vignoletti F, Matesanz P, Rodrigo D, Figuero E, Martin C, Sanz M. Protocolos cirúrgicos para preservação da crista após a extração do dente. Uma revisão sistemática. *Clin Oral Implants Res*. 2012; 23(suppl 5):22-38.
27. Yun JH, Jun CM, Oh NS. Secondary closure of an extraction socket using the double-membrane guided bone regeneration technique with immediate implant placement. *J Periodontol Implant Sci*. 2011;41:253-258.
28. Khalid Al-Hezaimi , Giovanna Iezzi,; Ivan Rudek,; Abdullah Al-Daafas, ; Khalid Al-Hamdan; Abdulaziz Al-Rasheed,; Fawad Javed,; Adriano Piattelli,; Hom-Lay Wang. Histomorphometric Analysis of Bone Regeneration Using a Dual Layer of Membranes (dPTFE Placed Over Collagen) in Fresh Extraction Sites: A Canine Model. *J Oral Implantol*. 2015, 41 (2): 188-195.
29. Ronda M, Rebaudi A, Torelli L, Stacchi C. Expanded vs. dense polytetrafluoroethylene membranes in vertical ridge augmentation around dental implants: a prospective randomized controlled clinical trial. *Clin Oral Implants Res* 2014;25(7):859-66
30. Ferreira VF, Stutz B, Barboza EP. Maintenance of the alveolar ridge using intentionally exposed d-PTFE membranes - 100 case reports / Alveolar ridge maintenance using intentionally exposed d-PTFE membranes - A report of one hundred cases . *ImplantNews* 2010;7(2):175-8.

**Citation:** Bezerra GM, Freitas BS, Ferreira LA, Martins SCR, Mariano JR and Sousa LLL. "Immediate Implant Placement and Double Layer Socket Preservation Associated with Mix of Xenograft and Particulate Autogenous Bone Graft: A Case Report". SVOA Dentistry 2:4 (2021) Pages 131-138.

**Copyright:** © 2021 All rights reserved by Leandro Lécio de Lima Sousa et al. This is an open access article distributed under the Creative Commons Attribution License, which permits unrestricted use, distribution, and reproduction in any medium, provided the original work is properly cited.