

# Verrucous Carcinoma in the Upper Alveolar Ridge: Case Report with 18-years Follow-up

Fábio Mendes Sipan Dias Pinto<sup>1</sup>, Daniel Nuciattelli Pinto de Mello<sup>2</sup>, Estevam Rubens Utumi<sup>4</sup>, José Eduardo Bacci<sup>4</sup> and Irineu Gregnanin Pedron<sup>5\*</sup>

<sup>1</sup>Undergraduate Student, Universidade Brasil, São Paulo, Brazil.

<sup>2</sup>DDS, Birmingham, UK.

<sup>3</sup>Preceptor and Oral and Maxillofacial Surgeon, Hospital Municipal Dr. Arthur Ribeiro de Saboya, São Paulo, Brazil.

<sup>4</sup>Professor, Department of Periodontology, Stomatology and Oral Pathology, Universidade Brasil, Universidade Cruzeiro do Sul and FAOA, São Paulo, Brazil.

<sup>5</sup>Professor, Department of Periodontology, Implantology, Stomatology and Therapeutics, Universidade Brasil, São Paulo, Brazil.

**\*Corresponding Author:** Irineu Gregnanin Pedron, Professor, Department of Periodontology, Implantology, Stomatology, Integrated Clinic and Therapeutics, School of Dentistry, Universidade Brasil, São Paulo, Brazil, Tel: +55-11 2944-4067

**Received:** September 07, 2021 **Published:** September 20, 2021

## Abstract:

The verrucous carcinoma is a low-grade malignant neoplasia, superficially invasive, with a low rate of metastasis. It is frequently associated with tobacco. This neoplasia with a low rate of infiltration must be treated and followed up. The dentist plays a role in early diagnosis of oral cancer and in post-treatment rehabilitation. Upon having the tumor diagnosed, the patient must be sent to an oncologist. The purpose of this article was to report a case in which the tumor was removed during biopsy. Once a malignant neoplasia was diagnosed, the patient was scheduled in Head and Neck Surgery Service.

**Keywords:** verrucous carcinoma; mouth neoplasms; gingiva; oral diseases; gingival diseases; early diagnosis.

## Introduction

Verrucous carcinoma is considered a low-grade pathological variant of the squamous cell carcinoma<sup>1-10</sup>. However, some authors have proposed the possibility of the verrucous carcinoma being a less aggressive form than the first one and could be re-classified as a papillary squamous cell carcinoma, a 'hybrid form' of the verrucous carcinoma<sup>4,8</sup>. However, in 2005, Khan et al.<sup>12</sup> presented a case of papillary squamous cell carcinoma in gingiva, discussing about the differentiation of this lesion and verrucous carcinoma, both distinct forms of squamous cell carcinoma.

Historically, Friedell and Rosenthal, in 1941 reported 8 cases of squamous cell carcinoma in the oral mucous, 4 of them showing papilliform or verrucous clinical aspects. However, the first description of verrucous carcinoma in the oral cavity was performed by Ackerman, in 1948<sup>1,5</sup>. This carcinoma is relatively infrequent, varying from 1 to 20% of all oral carcinomas in the US<sup>1,6,7,11</sup>, while reaching 40% in the Southeast Asian countries<sup>1,2,8,10</sup>. It can affect the skin, nasal cavity, larynx, esophagus, anal-rectal region, penis, vagina, soles of feet, ear canal and bladder<sup>1,5,7,8,11</sup>.

Clinically it presents a papilliform exophytic growth, generically related to tobacco and derived forms. Since it is a superficially-invasive carcinoma with low potential of metastasis, a surgical treatment is usually recommended<sup>1,2,4,11</sup>. The early diagnosis and intervention influence survival, quality of life and the patient's prognosis. Generally, the survival rate (5 years) is around 49% to 66%<sup>7</sup>. The purpose of this article is to report a case of a verrucous carcinoma in a former smoker and former drinker patient, looking at particular details and treatment of the lesion, as well clinical follow-up of the patient.

## Case Report

African-descendent patient of the male gender, 67-years-old, former hard smoker and former hard drinker, showed up at the private clinic complaining of a lesion in his mouth.

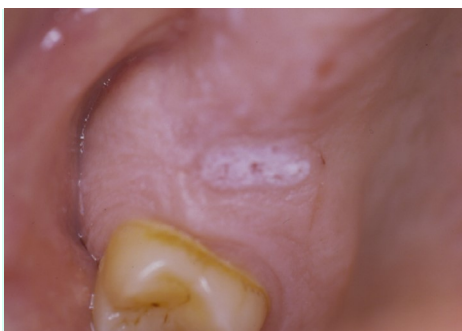Clinically, the lesion was oval shape, whitened, asymptomatic, with a size of 10 mm at the greatest diameter and presented a papilliform exophytic aspect. The patient had noticed the lesion two months before, coinciding with a burn by hot food that did not heal. The lesion was located in the upper edentulous alveolar ridge, corresponding to the region of the first molar tooth (Figure 1). There was no radiographic sign of bone involvement (Figure 2). Other white lesions were noticed on retromolar region and right tubers (Figures 3 and 4, respectively), with no continuity or association with the main lesion.

Regarding the systemic condition, the patient reported hypertension controlled with medicine anti-hypertensive and diuretic (nifedipine 30 mg and chlortalidone 25 mg, respectively, daily).

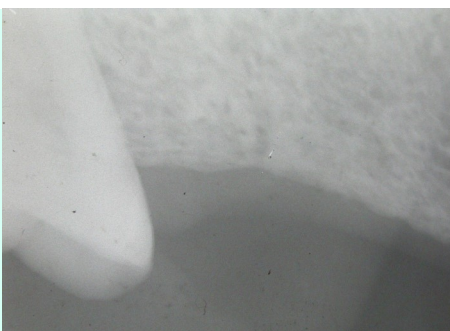
With a presumptive diagnosis of papilloma, an excisional biopsy was performed on the lesion. The histological features showed a fragment of mucosa covered by hyperkeratinized stratified pavementous epithelium, displaying hyperplasia, acanthosis and projections to the underlying lamina propria. Focal areas of polarity inversion of the basal layer cells were observed. The clefts formed among the projections were filled by keratin tampon. The lamina propria was made up of a dense connective tissue, which presented a mononuclear inflammatory infiltrate (Figure 5). The histopathological diagnosis was verrucous carcinoma.

There was repair in the operated region with no intercurrent. In the other whitened regions, other three incisional biopsies were performed. Two of those were in the right retromolar space region, at distinct surgical times, and another in the gingiva of right tuber region. The histopathological diagnoses were hyperkeratosis and acanthosis.

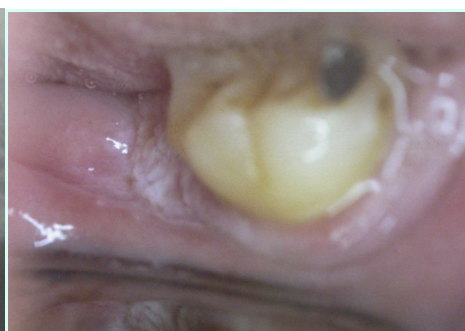The patient was sent to the Head and Neck Surgical Service of the Medical College Hospital of University of São Paulo. Another biopsy was performed in the right retromolar space mucosa, which histopathological diagnosis was also hyperkeratosis. The patient has been followed-up semi-annually for the last 18 years and has shown no evidence of lesion recurrence (Figure 6).



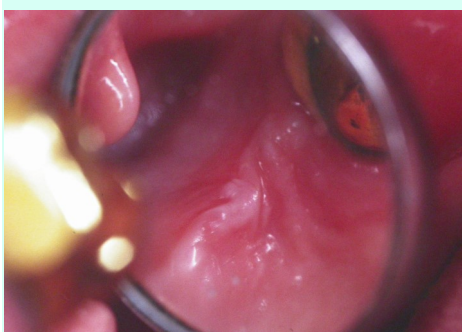
**Figure 1:** Gingival verrucous carcinoma in edentulous upper alveolar ridge.



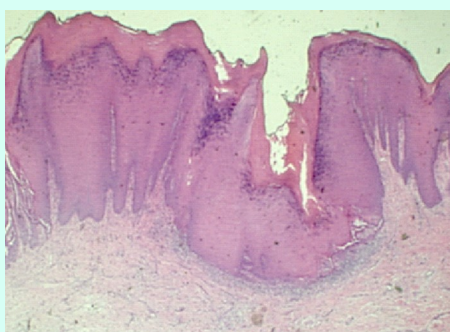
**Figure 2:** Periapical radiograph with no alterations in bone tissue.



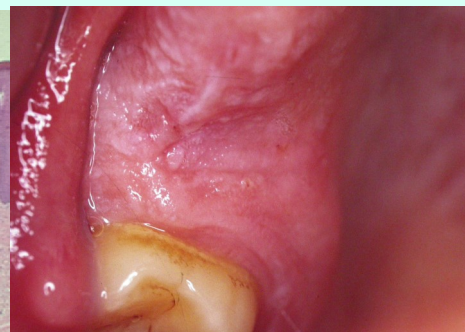**Figure 3:** White lesion on retromolar region.



**Figure 4:** White lesion on right tuber.



**Figure 5:** Histological features of the verrucous carcinoma (Hematoxylin-Eosin stain; magnification: 25 X).



**Figure 6:** Clinical evaluation of 18-years follow-up, presenting no recurrence of the lesion.

## Discussion

Clinically, the verrucous carcinoma presents as an exophytic growth; papilliform; irregular, with folds and wrinkles characterizing deep ridges (evaginations and invaginations); normally non-ulcerous; with slow growth; low metastatic potential. It can be covered by a leukoplasic membrane, with a rocky aspect and peduncled<sup>2,5,7,11,13</sup>. The verrucous carcinoma can become destructive, growing in size and invading or infiltrating adjacent or underlying tissues such as skin, cartilage, and bone<sup>4,5,8,11,12</sup>. It presents a trend of being multilocular<sup>5</sup>. The regional lymph nodes can become sensitive and ingurgitated, frequently simulating tumoral metastasis, although they are inflammatory alterations<sup>8,9,11</sup>. When the tumor reaches great dimensions pain and trismus are common, but bleeding is rare<sup>5</sup>.

Histologically it is characterized by hyperplasic lesion with hyperorthokeratosis and/or parakeratosis in the epithelium with a verrucous or papilliform surface, creating ridges. The acanthosis is a frequent characteristic and there is epithelial rapid growth projecting in the direction of the connective tissue, in the shape of test tubes. These histopathological findings were observed in our report. The basal membrane remains intact with the preservation of stratification and small evidence of invasion of the connective tissue by individual tumor cells. Mitosis, pleomorphism and hyperchromatism were infrequent. A remnant of epithelial vacuolated cells infected by papilloma virus can be identified. Dense infiltration and chronic inflammatory cells on the adjacent connective tissue were observed<sup>1,2,5,8,11-14</sup>. Clusters of squamous cell carcinomas are not rare and the histopathological exam must be done regularly.

The oral mucous, gingiva and alveolar ridge were the most affected oral sites<sup>1,2,4-6,11</sup>. Male is more affected than female, at a ratio of 4.29 to 1<sup>1,4,5,11</sup>. The present report confirms this prevalence. There is a higher prevalence of the 5<sup>th</sup> decade of life<sup>1,3-5,9,11</sup>, the incidence was 15% among Caucasian, 10% among Hispanics, 5% among African descendants, and 10% among young people, related especially to the use of tobacco<sup>7</sup>.

Smoking and tobacco use in all these forms (chewing tobacco, dip) were considered the main factor in the etiology of the verrucous carcinoma<sup>1-5,7,8,11</sup>. In this report, smoking, as well drinking, could be considered the main factor in the pathogenesis of the lesion. Previous study reported the higher incidence of verrucous carcinoma among smoking patients<sup>7</sup>. However, other co-carcinogenic factors can be also involved, as immunosuppression, HSV-1 (herpes simplex type 1), HPV (human papillomavirus)<sup>2,6-8,11,12</sup>, chew "betel nuts"<sup>4,8,11</sup> or eucaliptus leaf, association between drinking, smoking and precarious oral hygiene<sup>1,3-5,8</sup>.

Koch et al.<sup>8</sup> showed some theories about still uncertain pathogenesis of the verrucous carcinoma. The high incidence of abnormalities in the mucous membrane adjacent to the verrucous carcinoma and the rapid growth of verrucous lesions suggest that this kind of lesion can be a precursor or a pre-cancerous stage of a malignant tumor (leukoplakia or verrucous hyperplasia and lichen planus)<sup>4,8,10,11,14</sup>. Clinical and histopathological features of the carcinomas affecting the upper digestive tract (verrucous), genitalia (acuminated condilomas) and skin of the extremities (cuniculatum carcinoma) suggests the possibility of similar etiology. Carrozo et al.<sup>6</sup> reported a case of verrucous carcinoma associated with lichen planus, which could have to be the precursor of the first one, since it presents a pre-malignant potential and can transform itself directly into carcinoma or alter the susceptibility of the oral mucosa to the carcinogens, irritants or viruses. They suggested the possible role of chlorhexidine and local corticosteroid in the malignant evolution of the lichen planus, although there was no consistent evidence of this in the literature<sup>6</sup>.

The differential diagnosis of verrucous carcinoma is difficult. Sometimes, multiple biopsies are necessary to conclude the diagnosis. Generally, there are, lesions such as squamous cell carcinoma, leukoplakia (with or without epithelial dysplasia), leukoplakia and verrucous hyperkeratosis, moderate dysplasia, hyperkeratosis, chronic candidosis and lichen planus associated with verrucous carcinoma, making difficult to have a clinical diagnosis<sup>1,4-6,8,10-12</sup>. It is important to emphasize that the biopsies done in other regions were motivated by clinical aspects of the differential diagnosis (hyperkeratosis and acanthosis).

The treatment decision should be based on clinical, biological and pathological course of the lesion. Usually, surgical treatment, through excision of the lesion is the chosen method<sup>1-5,7,8,10,11</sup>. It should be done with a margin of safety, since it can affect adjacent tissues. It presents a favorable prognosis, as long as it is done with follow-up. Surgical block dissection is unnecessary<sup>4</sup> and the need for surgical dissection of the lymph nodes is rare<sup>11</sup>. Radiotherapy was reported by some authors, and it is well advised in extensive cases, in which surgery could be mutilating, or as a control for neoplasia, since there is a relative high recurrence in these cases, reaching 69.23% (from 10 to 30 months)<sup>1,2,4,5,7,11</sup>. Differentiation or anaplastic transformation (to carcinoma from squamous cells) after radiotherapy were mentioned, varying from 0 to 30% (in 6 months)<sup>3,5,9,11</sup>. Medina et al.<sup>3</sup> advocated that the results obtained from radiotherapy were similar to those obtained from surgery, and that they did not obtain anaplastic transformation in these cases. However, other studies showed that the association between radiotherapy and the surgical treatment did not satisfactory results, and that initial radiotherapy resulted in a noteworthy worsening when compared to surgery<sup>5,8</sup>.

Chemotherapy was suggested by some authors<sup>9-11</sup>, although according to Jordan<sup>11</sup>, it did not represent a significant role in the treatment of verrucous carcinoma. Several cytotoxic drugs such as bleomycin, UFT (uracil + 1-(2tetrahydrofuryl)-5fluorouracil), cisplatin and the metotrexate, alfa-interferon, or even the combination of these showed good results in the reduction of tumor size, but failed in complete remission. The treatment of oral verrucous carcinoma with bleomycin was suggested previously and showed good results<sup>10</sup>. Immunotherapy with the OK-432 (modifier of biological response) was not effective<sup>9</sup>. Yeh<sup>10</sup> commended the surgery followed by cryosurgery in lesions that are wide and irregular, presenting several advantages of their use, as reduction of bleeding and infection, pain and post-op scarring. Laser excision (ablation) and photodynamic therapy were also suggested<sup>8-10</sup>, specially in cases of recurrence<sup>10</sup>.

The recurrence rate was from 0 to 18% (from 6 to 30 months), and can be related to the multicentric nature of the lesion or the method of treatment used, such as isolated surgery or radiotherapy<sup>1,4,10,11</sup>. When there is recurrence, the treatment normally used is surgical<sup>8,11</sup>.

The early diagnosis, elucidated by biopsy, and the rapid use of adequate treatments favor the prognosis of verrucous carcinoma. Additionally, it is observed the reduction of anxiety of the oncological patient facing the diagnosis, treatments, survival and quality of life<sup>2,13</sup>.

## Conclusion

Verrucous carcinoma is a malignant neoplasm that is not very invasive and has a low malignancy grade. It presents clinically as papilliform or verrucous exophytic growth. Faced with the amplitude of lesions that present themselves with verrucous or papillary characteristics, the biopsy plays a fundamental role in elucidating the diagnosis, determining the treatment plan, and above all, reducing patient anxiety.

## References

- Rodrigues-Fernandes CI, Arboleda LPA, Vargas PA, Lopes MA, Santos-Silva AR. Oral verrucous carcinoma manifesting as proliferative verrucous leukoplakia. *Oral Oncol* 2021;116:105144.
- Narayan VK. Verrucous carcinoma of buccal mucosa in female: a rare case report of traumatic tooth origin. *Case Rep Dent* 2021;2021:6673038.
- Medina JE, Dichtel W, Luna MA. Verrucous-squamous carcinomas of the oral cavity. *Arch Otolaryngol* 1984;110(7):437-440.
- Rajendran R, Varghese I, Sugathan CK, Vijayakumar T. Ackerman's tumour (verrucous carcinoma) of the oral cavity: a clinico-epidemiologic study of 426 cases. *Aust Dent J* 1988;33(4):295-298.
- Kamath VV, Varma RR, Gadewar DR, Muralidhar M. Oral verrucous carcinoma. An analysis of 37 cases. *J Cranio-maxillofac Surg* 1989;17(7):309-314.
- Carrozzo M, Carbone M, Gandolfo S, Valente G, Colombatto P, Ghisetti V. An atypical verrucous carcinoma of the tongue arising in a patient with oral lichen planus associated with hepatitis C virus infection. *Oral Oncol* 1997;33(3):220-225.
- Bouquot JE. Oral verrucous carcinoma. Incidence in two US populations. *Oral Surg Oral Med Oral Pathol Oral Radiol Endod* 1998;86(3):318-324.
- Koch BB, Trask DK, Hoffman HT, Karnell LH, Robinson RA, Zhen W, Menck HR, Commission on Cancer, American College of Surgeons, American Cancer Society. National survey of head and neck verrucous carcinoma. *Cancer* 2001;92(1):110-120.
- Yoshimura Y, Mishima K, Obara S, Nariai Y, Yoshimura H, Mikami T. Treatment modalities for oral verrucous carcinomas and their outcomes: contribution of radiotherapy and chemotherapy. *Int J Clin Oncol* 2001;6(4):192-200.
- Yeh CJ. Treatment of verrucous hyperplasia and verrucous carcinoma by shave excision and simple cryosurgery. *Int J Oral Maxillofac Surg* 2003;32(3):280-283.
- Jordan RC. Verrucous carcinoma of the mouth. *J Can Dent Assoc* 1995;61(9):797-801.
- Khan SM, Gossweiler MK, Zunt SL, Edwards MD, Blanchard SB. Papillary squamous cell carcinoma presenting on the gingiva. *J Periodontol* 2005;76(12):2316-2321.
- Whitefield S, Raiser V, Shuster A, Kleinman S, Shlomi B, Kaplan I. The spectrum of oral lesions presenting clinically with papillary-verrucous features. *J Oral Maxillofac Surg* 2018;76(3):545-552.

14. Davidova LA, Fitzpatrick SG, Bhattacharyya I, Cohen DM, Islam MN. Lichenoid characteristics in premalignant verrucous lesions and verrucous carcinoma of the oral cavity. *Head Neck Pathol* 2019;13(4):573-579.

**Citation:** Pinto FMSD, de Mello DNP, Utumi ER, Bacci JE, Pedron IG. "Verrucous Carcinoma in the Upper Alveolar Ridge: Case Report with 18-years Follow-up". *SVOA Dentistry* 2:6 (2021) Pages 258-262.

**Copyright:** © 2021 All rights reserved by Pedron IG., et al. This is an open access article distributed under the Creative Commons Attribution License, which permits unrestricted use, distribution, and reproduction in any medium, provided the original work is properly cited.