

# Mucormycosis Involving Maxillary Sinus: A Case Report

Amit Kumar<sup>1\*</sup>, Pranav Nakra<sup>2</sup> and Saurabhachandra Pawar<sup>3</sup>

<sup>1</sup> Post graduate student, Department of Oral and maxillofacial surgery, Mithila minority dental college and hospital, Darbhanga, Bihar, India.

<sup>2</sup> BDS, CNC Arts Department, (Psychology majors) Canada.

<sup>3</sup> Post graduate student, Department of public health dentistry, Sinhgad Dental College and Hospital, Pune, India.

**\*Corresponding Author:** Dr. Saurabhachandra Pawar, Post graduate student, Department of public health dentistry, Sinhgad Dental College and Hospital, Pune, India.

**Received:** July 05, 2021 **Published:** September 23, 2021

## Abstract

Mucormycosis is the third most common fungal infection after candidiasis and aspergillosis.<sup>2</sup> Furthermore, rhino cerebral type is the most common form of mucormycosis, followed by cutaneous, gastrointestinal, pulmonary and disseminated form.<sup>3</sup> The fatality of mucormycosis explain its angio invasive nature, which allows deep penetration through perivascular channels attributing to necrosis and bone destruction and disseminating to orbital and intracranial structure, furthermore, complicating with cavernous sinus involvement and cerebral abscess and infarcts. <sup>4-5</sup> A sixty-two years old female reported to the hospital with unilateral pain and swelling on right side of face. The patient had medical history of diabetes and on regular oral hypoglycemic medication. She was diagnosed COVID -19 positive and was under treatment for the same for one month. Based on the findings a systematic treatment plan was established and followed. Initially the patient was hospitalized and blood sugar levels was cut down to normal with insulin. Excision of the necrotic bone along with 1 cm adjacent bone was accomplished under general anesthesia. Amphotericin -B of 0.8mg/kg/day was administered slowly for over 4-6 hours for two weeks. To avoid renal toxicity regular monitoring of blood urea and creatinine levels was done. The systematic investigations and findings provided a new insight to the management of mucormycosis infection. Though the patient was immunocompromised, but the recent tooth extraction paved a new pathway for the fungus to enter and disseminate in the system.

**Keywords:** Mucormycosis, Maxillary Sinus, Fungal-Infection, Post Covid Infection

## Introduction

Mucormycosis is a rare fungal infection caused by mucormycetes. It is both opportunistic and fatal in nature. The inevitable presence of the fungus in the environment makes it easily exposed to all population but only immunocompromised and uncontrolled diabetes with ketoacidosis is mostly affected. Moreover, upon its invasion, lungs and sinus are the main organs that harbor the microorganisms.<sup>1</sup> Mucormycosis is the third most common fungal infection after candidiasis and aspergillosis. <sup>2</sup> Furthermore, rhino cerebral type is the most common form of mucormycosis, followed by cutaneous, gastrointestinal, pulmonary and disseminated form.<sup>3</sup> The fatality of mucormycosis explain its angio invasive nature, which allows deep penetration through perivascular channels attributing to necrosis and bone destruction and disseminating to orbital and intracranial structure, furthermore, complicating with cavernous sinus involvement and cerebral abscess and infarcts. <sup>4-5</sup> Despite its infrequent incidence, the prevalence rate in India is nearly 70 times higher than the global data with 0.02 to 9.5 cases (with a median of 0.2) per 100,000 persons as suggested by Prakash et al.<sup>6</sup> Therefore, the following case has been presented with aims to portray the clinical presentation of mucormycosis involving the maxilla in uncontrolled diabetic patient and highlighting the diagnosis and treatment.

## Case Report

A sixty-two years old female reported to the hospital with unilateral pain and swelling on right side of face. She complained of moderate pain which aggravated on bending head and chewing food beside nasal congestion and head ache on the same side.

On further examination, the patient had high fever, purulent discharge, paraesthesia and foul odor. The patient had medical history of diabetes and on regular oral hypoglycaemic medication. She was diagnosed COVID -19 positive and was under treatment for the same for one month.

All the vital signs were in normal range when examined. A necrotic bone of 1 cm diameter in the right maxillary region was found along with grade III mobility of maxillary molars and edematous soft tissue (fig 1). Moreover, radiograph of paranasal sinus depicted haziness in right maxillary sinus with erosion in lateral sinus wall. CT scan was performed which shows sinus and other bone linings (fig 2). On biochemical investigation high blood sugar level of 300.06 mg/dL was found. Glycosylated hemoglobin (HBA1C) was 10.60 suggestive of poor control diabetic. (Fig-3) A biopsy was advised and hard tissue specimen along with soft tissue was sent for histopathological examination revealing a non-septate mucormycotic hyphae. Furthermore, Grocott's modified silver methenamine special staining technique also demonstrated similar non-septate branching hyphae of mucormycosis. (fig 4) Based on the above findings a systematic treatment plan was established and followed. Initially the patient was hospitalized and blood sugar levels was cut down to normal with insulin. Excision of the necrotic bone along with 1 cm adjacent bone was accomplished under general anesthesia. Amphotericin -B of 0.8mg/kg/day was administered slowly for over 4-6 hours for two weeks. To avoid renal toxicity regular monitoring of blood urea and creatinine levels was done.

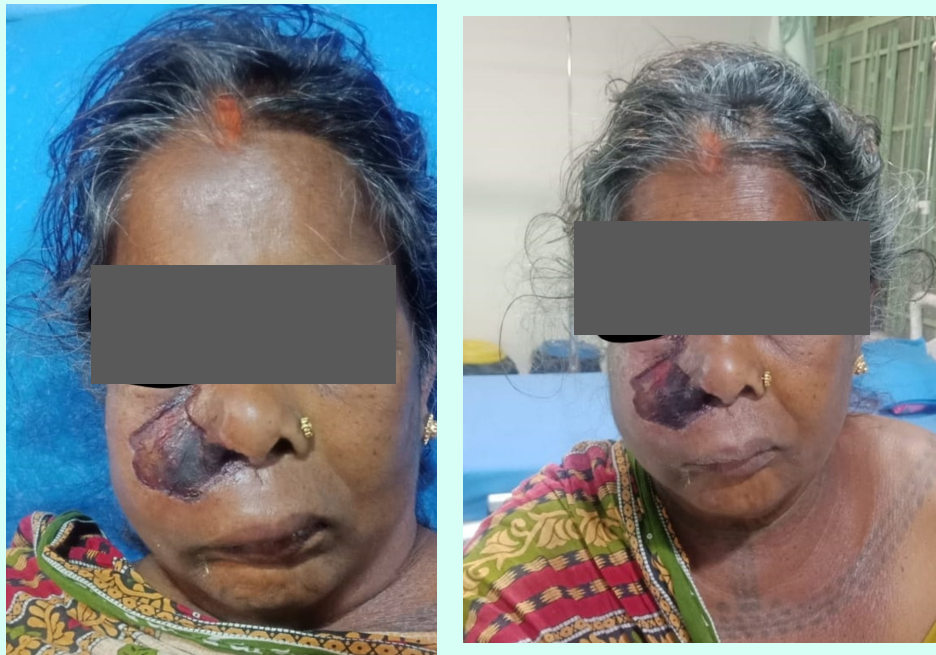

Figure: 1

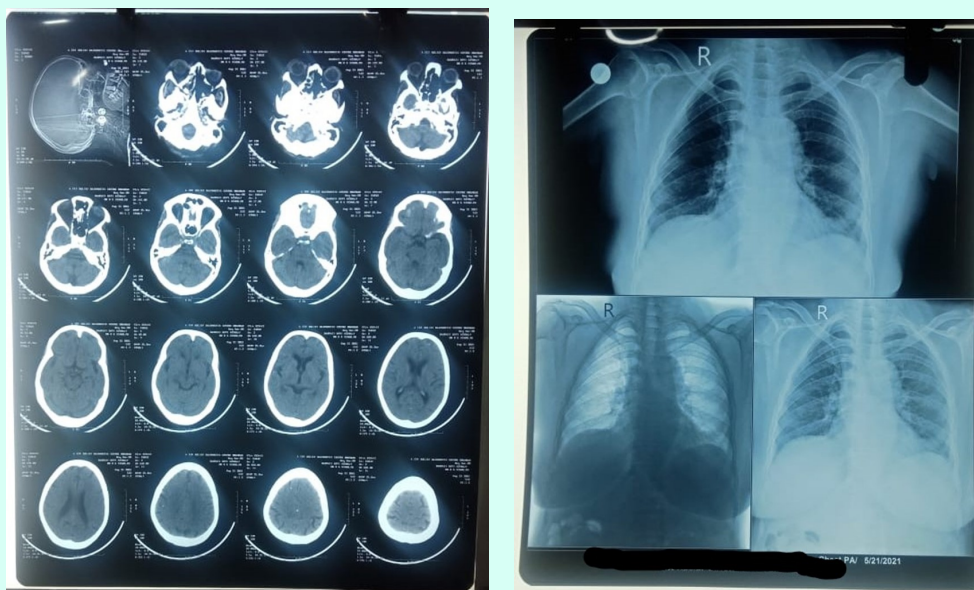


Figure: 2

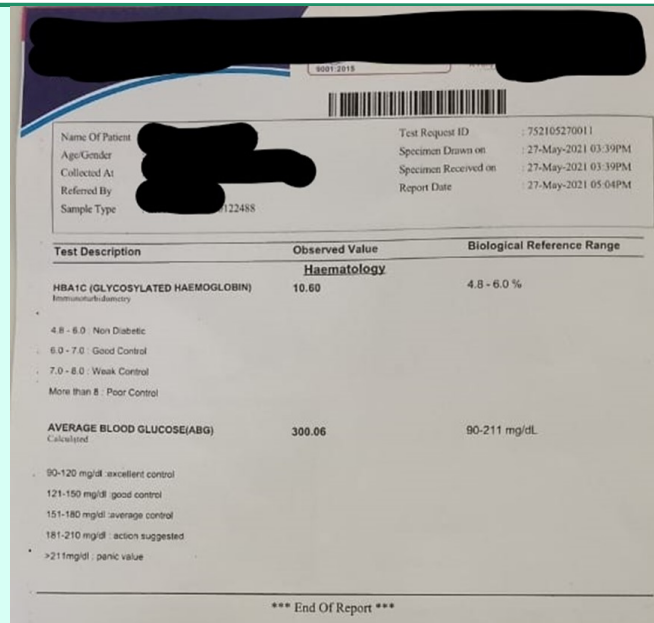

Figure: 3

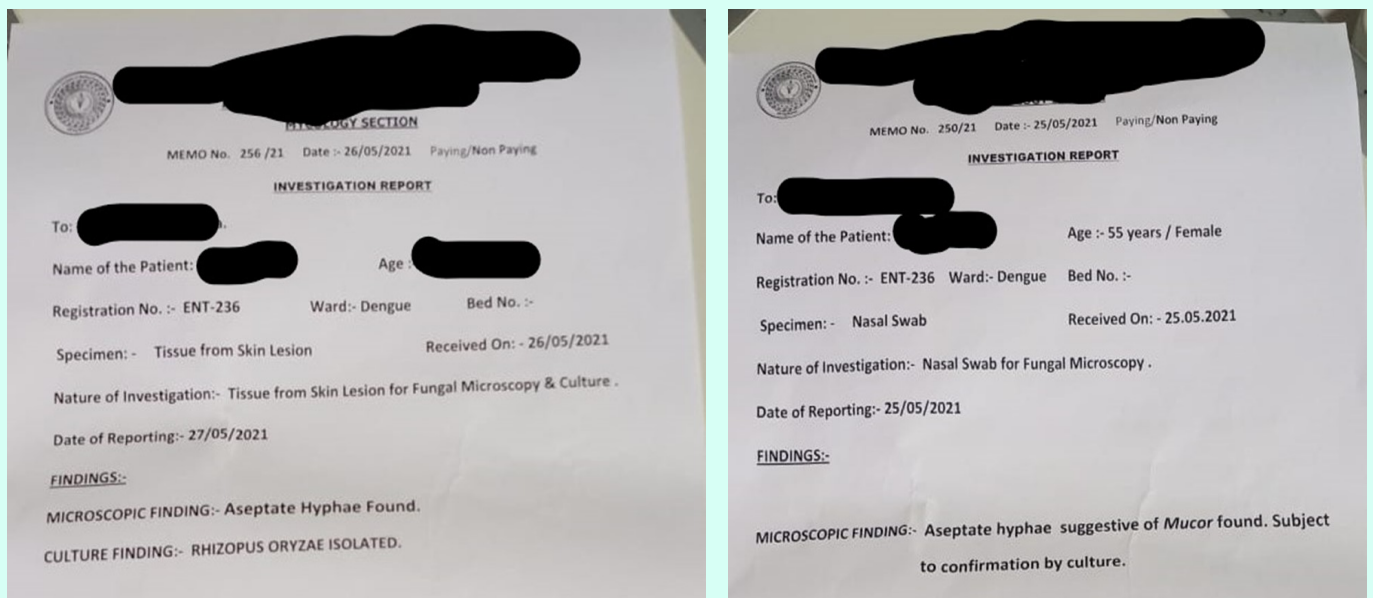


Figure: 4

## Discussion

Initially mucormycosis was known as zygomycosis<sup>1</sup> implicating different diseases caused by infection with fungi belonging to order Mucorales. However, rhizopus are the most common form of fungi which are associated with rhino orbital cerebral mucormycosis. Uncontrolled diabetes with ketoacidosis, malignancies such as lymphoma and leukemia, renal failure, organ transplant, long term corticosteroid and immunosuppressive therapy, cirrhosis, burns, protein energy malnutrition and AIDS are the most common risk factors that are associated with mucormycosis infection.<sup>7-14</sup>

Rhino orbital cerebral mucormycosis infection is the most common form of mucormycosis, usually common among diabetes with poor control of sugar levels, ultimately leading to decreased granulocyte phagocytic ability with altered polymorphonuclear leukocyte response, henceforth, enabling them susceptible to opportunistic fungal infections. Moreover, in the present report, it also emphasized on the importance of post extraction oral hygiene, which created an easy gateway for fungus to enter and attack the already poor defense system.<sup>14</sup>

The fatality of mucormycosis can attributed to delayed bony involvement due to late and poor diagnosis. Therefore, prompt diagnosis with early medical and surgical management plays a crucial role in increasing the survival rate to 80%.<sup>11</sup>

## Conclusion

The systematic investigations and findings provided a new insight to the management of mucormycosis infection. Though the patient was immunocompromised, but the recent tooth extraction paved a new pathway for the fungus to enter and disseminate in the system. Therefore, a patient with COVID-19 having high chance of mucormycosis infection following tooth extraction should alert a clinician of possible mucormycotic infection.

## Conflict of Interest

We Authors declare no conflict of interest in terms of the present study which is submitted.

## Acknowledgement

We Authors of the study acknowledge our parents for their blessings and support. We would also like to thank the team, Theatre of Scientific Coding for guiding us in this case report study.

## References

- Centers for Disease Control and Prevention. Fungal diseases. <https://www.cdc.gov/fungal/diseases/mucormycosis/index.html>. Accessed on 28<sup>th</sup> August
- Deepa A, Nair BJ, Sivakumar T, Joseph AP. Uncommon opportunistic fungal infections of oral cavity: A review. *J Oral Maxillofac Pathol*. 2014 May;18(2):235-43. doi: 10.4103/0973-029X.140765. PMID: 25328305; PMCID: PMC4196293.
- Nilesh K, Vande AV. Mucormycosis of maxilla following tooth extraction in immunocompetent patients: reports and review. *Journal of clinical and experimental dentistry*. 2018 Mar;10(3):e300.
- Park, Y.L., Cho, S. & Kim, JW. Mucormycosis originated total maxillary and cranial base osteonecrosis: a possible misdiagnosis to malignancy. *BMC Oral Health* **21**, 65 (2021). <https://doi.org/10.1186/s12903-021-01411-8>
- Auluck A. Maxillary necrosis by mucormycosis. A case report and literature review. *Med Oral Patol Oral Cir Bucal* 2007;12:E360-4.
- Prakash, H.; Chakrabarti, A. Epidemiology of Mucormycosis in India. *Microorganisms* 2021, 9, 523. <https://doi.org/10.3390/microorganisms9030523>
- Leitner C, Hoffmann J, Zerfowski M, Reinert S. Mucormycosis: necrotizing soft tissue lesion of the face. *J Oral Maxillofac Surg* 2003;61:1354-8.
- Pogrel MA, Miller CE. A case of maxillary necrosis. *J Oral Maxillofac Surg* 2003;61:489-93.
- Zapico ADV, Suarez AR, Encinas PM, Angulo CM, Pozuelo EC. Mucormycosis of the sphenoidal sinus in an otherwise healthy patient. Case report and literature review. *J Laryngol Otol* 1996;110:471-3.
- Jones AC, Bentsen TY, Fredman PD. Mucormycosis of the oral cavity. *Oral Surg Oral Med Oral Pathol* 1993;75: 455-60.
- Salisbury PL 3rd, Caloss R Jr, Cruz JM, Powell BL, Cole R, Kohut RI. Mucormycosis of the mandible after dental extractions in a patient with acute myelogenous leukaemia. *Oral Surg Oral Med Oral Pathol Oral Radiol. Endod* 1997; 83:340-4.
- Buhl MR, Joseph TP, Snelling BE, Buhl L. Temporofacial zygomycosis in a pregnant woman. *Infection* 1992; 20:230-2.
- Napoli JA, Donegan JO. Aspergillosis and necrosis of maxilla: a case report. *J Oral Maxillofac Surg* 1991;49: 532-4.
- Brown OE, Finn R. Mucormycosis of the mandible. *J Oral Maxillofac Surg* 1986;44:1326.

**Citation:** Kumar A, Nakra P, Pawar S. "Mucormycosis Involving Maxillary Sinus: A Case Report". *SVOA Dentistry* 2:6 (2021) Pages 263-266.

**Copyright:** © 2021 All rights reserved by Pawar S., et al. This is an open access article distributed under the Creative Commons Attribution License, which permits unrestricted use, distribution, and reproduction in any medium, provided the original work is properly cited.