

# Prosthetic Rehabilitation of the Lower Jaw with Removable Partial Denture After an Ameloblastoma Surgical Remotion: A Case Report

Angelo Maria Facecchia<sup>1\*</sup>, Roberto Facecchia<sup>2</sup> and Stefano Siliberto<sup>3</sup>

<sup>1</sup>Private Practitioner, DDS, Italy, +393928383006

<sup>2</sup>Private Practitioner, DMS, DDS, Italy, +393395804100

<sup>3</sup>Private Practitioner, DT (Dental Technician), Italy, +393296148586

\*Corresponding Author: Dr. Angelo Maria Facecchia, Private Practitioner, DDS, Italy, +393928383006

Received: September 21, 2022 Published: November 22, 2022

## Abstract

**Background:** The surgical treatment of maxillary tumors often involves bone resection and causes total or partial edentulism of one or both arches. Lack of bone volumes, even in normal condition, is per se a risk factor of bad prosthetic outcomes both in fixed and in removable prosthetic rehabilitation. The objective of this paper is to report a case of social dentistry in which a bone resection performed in a hospital environment has been prosthetically rehabilitated in a suburban private clinic.

**Case presentation:** 62 y/o woman, nonsmoker, partial mandibulectomy in April 2020 due to the diagnosis of a benign ameloblastoma of approximately 15 cm<sup>3</sup>. Exposition of part of the osteosynthesis implanted device caused by a thin mucosal area and second surgery in November 2021. Partial edentulism of the lower jaw caused by the surgical resection with the only presence of the dental elements 36, 37, 46 and 47. These elements were in good periodontal status and free of any cariogenic phenomenon.

**Discussion:** The patient's need and desire, due to economic condition and understandable iatrophobia, was to embrace a non-invasive prosthetic procedure. A removable partial denture, with cobalt-chrome armor and flexible acrylic in the inner side, was realized although wasn't the most indicated treatment plan.

**Conclusion:** The prosthetic rehabilitation of a compromised mandibular situation must be focused on restoring occlusal balance without interfering with the maxillofacial surgery procedures and post-op. In suburban areas, clinics may often encounter patients with lack of economical possibilities and difficult clinical situations, in these cases the aim of an ethical medical professional should be to restore the basic functions with the best possible aesthetic outcome while understanding the patient's need.

**Keywords:** ameloblastoma, removable denture, prosthodontics, chairside procedures.

## Background

Ameloblastoma are rare odontogenic tumors of ectodermic origin.<sup>[1]</sup> Although not commonly diagnosed in suburban clinics, their prosthetic management is difficult and involves different aspects.<sup>[2]</sup>

The surgical treatment of this neoplastic pathology, which could be combined with a pharmacological therapy, varies from case to case but often involves the surgical remotion of bone sections and teeth adding a safety range to the excised tissue to avert possible relapses.<sup>[3]</sup>

When bone changes are associated with edentulism the prosthetic planning generally hinders both in simple and in difficult rehabilitation. Is easy to imagine how the resection of a big mandibular portion could be an obstacle in the path to a new occlusal balance and requires particular attention if the clinician wants to have a stable and not iatrogenic treatment result.<sup>[4]</sup>

## Case presentation

The purpose of this paper is to briefly report an unusual clinical situation as the rehabilitation of partially edentulous alveolar ridge in an oncologic patient.

In this rehabilitation Facecchia R.C. (DMS, DDS) took care of the design of the prosthesis, Facecchia A.M. (DDS) realized the study of the model, oversaw the clinical management, and redacted this paper, while Siliberto S. (DT) handled the laboratory phases.

The patient was a 62 y/o nonsmoker woman, returning from a mandibular resection of approximately 15 cm<sup>3</sup> due to an ameloblastoma with apposition of osteosynthesis grid (Fig. 1). The surgery needed a second phase because of the exposition of part of the implanted device caused by the ulceration of part of the ridgsoft tissues for the exiguous thickness of the mucosal area. The whole surgical procedure was carried out in an hospitalary environment (Ospedale Generale Regionale 'F. Miulli', Acquaviva delle Fonti, BA, Italy).

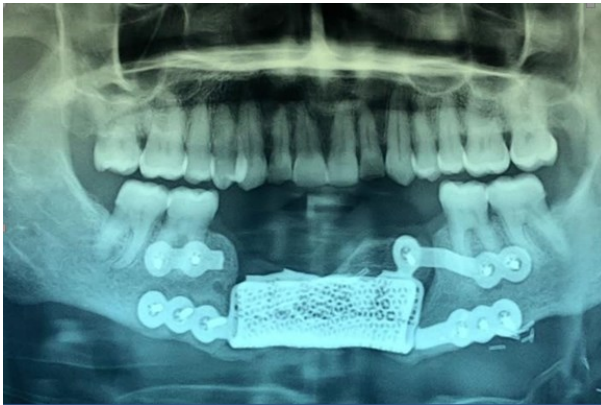

Fig.1: Patient OPT

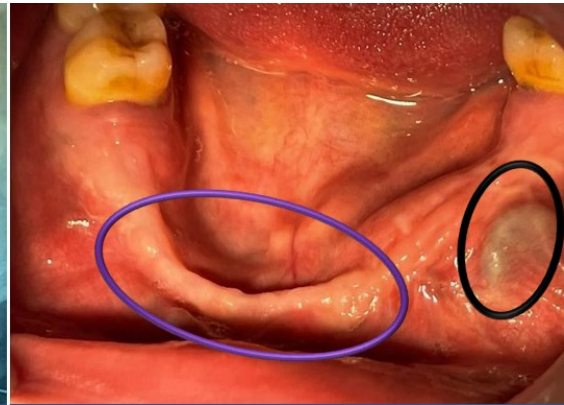


Fig.2: Lower jaw intraoral image

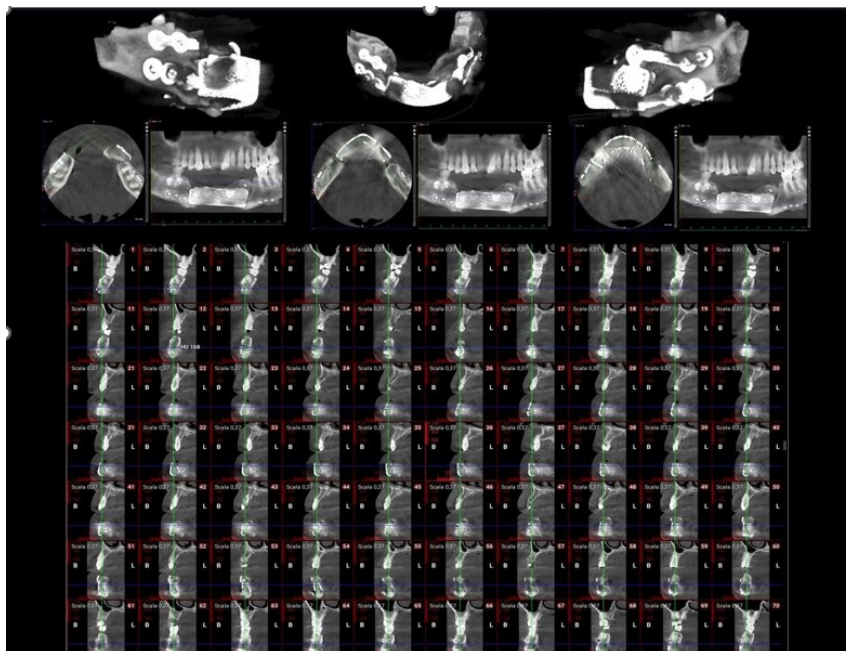
The case was evaluated as a fourth class of Kennedy's classification of edentulism (Fig. 2). In the clinical evaluation the remaining lower molars (elements 36, 37, 46, 47) were in good periodontal status and free of mobility and cariogenic phenomenon.

A Cone Beam Computed Tomography averted contact between molar roots and the osteosynthesis devices. Special care was given at two lower jaw areas:

A fibrotic thickening lacking in bone support considered a potential risk factor for future ulcerations of the free mucosa (circled in purple in Fig.2).

Transparency of the mucosa of the underlying osteosynthesis structure in the corresponding area of the left premolars (circled in black in Fig.2).

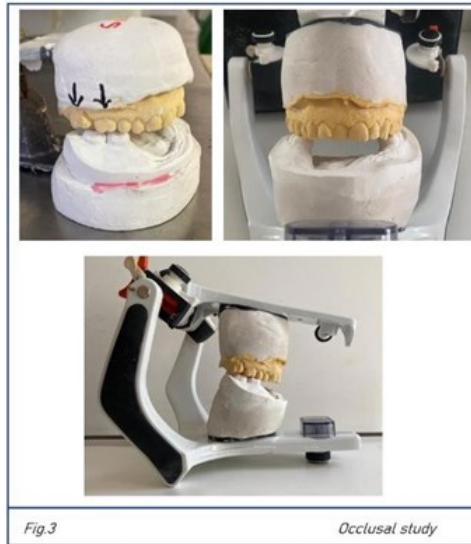The CBCT is reported in the following image.



Study and work models were realized in chalk (Zhermack® Elite Ortho 3 White) on alginate impressions (Zhermack® Hydrogum 5) to realize individual acrylic trays (Kulzer® Paladur) for second polyether impressions (3M® Impregum Garant L Duosoft).

A preliminary occlusor study and average-value articulator (BioArt A7 Plus) mounting was performed and highlighted a skeletal third class emphasized by the partial edentulism (fig. 3), often observable in mandibular resections.<sup>[4]</sup> These traits and the patient’s need of low expenses have directed the prosthetic design towards a removable partial denture with no vestibular and minimum lingual and crestal mucosal support and hooks on 36,37,46 and 47.

The prosthesis eventual poor retention has been object of particular concern because of the limits set by the patient’s socioeconomic situation.



## Discussion

The previously mentioned factors have led to the selection of a soft support (Qdent® Semiflex Acrylic) under the acrylic body of the prosthesis with a light support of the lingual and crestal side and no contact on the vestibular one leaving a safety margin of 2 mm (as traced with graphite on the work model in fig. 5 and 6).

The molar relation maintained in the long oncologic path was taken as reference for the vertical dimension, which was better defined in the chairside mounting process.

To better record protrusion and laterality two molars have been placed in the premolars’ spots during the mounting phase, substituted by two premolars in the final prosthesis with proper readjusting of occlusal balance.

The prosthesis (Fig.7 and 8) was designed as a framework with a metal bar and with two double ring hooks in chromium-cobalt alloy (MESA Magnum H60 chromium-cobalt alloy type 5).

Teeth in shade A3.5 were set for the diatorics (Ivoclar Orthotyp S DCL) and A3 for the anteriors (Ivoclar Vivodent S DCL). The opaquer (Kulzer Signum Opaque F A3) and the soft tissues (Kulzer Pala CRE-ACTIVE) were reproduced in laboratory, as opposed to the fitting test performed with the previously explained methods. During the delivery phase (Fig.9), we made sure to have occlusal balance distributed on the elements, alleviating the protrusion and laterality trajectories in order not to overload the thin fibrointegrated mucosa above the osteosynthesis devices.

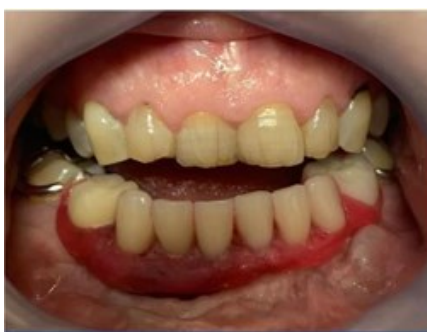

Fig.4

Chairside mounting

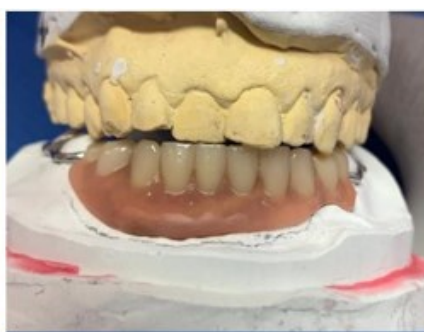

Fig.5

On-model prosthesis view

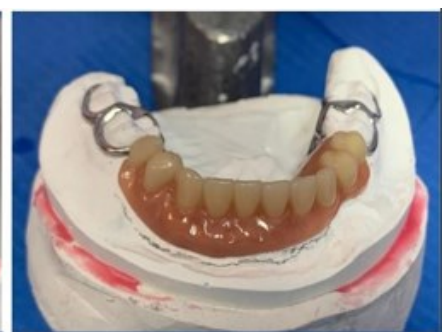
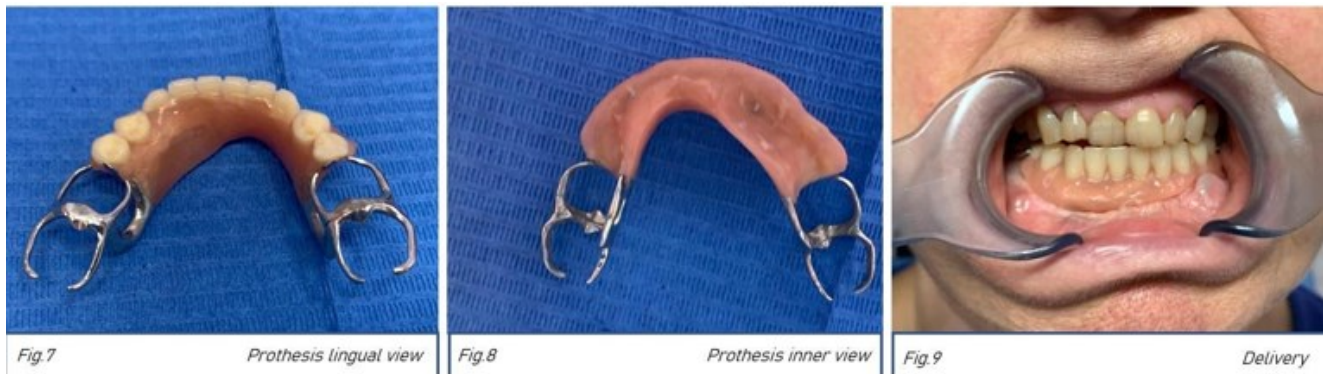
Fig.6

Prosthesis vestibular view





## Conclusion

The prosthetic rehabilitation of compromised mandibular situation must be focused on restoring occlusal balance without interfering with the maxillofacial surgery procedures and post-op.

Elastic materials can be useful to avoid stress on soft tissues and respect underlying structures.

In suburban areas can happen to treat patients with lack of economical possibilities and difficult clinical situations, in these cases the aim of an ethical medical figure should be to restore the basic functions with the best possible esthetic outcome understanding the patient's need.

The authors of this case report hope to provide colleagues an example of a particular case in which many factors came into play and had as background a complex socio-economic situation.

## Conflict of Interest

The authors declare no conflict of interest.

## Acknowledgement

All the authors have obtained permission to acknowledge Stefano Cavallo for the logistic help he has given in the communication between clinic and laboratory. Thanks to Umbra S.p.A. in the person of Francesco D'Onghia providing the clinical and laboratory materials.

## References

1. Palanisamy JC, Jenzer AC. Ameloblastoma. 2022 Jul 4. In: StatPearls [Internet]. Treasure Island (FL): StatPearls Publishing; 2022 Jan-. PMID: 31424749.
2. Anpalagan A, Tzortzis A, Twigg J, Wotherspoon R, Chengot P, Kanatas A. Current practice in the management of peripheral ameloblastoma: a structured review. *Br J Oral Maxillofac Surg*. 2021 Jan;59(1):e1-e8. doi: 10.1016/j.bjoms.2020.08.084. Epub 2020 Aug 21. PMID: 33162201.
3. Evangelou Z, Zarachi A, Dumollard JM, Peoc'h M, Komnos I, Kastanioudakis I, Karpathiou G. Maxillary Ameloblastoma: A Review With Clinical, Histological and Prognostic Data of a Rare Tumor. *In Vivo*. 2020 Sep-Oct;34(5):2249-2258. doi: 10.21873/invivo.12035. PMID: 32871747; PMCID: PMC7652510.
4. Pekkan G, Hekimoglu C, Sahin N. Rehabilitation of a marginal mandibulectomy patient using a modified neutral zone technique: a case report. *Braz Dent J*. 2007;18(1):83-6. doi: 10.1590/s0103-64402007000100018. PMID: 17639208.

**Citation:** Facecchia A.M, Facecchia R, Siliberto S. "Prosthetic Rehabilitation of the Lower Jaw with Removable Partial Denture After an Ameloblastoma Surgical Remotion: A Case Report". *SVOA Dentistry* 2022, 3:6, 245-248.

**Copyright:** © 2022 All rights reserved by Facecchia A.M., et al. This is an open access article distributed under the Creative Commons Attribution License, which permits unrestricted use, distribution, and reproduction in any medium, provided the original work is properly cited.