

The Bone Lid Technique in Oral Surgery Using Piezoelectric Device: Breaching Science with Clinical Practice, A Clinical Case Report and Literature Review

Faouzi Riachi^{1*}, Carine Tabarani², Daniel Tahchy³, Bachar Hussein³ and Nicolas Khoury³

¹DDS, MSC Oral Surgery, Periodontology, Former Chairman Oral surgery department- Saint Joseph University-Beirut-Lebanon.

²DDS, MSC Oral Surgery, Implantology, Oral Medicine, Senior Lecturer-Private Practice exclusive, Consultant Oral Surgery, Implantology, Oral Medicine, Abu Dhabi-U.A. E.

³Department of Oral Surgery, Faculty of Dental Medicine, Saint-Joseph University- Beirut- Lebanon.

*Corresponding Author: Dr. Faouzi Riachi, DDS, MSC Oral Surgery, Periodontology, Former Chairman Oral surgery department- Saint Joseph University-Beirut-Lebanon.

Received: November 21, 2022 **Published:** December 02, 2022

Abstract

The aim of the present article is to discuss the application of bone lid technique using piezoelectric device as an atraumatic surgical option when facing a deeply impacted tooth in order to optimize implant rehabilitation in the ideal position. The following article sheds light on the steps of the surgical bone lid technique using piezoelectric device and discusses its outcomes in limiting the post-operative bone resorption and enhancing implant placement through a peer literature review and a case report.

Keywords: Bone lid, Dental implant, Impacted tooth, Piezo surgery.

Introduction

The removal of impacted teeth is one of the most common procedures in oral and maxillo-facial surgery. Even though the procedure may be simple to apply in many cases, serious complications can arise depending on the location and position of the impacted teeth (1). Furthermore, the removal of impacted teeth itself can result in volumetric bone defects due to excess osteotomies. In some cases, large defects cannot be completely restored without the need for bone augmentation procedures, which may be required for implant placement (2).

The bone lid technique using piezoelectric device has been described as an alternative approach to conventional osteotomies. The purpose of this technique is to improve intraoperative visibility while avoiding the formation of bone defects using an immediate reconstructive approach (3). It is also indicated in cases of fractured implants removal, cystectomies, removal of deeply fractured roots or impacted teeth (2,4). The above method involves the creation of the bone window or lid, with direct access to the surgical site, followed by repositioning of the lid with or without fixation (5). The repositioned lid will isolate the bone cavity allowing the repopulation of osteogenic cells and preventing the non-osteogenic cell population, mainly the epithelial cells, fibroblast, and other connective tissue cells from invading the cavity (6). Burs and micro-saws were commonly used to create the bone lid until recent years where piezoelectric devices have been introduced presenting many advantages for both patient and operator, in conserving bone structure, heat reduction and preventing any traumatic intervention affecting the lower alveolar nerve (7), the main advantage remain lowering the bleeding in the surgical field by cavitation effect.

This case report illustrates the extraction of an impacted mandibular premolar in the lower left jaw using bone lid technique associated to piezo-electric device followed by implant supported rehabilitation.

Clinical Case Report

A 50-year-old female patient was referred to our center for dental implant rehabilitation of the mandibular left premolar zone. Clinical examination revealed an edentulous left mandible, with adequate vertical dimension for implant restoration. Panoramic radiograph showed an impacted second premolar, tooth # 20 (Fig 1A). Extraction of the impacted premolar was planned prior to implants placement. A CBCT was done in order to assess the position of the premolar and its relationship with the inferior alveolar nerve, where it showed an impacted second premolar positioned coronal to the inferior alveolar nerve, within the limits of the buccal and lingual cortices (Fig.1B).

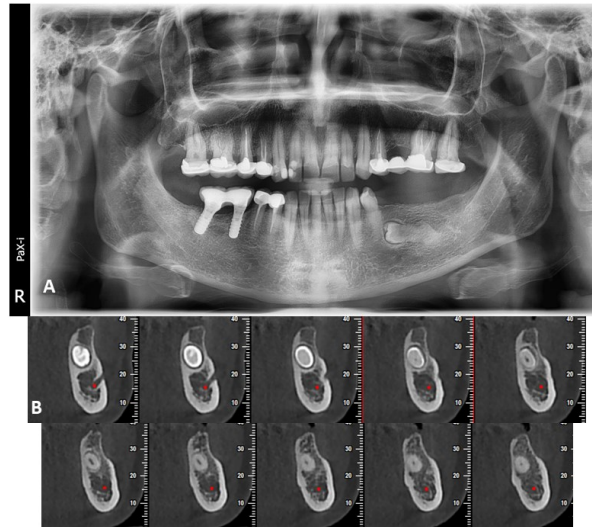


Fig 1: Pre-operative radiographic view: (A) orthopantomogram showing the maxillofacial complex, (B) cross sectional view of the cone beam computed tomography showing the premolar and its relation with the surrounding anatomical structures

The surgery was planned and performed under local anesthesia 4% articaine with epinephrine 1:100,000 (Septanest, Septodont, Saint Maur des Fosses, France), inferior alveolar nerve block with lingual and buccal infiltrations were conducted following by a linear incision and a mucoperiosteal flap elevation (Fig. 2B). The piezoelectric device (Mectron S.P.A, Italy) with inserts (OT4, OT8L, OT8R) were used in order to insure a precisely defined bony window in the extended reflection area of underlying teeth on the vestibular cortical plate of mandible, providing access to the impacted tooth (Fig. 2C). The osteotomy was performed to obtain an internal beveled angle in order to facilitate the subsequent removal and adjustment of the bony lid. The bone lid was then elevated with a bone chisel using progressive movements in order to avoid any possible fracture (Fig. 2D). After its removal, the lid was placed in a sterile saline solution. The tooth was sectioned and removed using the extraction tip EX1 (Fig. 3A,3B). Following the tooth removal, the cavity was filled using a collagen fleece (CollaTape, Zimmer Biomet, USA) and the removed bony lid was repositioned in situ (Fig.3C). Digital pressure was applied to assure its proper repositioning in its original place. No bone substitutes or membranes were used (Fig.3D). The flap was sutured in place using a 5.0 resorbable suturing material (Novosym, B-Braun, Melsungen, Germany). Antibiotics were initiated one day before surgery and carried on for 7 days following surgical procedure (Amoxicillin-Clavulanic acid 2 g/day orally) (Augmentin, GlaxoSmithKline, Brentford, United Kingdom). Postoperative medication also included ibuprofen 400 mg (Abbott Laboratories, Illinois, CHI, USA), three times daily for 3 days, and a chlorhexidine mouthwash (0.12%), three times daily for 2 weeks. The healing was uneventful, only minor swelling and pain were observed on the second day following surgery on clinical follow-up. Two weeks following the surgical procedure, healing by primary intention with no sign of inflammation was noted.

A cone beam computed tomography (CBCT) was done 6 months following the procedure revealing a partial radiographic bone healing at surgical site (Fig. 3A, B, C). Interestingly, no ridge collapse was noted. Two dental endosteal root form implants (Any ridge, Megagen, South Korea) were placed without any need for bone grafting (Fig. 4B). The implants were clinically and radiographically evaluated at the end of the healing period, at 3 months. Prosthetic rehabilitation was conducted 3 months following the surgical procedure (Fig. 4A).

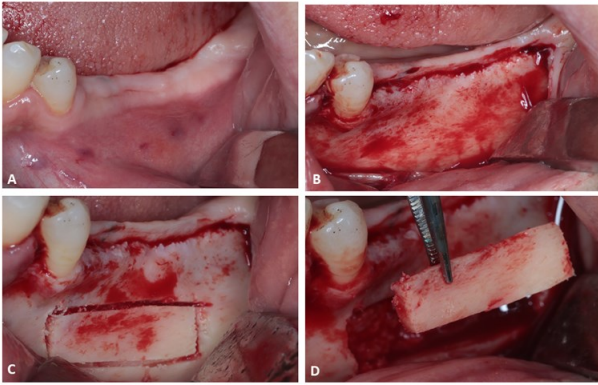


Fig 2: Clinical view of surgical site: (A) Pre-operative view, (B) The bone exposure following the mucoperiosteal flap elevation, (C) Demarcation of the bone lid using the piezoelectric inserts, (D) Removal of bone window.

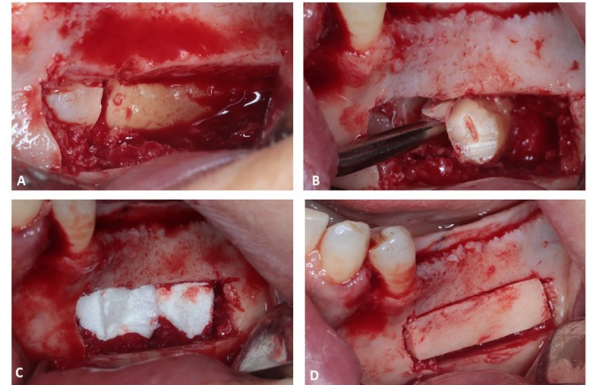


Fig 3: Clinical view of surgical procedure: (A) The osteotomy line separating the crown of the tooth's root, (B) Luxation and removal of the tooth, (C) Application of collagen fleece in the wound site, (D) Repositioning of the bone lid.

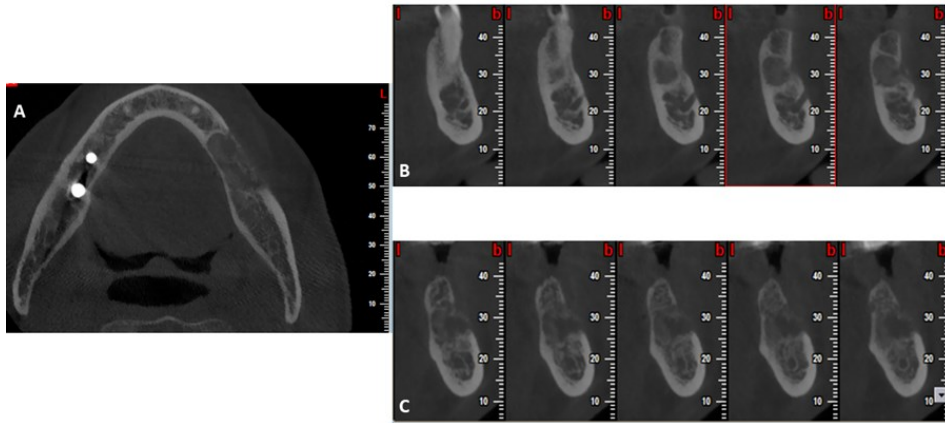


Fig 4: Post-operative cone beam computed tomography images: (A) Axial view of the mandible showing healing of the site, (B) cross sectional view showing the cavity filled partially with bone.

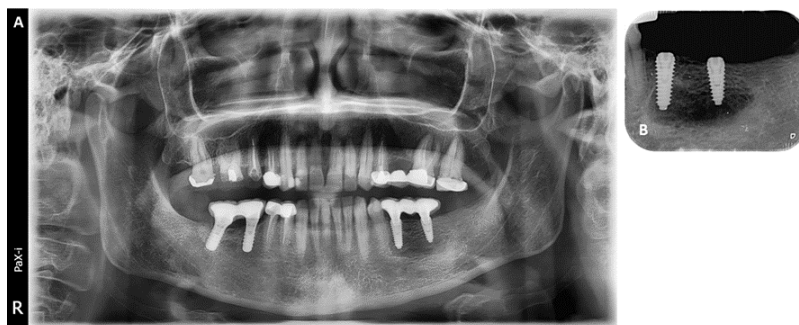


Fig 5: Radiographic examination following the implant placement: (A) Orthopantomogram showing implants and fixed crowns, (B) Periapical image showing the implants placement.

Discussion

The bone lid technique has several indications in oral surgery, including the removal of deeply impacted teeth, and reducing bone loss during enucleation of intraosseous lesions (3). It is also applied in endodontic surgeries of molar teeth, removal of foreign bodies from the maxillary sinus, removal of fractured implants, and removal of residual root fragments (2). The bone lid technique was shown to simplify treatment, avoiding large bone loss and ensuring adequate bone volume for dental implants placement. In the following case report, we reported the extraction of impacted mandibular premolar using the bone lid technique associated to piezoelectric device while also achieving implant rehabilitation.

Cho et al. (15) showed that repositioning a bony window after sinus graft surgery will act as a barrier membrane with additional osteogenic effects. As a result, this autogenous bony membrane will promote external cortical healing and a higher percentage of vital bone formation. The bone window helped in the maintenance of an isolated space preventing the entry of non-osteogenic cells and in which a blood clot could form, eventually leading to complete bone formation.

The repositioned lid mobility may interfere with the healing of the osteotomy margins, resulting in bone necrosis and sequestration. To avoid any complications, the repositioned lid can be stabilized with miniplates and screws (16). Khoury reported that rigid bone lid fixation is not required if the lid's edge has a beveled angle (2). Due to mesial and distal beveling in the present case, we were able to achieve an exact fit so that no additional fixation was needed.

Khoury et al. reported a prospective case series of 200 consecutive patients treated with a bone lid technique using a micro-saw and followed-up for 4 years (8). In 76 patients, implant insertions or grafting procedures were performed at the same time with the bony lid technique. In the other 126 patients, the bony lid technique was done with no associated procedures. In this study, re-entry revealed a well-integrated vestibular bone wall with volume stability in 98.5% of cases (8). The author concluded that the bone lid technique in pre-implant and implant surgery showed excellent outcomes.

Sivolella et al. treated 21 consecutive patients with various mandibular alveolar bone lesions (cysts, endodontic lesion, keratocystic odontogenic tumors and impacted teeth) using the bone lid technique associated to piezoelectric device and followed-up for 12 months (9). The lesion and bone lid healed completely in 19 of the 20 cases; one patient had permanent mild paresthesia, with trauma-induced bone lid necrosis. A year after the procedure, the lines of the osteotomy were no longer visible radiographically in all the cases treated due to perfect reintegration of the bone lid with the surrounding bone. Computed tomography analysis on 11 cases, revealed good recovery in 93.8% of cases (9). Authors concluded that using bone lid technique prevents the formation of large residual bone defects after treatment of mandibular alveolar lesions, thereby eliminating the need for additional augmentation procedures.

Ali et al. reported a prospective clinical and radiographic study of ten patients treated with the bone lid technique for the extraction of deeply impacted lower third molar (10). A radiographic examination was conducted immediately after surgery and in the six following months to estimate the mean bone density of the buccal bone. By the end of the follow-up period, all cases had normal lower lip sensation, a decrease in pain intensity score, and uneventful wound healing with no signs of infection. After six months, mean bone density showed a statistically significant change in buccal bone density but a statistically non-significant difference in crestal bone density (10). The authors explained that despite a decrease in recorded buccal bone density in the postoperative scan, the recorded values were within the normal physiological values reported at the site with D1 bone quality. Which may indicate a normal bone healing with preservation of the buccal contour of the alveolar bone (10). This study indicated that the use of bone lid technique results in a predictable and satisfactory outcome in reducing bone defect.

A retrospective case series study using buccal osteotomy by piezo-surgery as a surgical approach for removal of deep impacted mandibular teeth was published by Scolozzi in 2021 (11). In this study, 23 mandibular-impacted teeth in 6 patients were extracted using the bone lid technique (8 third molars, 6 second molars, 1 first molar, 4 second premolars and 4 first premolars). After completion of the extraction, the bone window was repositioned and miniplates and monocortical screws were used for the fixation of bone window. All patients were followed up on at 1, 3, 6, and 12 months, and no major or minor complications were noted. The author concluded that the above technique provided great surgical exposure for the safe removal of deeply impacted mandibular teeth, especially in situations where conventional techniques either do not provide adequate visibility or significantly increase the risk of surgical complications such as inferior alveolar nerve injury and mandibular fracture (11).

Jung et al. treated 10 patients with the modified bone lid technique to remove or replace compromised implants (12). The bony lid technique was modified by limiting the size of the bony lid, performing guided bone regeneration, immediate implant placement, and providing rigid fixation including fixation screws and microplates (12).

No complications occurred in all the 10 cases. The result showed that replacing failing dental implants can be successfully accomplished by removing cortical bone on the buccal aspect of the implant and then replacing bone after the implant removal. Using allogenic bone, fixation screws, microplates play an important role in the following procedure (12).

Biglioli et al. treated 36 patients presenting with oral implants displaced into the maxillary sinus with no signs of acute or chronic sinusitis using the bony window technique as an intraoral approach to retrieve these implants (13). This technique is initiated by creating a rectangular bony window to expose the maxillary sinus cavity with the creation of two pairs of holes in this window to allow its stabilization at the end of the surgical procedure with sutures. Removal of oral implants from the maxillary sinus was achieved in all patients, and postoperative recovery was uneventful in all of them (13). Post-operative computed tomography revealed no signs of residual sinus infection in all patients. There was no significant resorption of the window, and the thin gap between the window margins and the surrounding bone disappeared entirely. According to the authors' experience, it can be concluded that this intraoral approach with the creation of a bony window pedicled to the sinus mucosa is a simple and safe procedure to remove foreign bodies such as oral implants displaced into the maxillary sinus (13).

Aliyev et al. used the bone lid technique for the removal of a residual root and implant placement simultaneously (14). The bone window was used to preserve the marginal bone integrity in this case, and bone loss in the implant's margin was minimized. There was no need for a bone augmentation procedure. (14)

The use of piezoelectric technology in the above case contributed in a significant way in terms of minimally invasive osteotomy. The beveled angle design and its selective cutting mode played an important role in optimizing the surgical outcomes (17). Furthermore, unlike micro saws and burs, ultrasonic vibrations and its cavitation effect, break down the irrigation liquid into very small particles that wash away from the operation field, reducing the bleeding, and allowing excellent intraoperative visibility(18,19).

In conclusion the ultimate association of bone lid technique to the piezoelectric device showed promising results in terms of bone conservation, implant placement in optimal position with satisfactory outcomes.

Conclusion

The objective of the following article was to shed light on the advantages of using synergistically the bone lid technique associated to piezoelectric device which showed being a minimally invasive technique when used in the removal of impacted mandibular premolar followed by implant placement. The harvested bone lid using piezoelectric device was used as a rigid autogenous membrane in preserving the marginal bone integrity therefore optimizing the implant rehabilitation outcomes.

Conflict of Interest

The authors declare no conflict of interest.

References

1. Scolozzi P. Buccal corticotomy using piezosurgery as a surgical approach for removal of deeply impacted mandibular teeth: An alternative procedure to avoid pitfalls associated with the conventional technique. *Journal of stomatology, oral and maxillofacial surgery*. 2021; 180-252.
2. Fouad Khoury. The bony lid approach in pre-implant and implant surgery: a prospective study. *Eur J Oral Implantsol*. 2013;6(4):375-84.
3. Sivolella S, Brunello G, Fistarol F, Stellini E, Bacci C. The bone lid technique in oral surgery: a case series study. *International journal of oral and maxillofacial surgery*. 2017 Nov 1;46(11):1490-6.
4. Younes R, Nasseh I, Lahoud P, Wassef E, Dagher M. Bone Lid Technique Using a Piezoelectric Device for the Treatment of a Mandibular Bony Lesion. *Case reports in dentistry*. 2017;2017.
5. Khoury F, Hensher R. The bony lid approach for the apical root resection of lower molars. *International journal of oral and maxillofacial surgery*. 1987;16(2):166-70.
6. Hämmerle CHF, Schmid J, Lang NP, Olah AJ. Temporal dynamics of healing in rabbit cranial defects using guided bone regeneration. *Journal of oral and maxillofacial surgery*. 1995;53(2):167-74.
7. Pappalardo S, Guarnieri R. Randomized clinical study comparing piezosurgery and conventional rotatory surgery in mandibular cyst enucleation. *Journal of cranio-maxillo-facial surgery : official publication of the European Association for Cranio-Maxillo-Facial Surgery*. 2014;42(5).

8. Khoury F, Schloss P. The bony lid approach in pre-implant and implant surgery: a prospective study. *Eur J Oral Implantol* . 2013 .
9. Sivolella S, Brunello G, Fistarol F, Stellini E, Bacci C. The bone lid technique in oral surgery: a case series study. *Int J Oral Maxillofac Surg*. 2017 Nov 1 ;46(11):1490–6.
10. Ali Y, El-sabagh A, Sweedan A. Evaluation of buccal bone lid technique using piezoelectric surgery in deeply impacted third molar. *Alexandria Dental Journal*. 2020(11); 51-67.
11. Scolozzi P. Buccal corticotomy using piezosurgery as a surgical approach for removal of deeply impacted mandibular teeth: An alternative procedure to avoid pitfalls associated with the conventional technique. *J Stomatol Oral Maxillofac Surg* . 2022;123(2).
12. Jung SR, Bashutski JD, Linebaugh ML. Application of modified bony lid technique to remove or replace compromised implants: Case series. *Implant Dentistry* [Internet]. 2013 Jun [cited 2022 Apr 6];22(3):206–11.
13. Biglioli F, Chiapasco M. An easy access to retrieve dental implants displaced into the maxillary sinus: the bony window technique. *Clinical Oral Implants Research* [Internet]. 2014 Dec 1;25(12):1344–51.
14. Aliyev T, Efeoğlu B, Rizaj X, Şahin O. Removal of the residual root and implant therapy simultaneously via bone lid approach. *Nigerian Journal of Clinical Practice*. 2019 May 1;22(5):739.
15. Cho Y-S/ P-K/ P-J. Bony Window Repositioning Without Using a Barrier Membrane in the Lateral Approach for Maxillary Sinus Bone Grafts: Clinical and Radiologic Results at 6 Months. *Journal of oral and maxillofacial implants*. 2012 Jan;27(1):211–7.
16. Sivolella S, Brunello G, Berengo M, De Biagi M, Bacci C. Rehabilitation With Implants After Bone Lid Surgery in the Posterior Mandible. *Journal of oral and maxillofacial surgery : official journal of the American Association of Oral and Maxillofacial Surgeons*. 2015 Aug 1;73(8):1485–92.
17. Robiony M, Polini F, Costa F, Vercellotti T, Politi M. Piezoelectric bone cutting in multipiece maxillary osteotomies. *Journal of oral and maxillofacial surgery : official journal of the American Association of Oral and Maxillofacial Surgeons*. 2004;62(6):759–61.
18. Sortino F, Pedullà E, Masoli V. The piezoelectric and rotatory osteotomy technique in impacted third molar surgery: comparison of postoperative recovery. *Journal of oral and maxillofacial surgery : official journal of the American Association of Oral and Maxillofacial Surgeons*. 2008 Dec;66(12):2444–8.
19. Eggers G, Klein J, Blank J, Hassfeld S. Piezosurgery: an ultrasound device for cutting bone and its use and limitations in maxillofacial surgery. *The British journal of oral & maxillofacial surgery*. 2004 Oct;42(5):451–3.

Citation: Riachi F, Tabarani C, Tahchy D, Hussein B, Khoury N. “The Bone Lid Technique in Oral Surgery Using Piezoelectric Device: Breaching Science with Clinical Practice, A Clinical Case Report and Literature Review”. *SVOA Dentistry* 2022, 3:6, 249-254.

Copyright: © 2022 All rights reserved by Riachi F., et al. This is an open access article distributed under the Creative Commons Attribution License, which permits unrestricted use, distribution, and reproduction in any medium, provided the original work is properly cited.