

3D Guided Implant Placement for a Single Anterior Tooth: A Case Report

Layla Assila^{1*} and Zouheir Ismaili²

^{1,2} Faculty of Dental Medicine, University Mohamed V of Rabat, Morocco

*Corresponding Author: Layla Assila, Faculty of Dental Medicine, University Mohamed V of Rabat, Morocco.

Received: March 16, 2022 Published: June 20, 2022

Abstract

As appropriate implant positioning is crucial to long-term successful biological, functional and esthetic outcome, implant dentistry has recently been based on prosthetically driven approach in every step of the whole procedure. Moreover, the main challenge in implant dentistry, is to reproduce as accurately as possible the same implant location previously determined during the case study. The guided implant surgery simplifies the fulfillment of the conditions above leading to implant and restoration success. The 3D static guided implant surgery has a clear workflow allowing digital implant planning, virtual visualization of the final restoration and the transfer of all using a computer-generated surgical guide. This technique is indicated in many cases, accomplishes plenty of advantages and guarantee higher accuracy.

Keywords: implant placement, digital workflow, immediate loading, single tooth, anterior maxilla

Introduction

In implant dentistry, one of the main challenges have been the establishment of an ideal implant placement to obtain an optimal restorative outcome, for poorly placed implants may lead to immediate complications (such as violation of nearby vital structures) or mid-term revealed inadequate results (marginal bone loss, emergence profile...), and more technical time and cost-consuming obstacles. (1)(2)(3)(4)

Three dimensional (3-D) guided implant surgery is a recent concept intended to facilitate the placement of the implant by planning its final position prior to surgery. (1) It is a revolutionary process due to a number of disruptive advances in digital technologies.

Computer Aided-Design / Computer Assisted- Manufacturing (CAD/CAM), Cone Beam Computerized Tomography (CBCT), and surface scanning technologies, either intra- or extra- oral, have allowed a 3-D view of anatomical structures of the patient, with a superimposition of the prosthodontic project. A virtual representation of the patient's maxilla can be viewed on an implant planning software with the needed data about soft tissue, hard tissue and anatomical structures. The software enables the clinicians to make a treatment plan as well as virtually execute the surgery, with anatomical considerations, in accordance with prosthetic needs, and in an accurate manner. The planned data of implant placement are then transferred to fabricate surgical drill guides. This template makes it possible for the operator to place implants in the pre-planned position. The 3-D guided surgery allows an immediate loading, when possible, as the provisional restoration can be provided with the surgical guide. (5)(6)(7)(8)

The aim of this case report is to show the steps of a static 3-D guided implant placement, with immediate loading in an esthetic zone, and the benefits of this treatment option.

Case Report

A 25 year old male patient was referred to dental clinic of University Hospital of Rabat; Centre de Consultations et Traitements Dentaires de Rabat (CCTD CHU Rabat), for the replacement of the #21 (fig1), missing due to a traumatic root fracture. Socket preservation using a bovine derived xenograft material and collagen membrane was performed after the extraction.

The patient was healthy with no remarkable history.

Intra-oral periapical radiograph, maxillary and mandibular diagnostic impression were taken. An intraoral exam revealed: an adequate oral hygiene, an average smile line, sound adjacent teeth, beneficial occlusion as well as favorable soft and hard tissue dimensions. As a provisional restoration, the patient had an Essix appliance with a bonded acrylic tooth which he was not totally satisfied about.

Restoration options that were proposed to the patient included: implant replacement, resin-bonded bridge, or a cemented bridge. Reshaping the adjacent teeth is a must for replacement of the missing tooth by a bridge as it was explained to the patient. Taking into consideration the age of the patient, the intact adjacent teeth, and his esthetic concern, the chosen option was an implant supported crown with guided surgery and an immediate loading if possible.

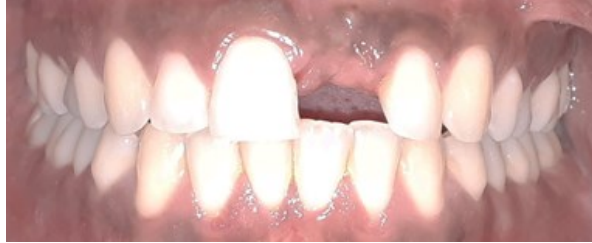

Figure 1: Single missing tooth in the esthetic zone.

Treatment steps:

1. Data collection: A CBCT was recorded for the patient (fig.2) and an extra-oral scan of the maxillary cast was recorded (fig.3).

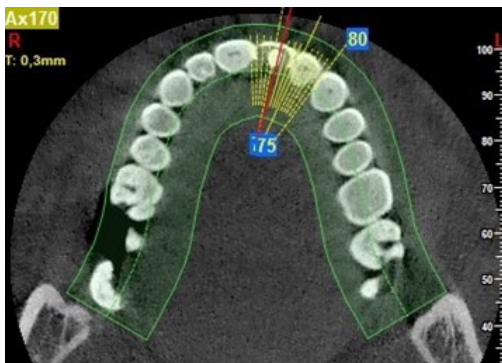


Figure 2: CBCT scan of the patient.

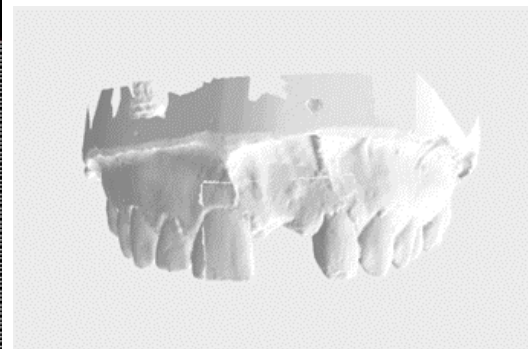


Figure 3: Extra-oral scan of the maxilla's model.

1. 3-D Treatment Planning:

A CBCT DICOM file, and an STL file of the models were then saved and transferred to the 3D treatment plan software (R2Gate®, MegaGen implants, Korea) where a matching allows the superimposition of the virtual cast and the maxilla scan (fig.4).

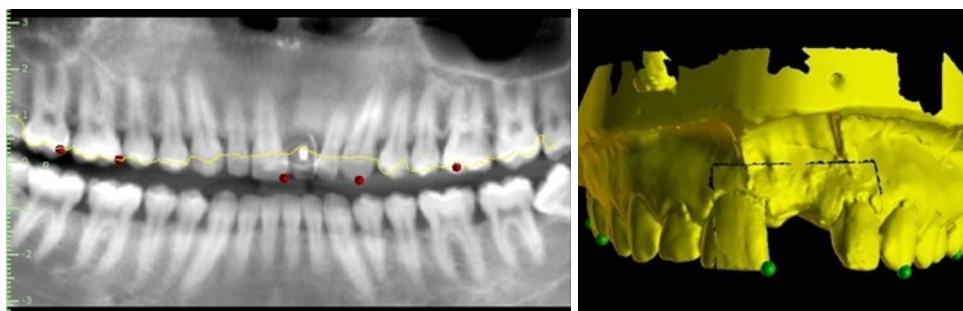


Figure 4: Matching the CBCT and the virtual cast to obtain their superimposition.

A virtual wax up and provisional tooth set-up for a prosthetic restoration, were planned on the virtual model (fig.5).

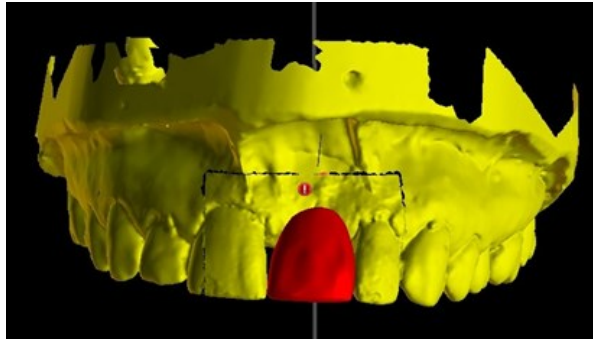


Figure 5: Virtual wax-up of the missing tooth.

The evaluation of the CBCT showed sufficient thickness of buccal and palatal alveolar bone around tooth #21. An implant of 3,5mm diameter and 13mm length was planned. The dimensions and the 3-D orientation of the implant were discussed, prosthetically driven, and respected the anatomical structures (fig.6).

After the approval of the planification, a virtual surgical guide was created. The data files were sent in order to proceed with the 3-D printing of the surgical guide (fig.7) and the manufacturing of the screw retained provisional restoration (fig.8).

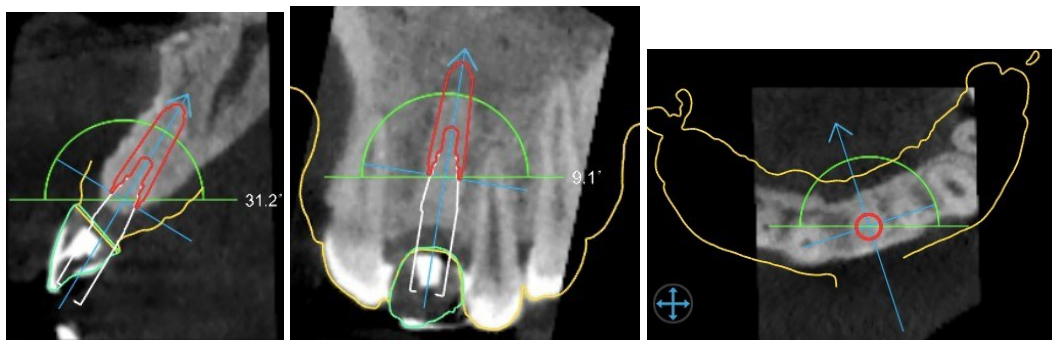


Figure 6: Implant placement planification according to the virtual wax-up and vital structures and the bone.

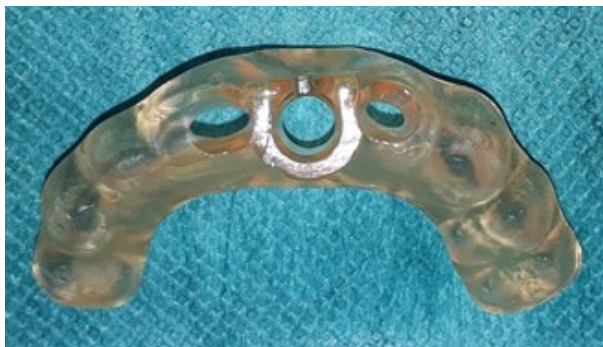

Figure 7: Teeth-supported surgical guide.



Figure 8: Screw-retained CAD/CAM fabricated provisional restoration.

2. Surgery Procedure

After the fit of the surgical guide was verified intraorally (fig.9), the implant surgery was performed under local anesthesia. It was initiated with a full thickness flap.

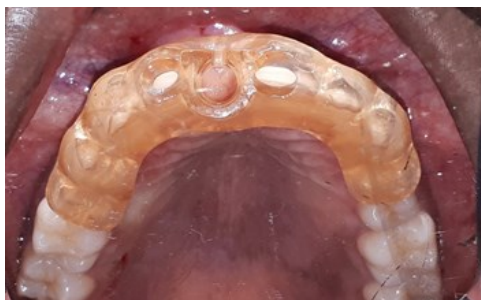

Figure 9: The surgical guide should be tried before the surgical procedure to be sure of its accurate fit.

The surgical protocol (fig.10), provided with the surgical template, recommended a specific sequence of instruments used for the preparation of the implant site according to the used implant system and kit (AnyRidge® MegaGen implants), and the bone density revealed in the planification software (R2Gate® MegaGen implants).

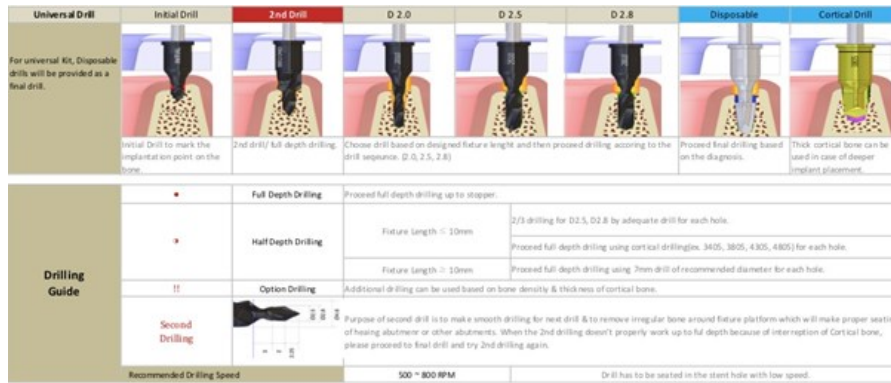

Figure 10: The drilling sequence is provided with details about the depth and the speed of each instrument.

The bone preparation was performed with continuous cooling and sterile saline, following the the exact sequence of drill diameters and lengths. The depth of the osteotomy was checked by the stop on each drill. Then the implant (3,5mm – 13mm) was placed and an insertion torque of 35 Ncm was obtained.

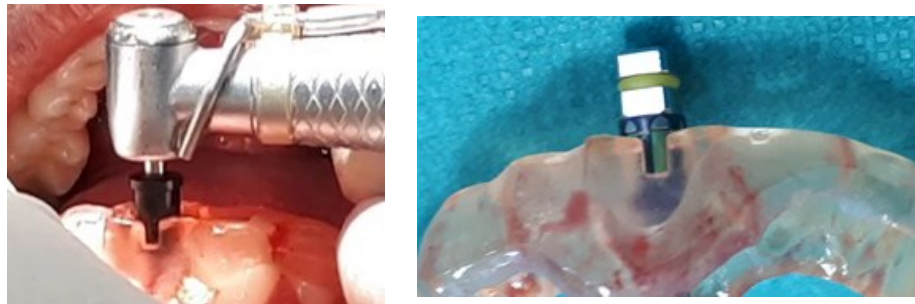


Figure 11: The depth of the drilling and the implant placement is checked through the surgical guide window on a colored stop.

A primary implant stability measurement indicated an ISQ of 75 which allowed the placement of the provisional restoration in the same day (fig.12).

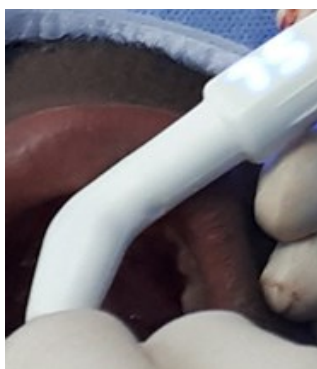

Figure 12: For an immediate loading the primary stability is quantified by measuring the ISQ.

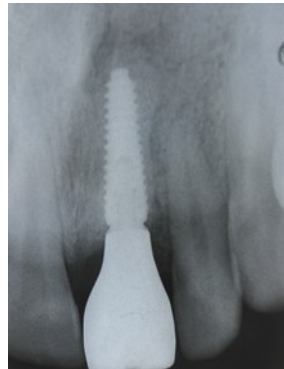

Figure 13: Post-operative x-ray showing correct placement of the implant and fit of the provisional restoration.

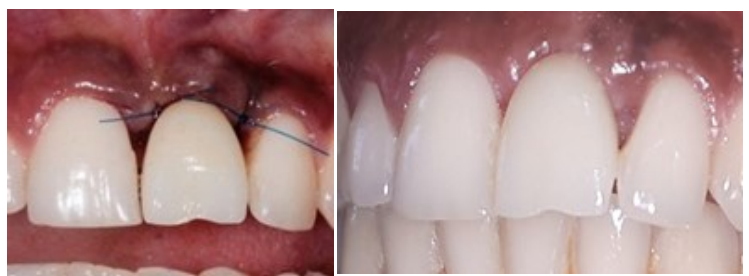

Figure 14: Immediate and one-week later outcome of the treatment.

An immediate loading of the provisional was performed. The full placement, the interproximal contacts, interdental spaces and the occlusion were verified. Palatal-wise, the crown was contact free.

Flap suturing was performed with the provisional restoration placed, as it will guide the soft tissue healing. A post-surgical peri-apical radiograph of the implant placement was taken immediately (fig.13). The post-operative instructions were explained to the patient as for the prescribed medication which included paracetamol (1000 mg), amoxicillin (1000 mg) twice a day for 5 days.

Discussion

Main challenges about a single anterior tooth implant replacement are the diagnosis and correction of hard and soft tissue defects, the accurate prosthetically driven implant placement, and consequently, teeth and gum aesthetics.

Conventionally, the implant placement was planned using radiographic guide, then a surgical guide was prepared traditionally on models, separately from CT data, and employed only as position indicator, providing surgical information only on placement position but not depth, which explained the unavoidable loss of accuracy and predictability of the implant placement. (1)(9)(10)(11)

In the present case, we proceeded to the 3D digital planification, of the implant position accordingly with the prosthetic needs as we intended to accomplish an immediate loading and respond to the patient's request. In addition, we considered it as a clinical situation that preferably required this technology because the missing tooth was single, in an esthetic zone, with a narrow bone deficiency.

The choice of computer-assisted implant placement over free-hand treatment protocol, using tooth-supported surgical guides, was justified, for it would lead to fulfill biological, functional and esthetic outcomes. In fact, template-based surgery has been compared in many studies to free-hand surgery for the treatment of single-tooth gaps: Single implants placed using computer-assisted, template-based surgery are associated with higher accuracy than single implants placed using conventional procedures. Accuracy improvement is obtained with the use of the template guidance in the final drilling and implant placement. (12)(13)

A systematic review from the 5th International Team for Implantology Consensus Conference (14) concluded that, compared with other types of guides, the bone-supported surgical guides showed the lowest accuracy. (15)

Using a software combining 3D CBCT data as DICOM file and STL extraoral model scan, allowed a detailed visualization of the clinical situation, Hence, a precise diagnosis, prosthetic outcome and eventual needed procedures were determined. In the present case, as the bone defects were previously corrected, no additional procedures were necessary. In addition, a planning report was provided, summarizing the type, size and position of the implant, and specifying the drilling protocol (according to the bone density), with technical information on the correct use of the instruments of the chosen surgical system, which is time and energy saving.

We were able to replace a 3,5 – 13mm implant virtually in a correct position, parallel to the adjacent teeth roots, at 2mm distance from the adjacent teeth, and the buccal and palatal crestal bone. This position was chosen according to the virtual wax-up (future restoration) and was placed 4mm below the gingival margin, in order to respond to the occlusal and esthetic requirements. An immediate loading of a screw-retained provisional restoration was allowed since the torque insertion was 35Ncm and the primary implant stability measurement indicated an ISQ of 75.

The provisional restoration is the key to obtain a natural and esthetic well-shaped peri-implant soft tissue. In addition, screw retained provisional restorations would eliminate the possibility of having any temporary cement present in the peri-implant tissue. (16)

For this purpose, we used the same virtual wax up, established during the planification, and fabricated a CAD/CAM (PMMA) provisional crown. The fit, form, and occlusion, were controlled before the final hand-tightened placement. A periodic monitoring is established in order to follow the shaping and maturation of the peri-implant tissue to yield an appropriate emergence profile for the final restoration.

Conclusion

In the presented case, 3D implant placement helped achieving the patient expectations about the whole procedure, and the rehabilitation outcome.

Within the limitation of a single case report, guided implant placement for single teeth may be considered as more accurate and reliable procedure as it offers predictable implant positioning, *a priori* digital simulation of the surgery, favorable clinical and esthetic outcomes especially for a single anterior tooth. However, high caution is needed in the selection of cases as well as a learning phase should be expected and duly observed by everyone operating or supervising the procedure.

References

1. Lau JA and D. Accuracy of static computer-assisted implant placement in anterior and posterior sites by clinicians new to implant dentistry: in vitro comparison of fully guided, pilot-guided, and freehand protocols | EndNote Click [Internet]. [cited 2021 Mar 29].
2. Belser UC, Mericske-Stern R, Bernard J-P, Taylor TD. Prosthetic management of the partially dentate patient with fixed implant restorations. Clin Oral Implants Res. 2000Sep;11:126–45.

3. Buser D. Optimizing Esthetics for Implant Restorations in the Anterior Maxilla: Anatomic and Surgical Considerations. :20.
4. Ramaglia L, Toti P, Sbordone C, Guidetti F, Martuscelli R, Sbordone L. Implant angulation: 2-year retrospective analysis on the influence of dental implant angle insertion on marginal bone resorption in maxillary and mandibular osseous onlay grafts. *Clin Oral Investig*. 2015 May;19(4):769–79.
5. Maharjan SK, Mathema SRB, Shrestha SM. 3D Guided Implant Surgery: A Case Report. *J Nepal Prosthodont Soc*. 2018 Dec 31;1(2):90–5.
6. Tahmaseb A, Wu V, Wismeijer D, Coucke W, Evans C. The accuracy of static computer-aided implant surgery: A systematic review and meta-analysis. *Clin Oral Implants Res*. 2018 Oct;29 Suppl 16:416–35.
7. Tabassum A. Guided implant surgery and immediate implant placement in esthetic zone. *Rodrigues Tonetto M, editor. Int J Med Dent Case Rep*. 2018;5(1):1–5.
8. Lin C-C, Wu C-Z, Huang M-S, Huang C-F, Cheng H-C, Wang DP. Fully Digital Workflow for Planning Static Guided Implant Surgery: A Prospective Accuracy Study. *J Clin Med*. 2020 Apr 1;9(4).
9. Zayed SM. Computer Guided Implant Surgery: Is It a Holistic Solution? 2019;12.
10. Faciomaxillary Surgeon and Implantologist, Academic and Research Scientist, Axiss Dental Pvt. Ltd., Bangalore, Karnataka, India, Gupta S. 3D Printing in Dental Implantology. *Dent - Open J*. 2017 Jun 9;4(1):e1–3.
11. Moon S-Y, Lee K-R, Kim S-G, Son M-K. Clinical problems of computer-guided implant surgery. *Maxillofac Plast Reconstr Surg*. 2016 Dec;38(1):15.
12. Tallarico M, Meloni SM, Canullo L, Xhanari E, Polizzi G. Guided surgery for single-implant placement: A critical review. :8.
13. Pozzi A, Polizzi G, Moy PK. Guided surgery with tooth-supported templates for single missing teeth: A critical review. *Eur J Oral Implant*. :19.
14. Tahmaseb A, Wismeijer D, Coucke W, Derksen W. Computer Technology Applications in Surgical Implant Dentistry: A Systematic Review. *Int J Oral Maxillofac Implants*. 2014 Jan;29(Supplement):25–42.
15. D'haese J, Ackhurst J, Wismeijer D, De Bruyn H, Tahmaseb A. Current state of the art of computer-guided implant surgery. *Periodontol 2000*. 2017 Feb;73(1):121–33.
16. Santosa R. Provisional restoration options in implant dentistry.

Citation: Assila L, Ismaili Z. “3D Guided Implant Placement for a Single Anterior Tooth: A Case Report”. *SVOA Dentistry* 2022, 3:4, 178-183.

Copyright: © 2022 All rights reserved by Assila L., et al. This is an open access article distributed under the Creative Commons Attribution License, which permits unrestricted use, distribution, and reproduction in any medium, provided the original work is properly cited.