

Fibrous Dysplasia: Clinicopathological Behavior and Its Management

Ajay Pillai¹, Neha Jain^{2*}, Ashutoshdutt Pathak³, Sabhrant Singh⁴, Honey Shukla⁵ and Nitin Kumar Mishra⁶

¹ Professor and Head, Department of Oral and Maxillofacial Surgery, People Dental Academy, Bhopal, India.

² Professor, Department of Oral and Maxillofacial Surgery, People College of Dental Sciences and Research Center, Bhopal, India.

³ Professor, Department of Oral and Maxillofacial Surgery, People College of dental Science and Research Center, Bhopal, India.

⁴ Reader, Department of Oral and Maxillofacial Surgery, People College of dental Science and Research Center, Bhopal, India.

⁵ Reader, Department of Oral and Maxillofacial Surgery, Modern Dental College and Research Center, Indore, India.

⁶ Post graduate Student, Department of Oral and Maxillofacial Surgery, People Dental Academy, Bhopal, India.

*Corresponding Author: Dr. Neha Jain, Room No 101, Dept of Oral & Maxillofacial Surgery, People's Dental Academy, Bhopal, India.

DOI: <https://doi.org/10.58624/SVOADE.2024.05.0185>

Received: July 19, 2024 Published: August 13, 2024

Abstract

Fibrous dysplasia (FD) is a rare disorder of bone in which normal bone is replaced by abnormal fibro-osseous tissue. It more commonly involves the long bones, craniofacial bones, ribs, and pelvis. The involvement of single bone is called as monostotic type of FD and if multiple bones are involved it is called polyostotic type of FD. Its occurrence is predominantly observed in teenagers, and it usually becomes static after adulthood. The incidence of monostotic FD (MFD) is four times more than that of polyostotic FD (PFD). The posterior region of the jaw bone is more prone and rarely crosses the midline. The malignant potential is 0.5% for cases that remain untreated. Here, we present a case of MFD involving the posterior region of the right side of the mandible in a 37-year-old female patient. The clinical diagnostic approach, different imaging modalities, and histological examination methods for definitive diagnosis have been elaborated. During the regular follow-up, the MFD lesion showed no obvious signs of progression or malignancy features.

Keywords: Fibrous dysplasia, Monostotic fibrous dysplasia, Osteoblast, Osteoclast, Woven bone

Introduction

Lichtenstein first coined the term "fibrous dysplasia" in 1938 [1]. FD results due to a disturbance in bone metabolism that is classified as benign fibro-osseous lesion. Abnormal bone containing fibrous connective tissue replaces normal bone [2]. FD occurs due to differences in rates of osteoblastic and osteoclastic activities [3]. Mutation in the guanine nucleotide-binding protein-coding gene in the early stages of life is considered to be the etiology of the disease. A cell population with this genetic disturbance, which is not capable of producing normal bone, instead generates a disorganized woven bone. The lesion has mainly two forms; monostotic form which is single bone involvement whereas polyostotic form is when multiple bone involvement occurs. In most of patients, the disease presents in early childhood, grows slowly and stabilizes in early adult life [4]. Patients may have symptoms like swelling, pain, or numbness on the affected site. MFD is likely to occur four times more than PFD [3].

Case Presentation

A 37-year-old female patient reported to the Outpatient Department of Oral and Maxillofacial Surgery with chief complaints of swelling and pain in the right lower third of her face since 2 years. The patient initially noticed a swelling on the lower right side of the mandible, which showed slow growth and progressive nature with no history of forerunning symptoms. Pain followed the swelling, which was gradual in onset, progressive, mild, intermittent, dull in nature, aggravated on chewing solid food, and relieved with medications. The patient consulted a private dental clinic for the swelling where root canal treatment was done with respect to 46. However, she did not experience any relief from pain and swelling. So, she got her tooth (46) extracted followed by extraction of 43, 44, and 45 on subsequent appointments after not getting any relief. Even then patient did not experience any relief so she visited our OPD. On examination, there was a diffuse swelling over the lower border of the mandible on the right side extending from 2cm away from the corner of the mouth till 2cm anterior to the angle of the mandible (figure1). Skin over swelling appeared normal in colour and texture. On palpation swelling was hard in consistency, non-tender, and immobile with signs of paraesthesia of the affected side, the temperature of the skin over swelling appeared normal. On intra-oral examination 43, 44, 45, and 46 were missing. No buccal and lingual cortical plate expansion (figure 2).

Following clinical examination, a CBCT was advised (figure 3). Radiograph revealed solitary, ill-defined, mixed radiolucent-radiopaque areas in the right mandibular region (43-46), extending mediolaterally from distal to 42 till mesial aspect of 47. Extends supero-inferiorly from the middle third of mandible, till the lower border of the mandible, mainly noted beneath IANC. Anterior one-third of the lesion is more radiolucent. The middle one-third of the lesion was mixed radiolucent-radiopaque and the posterior one-third of the lesion was more radiopaque, giving the lesion ground glass appearance. Evidence of expansion of buccal and lingual cortical plates was noted, along with expansion at the lower border of the mandible. An incisional biopsy procedure was performed on the affected side for confirmatory diagnosis. The histopathological report revealed irregular bony trabeculae lined by osteoblastic rimming surrounded by fibrous tissue suggestive of fibrous dysplasia (figure 4). None of the other bone involvement was found in the skeleton. Biochemical parameters including serum calcium, phosphorus, and alkaline phosphatase levels were normal. Under general analgesia, a wide osteoplasty (bone shaving) was performed, and the buccal and lingual cortical plates were reshaped (figure 5,6).

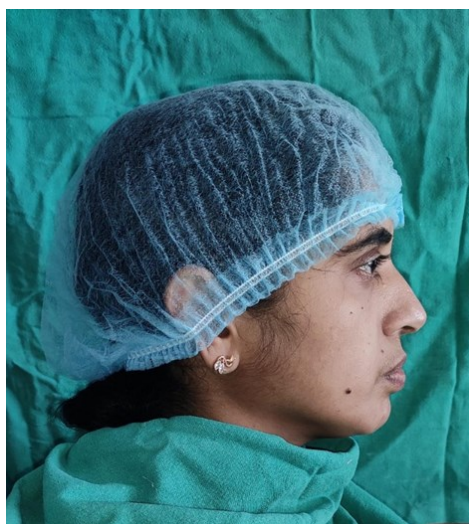

Figure 1. Right lateral profile of patient (preoperative).

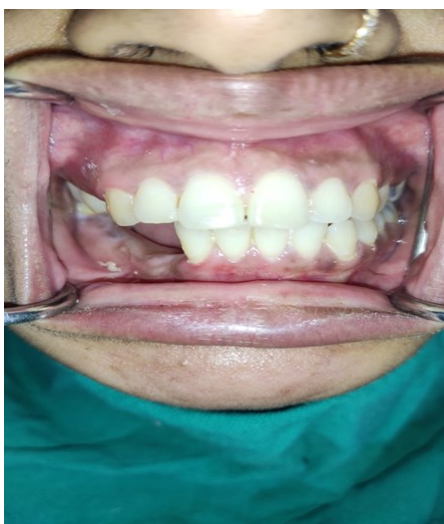

Figure 2. Intraoral view (preoperative).

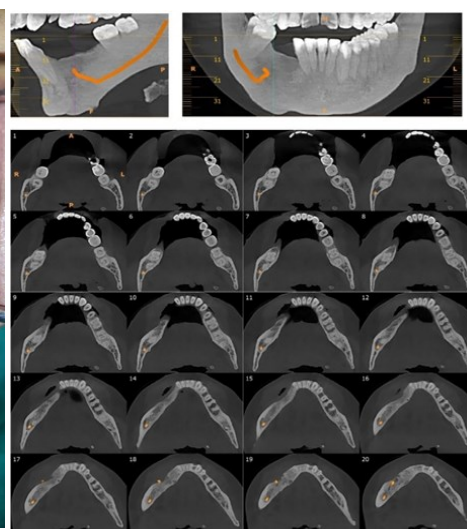


Figure 3. CBCT scan (axial view).

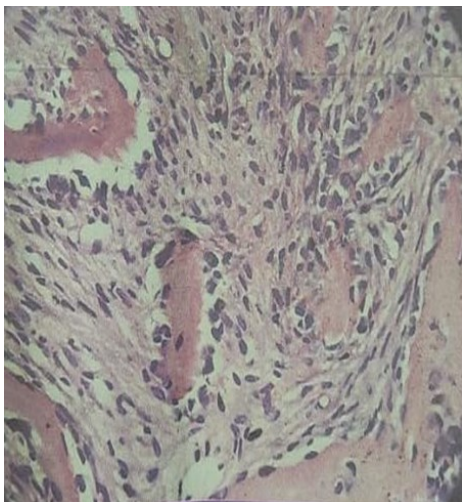


Figure 4. Microscopic view of histopathological section of the lesion.

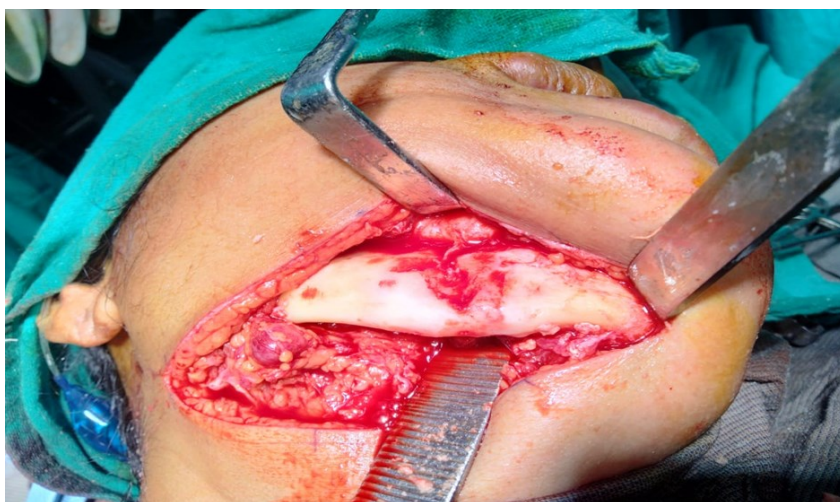


Figure 5. Intraoperative view of the lesion.

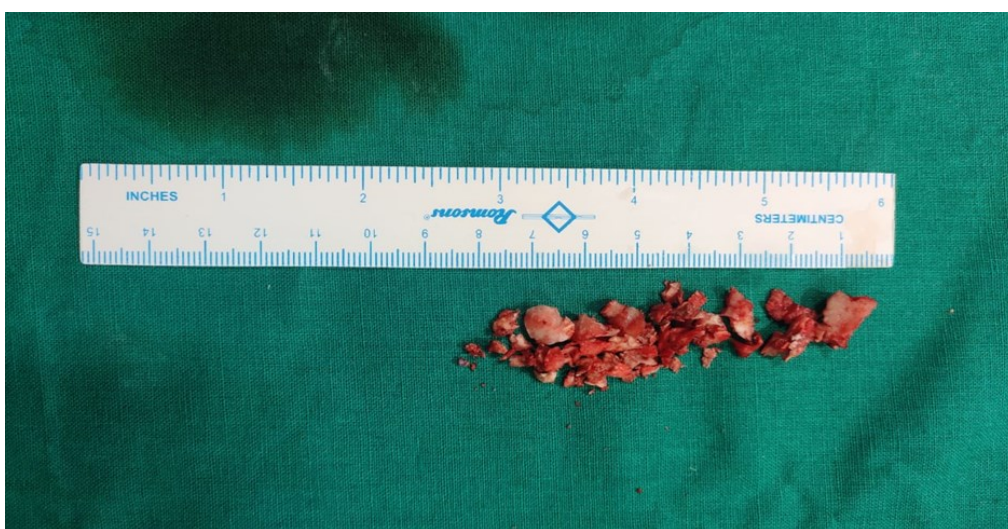


Figure 6. Bony lesion removed after performing osteoplasty.

Discussion

Fibrous dysplasia is a developmental disorder in which normal bone is replaced with fibrous connective tissue. As the lesion advances, the fibrous connective tissue is replaced with irregularly patterned trabecular bone. Fibrous dysplasia is a localized anomaly, which can involve one (monostotic) or multiple (polyostotic) bones. The monostotic form generally presents during the second decade of life and becomes inactive by the third decade. Hormonal changes, such as those seen in pregnancy, can reactivate a dormant lesion. When the anatomic spaces and foramina are compressed because of invasion of the lesions, the patient may experience a variety of symptoms, including headaches, blindness, proptosis, diplopia, deafness, anosmia, nasal obstruction, epistaxis, epiphora and symptoms mimicking sinusitis. The incidence of FD is twice more common in the maxilla than in the mandible, and the posterior mandible is more frequently affected than the anterior. Recent researches have shown a slight female prevalence [2]. There is no single definite etiology of FD, but it is believed to arise from abnormal activity in the bone-forming mesenchymal tissue. Trauma was also believed as a causative factor but the disease in some cases has been reported at the time of birth [4]. The current gold standard for the diagnosis of FD is a histologically-proven fibro-osseous lesion with poorly defined margins which are confirmed by radiographic findings [1]. Differential diagnosis of FD is based on clinical, radiographic, laboratory, and histological findings. Pathological conditions mimicking FD can be classified as other fibro-osseous lesions (cemento-osseous dysplasia, ossifying fibroma), bone cysts, cementoma, Paget's disease, Cherubism, hyperparathyroidism, chronic sclerosing osteomyelitis, and osteogenic sarcoma.

The lesion most frequently misdiagnosed as FD is Ossifying Fibroma (OF). OF shows a well-defined border whereas FD is expansive and diffuse with a poorly defined margin [4]. Treatment usually involves bony recontouring at the affected site to improve aesthetics and function [2]. Medical treatment with bisphosphonates may have benefits including improvement of function, pain relief, and lower fracture risk in appropriately selected FD patients. Conservative treatment has been the standard of care, which involves removing the diseased bone via an intraoral approach. Cortical bone grafts are better than cancellous bone grafts or bone-graft alternatives because of the outstanding quality of the remodeled cortical bone [1]. Recurrence is rare in adults, but the lesions can show surprising growth potential if they are surgically altered during their active growth phase [2]. Malignant transformation rarely occurs but it may transform into sarcomas. Radiation therapy is associated with the malignant transformation of FD, therefore it is not included in their treatment options [4]. Increased blood alkaline phosphatase levels are a warning sign for the malignant transformation of FD. Therefore, its levels should be periodically monitored in such patients [3]. Therefore, adequate knowledge of FD is essential to make an appropriate diagnosis and restrict the complications of the disease. With improvements in medicine and molecular technology, better therapy for FD, such as gene therapy, may be possible in the near future [1].

Conclusion

In conclusion, this case report highlights the successful management of FD in a 37-year-old female patient through surgical intervention. Each case is different with peculiar symptoms and unique clinical findings. Therefore, the treatment approach for this condition must be apposite to the site of involvement.

Conflicts of Interest

The authors declare that they have no conflict of interests.

References

1. Yang HY, Su BC, Hwang MJ, Lee YP. Fibrous dysplasia of the anterior mandible: A rare case report. *Tzu-Chi Medical Journal*. 2018 Jul;30(3):185.
2. Singer SR, Mupparapu M, Rinaggio J. Clinical and radiographic features of chronic monostotic fibrous dysplasia of the mandible. *Journal-Canadian Dental Association*. 2004 Sep 1;70:548-52.
3. Assiri KI. Monostotic fibrous dysplasia involving the mandible: a case report. *SAGE Open Medical Case Reports*. 2020 Sep;8:2050313X20936954.
4. Delilbaşı Ç, Deniz E, Doğan Ekici I. Monostotic fibrous dysplasia of the mandible. *Oral Health and Dental Management*. 2014.

Citation: Pillai A, Jain N, Pathak A, Singh S, Shukla H, Mishra NK. Fibrous Dysplasia: Clinicopathological Behavior and Its Management. *SVOA Dentistry* 2024, 5:4, 154-157. doi:10.58624/SVOADE.2024.05.0185

Copyright: © 2024 All rights reserved by Jain N., et al. This is an open access article distributed under the Creative Commons Attribution License, which permits unrestricted use, distribution, and reproduction in any medium, provided the original work is properly cited.