

The First Ever Described Transhepatic Gallbladder

Kristen Bridges MD¹, Pratibha Vemulapalli MD¹, Kieran O'Driscoll BSc¹, Jamie Han DO¹,
Jaime Sexton MSc¹ and Brian Gilchrist MD^{1*}

¹ The Brooklyn Hospital Center, New York, USA.

*Corresponding Author: Brian Gilchrist MD, The Brooklyn Hospital Center, New York, USA.

DOI: <https://doi.org/10.58624/SVOAMR.2023.01.003>

Received: June 21, 2023 Published: August 03, 2023

Abstract

A transhepatic gallbladder is an exceedingly rare finding that presents unique challenges for the general surgeon who often encounters it unexpectedly. A sonogram will not demonstrate it. A gallbladder that wholly penetrates the right lobe of the liver and is clearly visible on the anterior surface is an enigma. We describe an incidental finding at the time of elective surgery of such a phenomenon. This presented the author with a unique problem - how to remove the entire gallbladder without leaving a hole in the right lobe of the liver through which bowel could herniate. A novel technique was utilized which left a small bridge of cauterized gallbladder fundus wall. This article delves into the embryology of the hepatobiliary system in order to surmise how this could have occurred during development. This transhepatic gallbladder also contained a septum, dividing the gallbladder transversely into unequal parts. We hope that our findings and operative description will assist future surgeons that encounter a similar anatomic problem.

Keywords: transhepatic gallbladder, anomalous gallbladder, septate gallbladder, hepatobiliary embryology.

Introduction

Laparoscopic cholecystectomy is one of the most commonly performed surgical procedures in the world.¹ Complications from this surgery may occur due to embryological anomalies of the gallbladder. These anomalies have a rare occurrence of 0.1% to 0.7%.² They are discovered intraoperatively in the majority of cases, thus causing perioperative challenges. The most common anomalous locations of ectopic gallbladders are beneath the left hepatic lobe, intrahepatic, transverse, and retrohepatic/retroperitoneal.³ Other cases of "floating" ectopic gallbladders have been reported in the lesser omentum, the retroduodenal area, falciform ligament and within the abdominal wall.^{4,5} Ectopic gallbladders are clinically significant due to their tendency to cause stasis within the gallbladder and ultimately cholelithiasis. In this report, we present the first in the literature ectopic transhepatic gallbladder that additionally contained a septum. This paper aims to detail and discuss transhepatic gallbladders with reference to their pathogenesis, surgical approach, and clinical relevance.

Case Presentation

A 52-year-old woman with no significant past medical history reported chronic right upper quadrant pain. Ultrasound evaluation revealed a marginally thickened gallbladder containing two large stones. There was no sonographic evidence of an ectopic gallbladder or presence of a transverse septum.

Embryology

The gallbladder is derived from the hepatic diverticulum, which appears in the ventral wall of the primitive midgut after 4 weeks of gestation.⁶ The hepatic diverticulum is a product of endodermic proliferation from the gut tube and leads to the development of the liver, extrahepatic biliary ducts, gallbladder, and ventral pancreas. During the 4th week, two buds can be recognized in the hepatic diverticulum.

The cranial bud develops into the liver and the extrahepatic biliary tree. The superior aspect of the caudal bud develops into the gallbladder and the cystic duct. At the end of the 5th week, the entire biliary tree is recognizable.⁶ Significantly, the gallbladder is seen to develop intrahepatically in utero until the 18th week.⁷ This is demonstrated in a study conducted in 2012.⁷ After the 21st week of gestation, the gallbladder is seen to be located in the normal subhepatic position. The ectopic position of the gallbladder in our case was therefore retained by the liver parenchyma and thus this resulted in its transhepatic position.

Another embryological defect seen in this patient was a transverse septum seen in the gallbladder. The septum resulted in two non-communicating cavities (Figure 1). Septate gallbladders are rare anomalies.⁸ They are usually asymptomatic and thus most often found incidentally post mortem; however, there have been case reports of symptomatic patients with septate gallbladders, even in the absence of stones.^{8,9} A significant differentiation between septate gallbladders and bilobed gallbladder should be made since they are similar macroscopically. When the septum dividing the gallbladder lies longitudinally it is called bilobed gallbladder and when there is a transverse septum separating the fundus from the rest of the gallbladder it is called an hour-glass gallbladder¹³. The embryological processes involved in septate gallbladders are related to the multiseptate gallbladders (MSG). MSGs are very rare with one systematic review showing around 150 cases of multiseptated gallbladders (MSG).¹⁰ MSGs were first described in 1952 and since then a series of hypotheses have been represented to the literature. The embryological hypothesis was detailed in 1970 and it put forward the theory that MSGs are a result of the failure of disappearance of septations which occur in the later stages of embryological development.¹¹ They hypothesize that intraepithelial clefts fuse to form locules, which ultimately create spaces surrounded by septations when they expand. Support of this theory is regarded due to the fact that histopathology report shows smooth muscle in the septations of the gallbladder wall muscles.¹¹

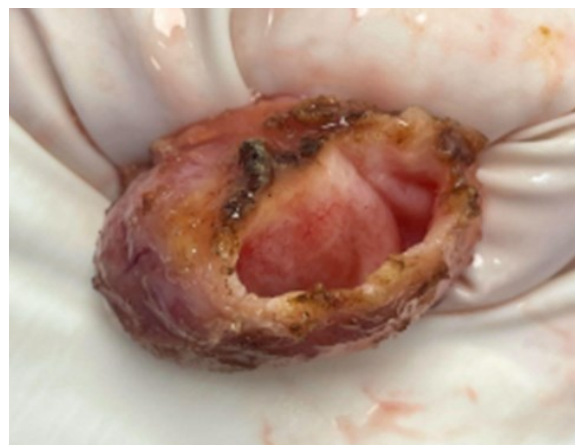


Figure 1: This is looking into the small separate lumen at the top of the fundus. It is open by virtue of the fact that the missing piece was left attached to the liver to avoid leaving a hole in the right lobe of the liver. The stones were in the larger of the two cavities. There was a thick septum dividing the two cavities and the larger cavity had to be opened to extract the stones (fig 4).

Ectopic Gallbladder

As discussed, ectopic gallbladders have been reported in the literature in many locations.^{2,3,4,5} This case shows a gallbladder located in a completely transhepatic position in the right lobe of the liver. This has not been previously described. Intrahepatic gallbladders are regarded as the second most common ectopic location however, here the gallbladder differed from intrahepatic gallbladders due to its complete penetration through the whole liver parenchyma. In regard to our patient's pathophysiological processes, the patient's gallbladder had significant risk factors for bile stasis and ultimately cholelithiasis. Another factor contributing to stasis within the gallbladder is a septate gallbladder. Our gallbladder was theoretically limited in its function due to the transverse septum.⁸ Therefore the combination of anomalies in our patient likely predisposed her to a higher risk of developing gallstones.

Surgical approach

This was done in laparoscopic fashion. The gallbladder was located in a transhepatic location in the right lobe of the liver. The inferior $\frac{1}{4}$ of the fundus was noted to be protruding from the anterior surface of the right lobe of the liver by 1mm and the superior portion was seen to be contained within a richly vascularized membranous sheath that was integrated within the liver parenchyma. We were able to easily visualize the gallbladder through the dome of the liver (Figure 2). As dissection was extended up to the level where the gallbladder travelled through the liver, we left a small piece of fundus bridging the defect in the liver, the mucosa of which was cauterized. If the gallbladder had been removed in its entirety, the patient could have potentially been at risk for intraoperative bleeding or late complications such as internal herniation. The patient was discharged on POD #0 and has done well postoperatively. The surgical pathology revealed chronic cholecystitis and cholelithiasis.

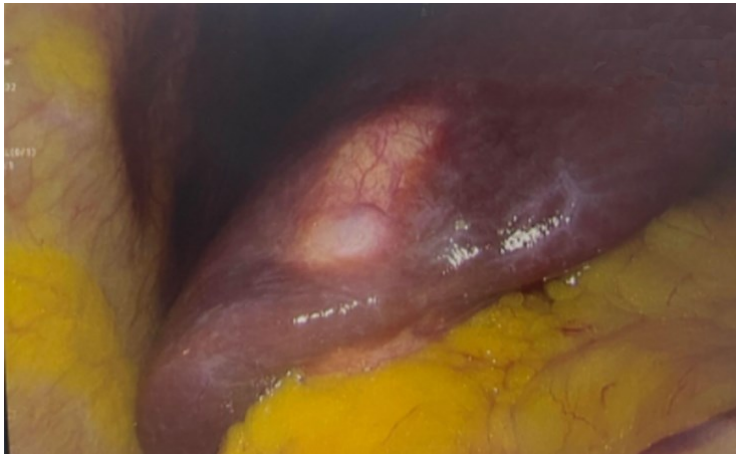

Figure 2: The gallbladder rising through the liver like an alligator cresting the water.

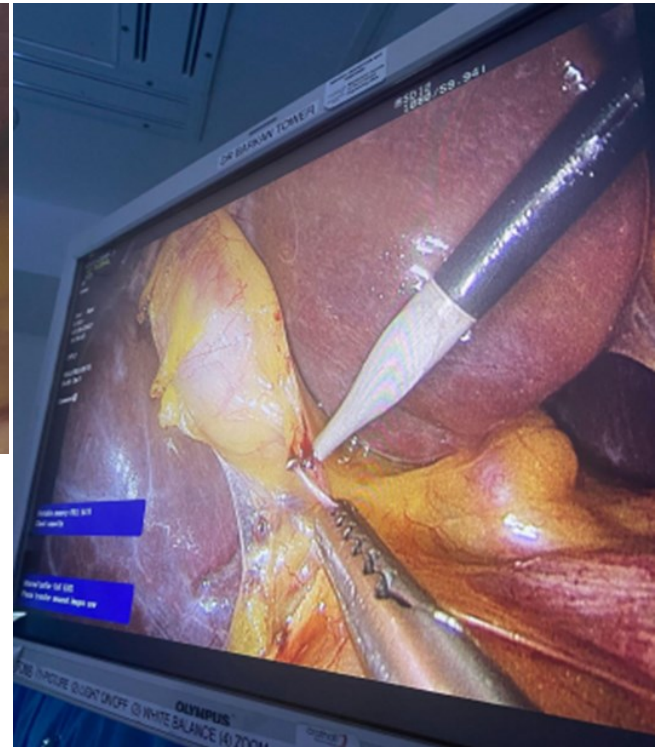


Figure 3: Laparoscopic dissection was performed in standard fashion. This is the opening of the peritoneum overlying the cystic duct using hook electrocautery. This part of the anatomy was not anomalous.

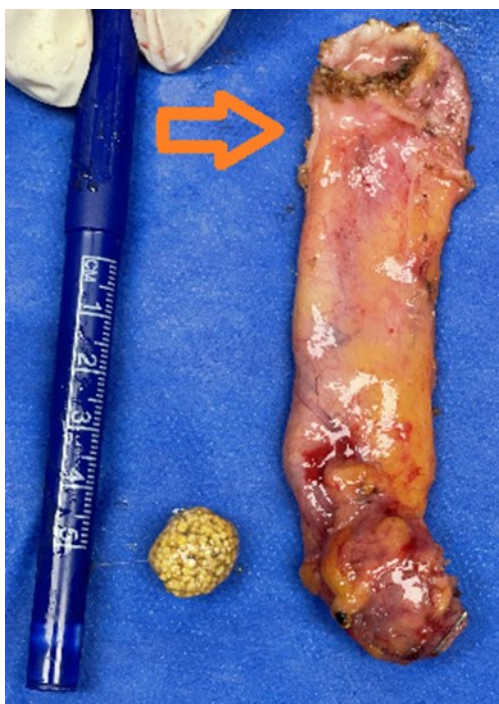


Figure 4: There was a second stone of similar size impacted in the neck of the gallbladder. The visible stone was extracted through a hole (arrow) made in the larger of the two lumens.

Discussion

Ectopic gallbladders are of an important clinical significance given the incidence of cholecystectomies performed throughout the world. They predispose patients to biliary complications and ultimately may result in technical problems during surgery. Previous case reports have reported ectopic gallbladders, however, after reviewing the literature, there are no ectopic gallbladders that have been described as being wholly transhepatic. The cystic artery and the cystic duct were noted not to be anomalous in this case, however, the remaining venous drainage from the gallbladder was shown to be integrated within the liver. We made a decision to leave behind a small piece of the gallbladder fundus due to its intimate relationship with the liver and the high risk of bleeding after dissecting it from the liver. Additionally, creating a hole in the right lobe of the liver may have put this patient at risk for an internal hernia. In figure 1, the gallbladder is seen after it was removed. The transverse septum can clearly be seen through the opening at the top of the fundus. In this case and others regarding ectopic gallbladder, the surgical approach to visualize the critical view of safety is imperative and challenging.¹² This case report describes the surgical approach when an ectopic gallbladder is found incidentally during an elective laparoscopic procedure and therefore it is clinically relevant and applicable to intraoperative management of ectopic gallbladders.

Conclusion

This report represents a first ever described wholly transhepatic gallbladder which was discovered intraoperatively and successfully managed laparoscopically. The transverse septum noted within the gallbladder in this case report also represents a rare anomaly which may have led to increased stasis of bile flow.⁸ This patient had a higher degree of risk of developing cholelithiasis due to the transhepatic location of the gallbladder, which increases the risk of bile stasis. The surgical approach in this case report can be referenced in the management of future ectopic gallbladders.

Conflict of Interest

The authors declare no conflict of interest.

References

1. Gupta V, Jain G. Safe laparoscopic cholecystectomy: Adoption of universal culture of safety in cholecystectomy. *World Journal of Gastrointestinal Surgery*. 2019;11(2):62-84.
2. Guerin J, Venkatesh S, Roberts L. Ectopic Gallbladder. *Clinical Gastroenterology and Hepatology*. 2015;13(7): e69.
3. Rafailidis V, Varelas S, Kotsidis N, Rafailidis D. Two Congenital Anomalies in One: An Ectopic Gallbladder with Phrygian Cap Deformity. *Case Reports in Radiology*. 2014; 2014:1-4.
4. Popli M, Popli V, Solanki Y. Ectopic gallbladder: A rare case. *Saudi Journal of Gastroenterology*. 2010;16(1):50.
5. BLANTON D, BREAM C, MANDEL S. Gallbladder ectopia. *American Journal of Roentgenology*. 1974;121(2):396-400.
6. Ando H. Embryology of the Biliary Tract. *Digestive Surgery*. 2010;27(2):87-89.
7. Wang B, Kim J, Yu H, Rodríguez-Vázquez J, Murakami G, Cho B. Fetal intrahepatic gallbladder and topographical anatomy of the liver hilar region and hepatocystic triangle. *Clinical Anatomy*. 2011;25(5):619-627.
8. Debaibi M, Sghair A, Sridi A, Chouchen A. Septate gallbladder: A rare congenital anomaly. *Clinical Case Reports*. 2022;10(4).
9. Patel N, Joshipura V, Haribhakti S, Soni H. Septate gallbladder in the laparoscopic era. *Journal of Minimal Access Surgery*. 2008;4(1):20.
10. Terkawi R, Qutob D, Hendaus M. Understanding multiseptated gallbladder: A systematic analysis with a case report. *JGH Open*. 2021;5(9):988-996.
11. Bhagavan BS, Amin PB, Land AS, Weinberg T. Multiseptate gallbladder. Embryogenetic hypotheses. *Arch. Pathol*. 1970; 89: 382-5.

12. Strasberg S, Brunt M. Rationale and Use of the Critical View of Safety in Laparoscopic Cholecystectomy. *Journal of the American College of Surgeons*. 2010;211(1):132-138.
13. Karaca T, Yoldas O, Bilgin BC, Bilgin S, Evcik E, Ozen S, "Diagnosis and Treatment of Multiseptate Gallbladder with Recurrent Abdominal Pain", *Case Reports in Medicine*, vol. 2011, Article ID 162853, 2 pages, 2011. <https://doi.org/10.1155/2011/162853>

Citation: Bridges K, Vemulapalli P, O'Driscoll K, Han J, Sexton J, Gilchrist B. The First Ever Described Transhepatic Gallbladder. *SVOA Medical Research* 2023, 1:1, 12-16.

Copyright: © 2023 All rights reserved by Gilchrist B., et al. This is an open access article distributed under the Creative Commons Attribution License, which permits unrestricted use, distribution, and reproduction in any medium, provided the original work is properly cited.