

A Rare Case of Human Urogenital Myiasis Caused by *Chironomus crassicaudatus* (Diptera: *Chironomidae*) from Kolkata, India

Kokila Banerjee, MD^{1*}, Arindam Dutta, MS, MCh² and Subhendu Roy, MD¹

¹ Drs. Tribedi and Roy Diagnostic Laboratory, Kolkata, India.

² RG Stone Urology and Laparoscopy Hospital, Kolkata, India.

*Corresponding Author: Dr. Kokila Banerjee, Drs. Tribedi and Roy Diagnostic Laboratory, Kolkata, India.

DOI: <https://doi.org/10.58624/SVOAMB.2024.05.040>

Received: May 17, 2024 Published: June 11, 2024

Abstract

Infestation by the Dipteran insect larvae is one of the public health problems in tropical countries, including India. Calliphorid flies are reported to cause various types of myiasis, including urogenital myiasis. Besides, non-myiasis-producing flies also occasionally invade human or animal tissues and cause myiasis. For the first time, we report here, an uncommon type of myiasis of the urogenital system due to an infestation by *Chironomus* larvae. A 19-year-old female patient from a poor socio-economic background from Kolkata, India attended the outpatient department with a complaint of passing worms in her urine with one-to-five larvae, several times a day, for four weeks. Another member of the family had a similar complaint. The larvae isolated from the patient were identified to be *Chironomus crassicaudatus* (Diptera: *Chironomidae*). It was probable that *Chironomid* flies breeding in and around the dwellings had infested the urethra. The patient was successfully treated with albendazole. Implementing overall environmental and personal hygienic living conditions, eliminating fly breeding habitats, and avoiding sharing of a common toilet facility are important measures to avoid such kind of fly infestation.

Keywords: Urogenital myiasis; *Chironomus crassicaudatus*; Larvae; Infestation.

Introduction

Myiasis is a condition where dipterous fly larvae infest the body of both human and other vertebrates. While growing, the larvae feed on living, dead, or necrotic host tissues.¹ Clinically, this syndrome is categorized into the following types: dermal, nasal, oral, aural, intestinal, rectal, and urogenital myiasis, depending on the site of infestation.¹ Based on the mode of egg-laying behavior of the adult female flies, the syndrome is classified into obligatory, accidental, or facultative myiasis.² In obligatory myiasis, adult female flies are attracted to open wounds or natural openings having putrefying discharge or odor. The flies deposit eggs, which upon hatching; the larvae migrate interiorly and consume necrotic or healthy tissues. Ultimately, the eggs drop to the ground along with feces or urine during pupation.³ In accidental myiasis, certain flies, whose larvae are free-living, accidentally deposit eggs on food. When such infested food is improperly cooked and consumed, the larvae get access to the intestine and cause intestinal myiasis.⁴ In facultative myiasis, adult flies invade diseased human or animal tissues.³

The larvae of certain dipteran flies are free-living. When their population density becomes high or breeding habitat gets scarce, they invade wounds and natural openings of human or animal hosts having a putrefying odor, often because of bacterial infection.⁵ The eggs then gain access to wounds or natural openings. The larvae after hatching continue their life cycle on the living host; a condition known as pseudo myiasis. The severity of infestation in the vertebrate hosts depends on the parasite species.⁶ Identification of the species of larvae that cause myiasis is essential. There are several reports of different types of myiasis caused by *Calliphorid*, *Sarcophagid*, and *Gastrophilid* flies. However, for the first time, we present a case of urogenital myiasis, incidentally caused by larvae of the *Chironomus* fly.

Case Report

A 19-year-old female patient from Kolkata, India presented with a history of passing one-to-five worms multiple times a day in her urine for the preceding four weeks. She belonged to low socioeconomic status and was dwelling in an unhygienic slum having a sharing community toilet facility. She had no history of abdominal pain, vomiting, fever, loss of appetite, abnormal bowel habits, or weight loss. She also had no complaint of genital itching, irritation, pain, or abnormal frequency of micturition. Interestingly, another lady in her family had a similar medical history.

On examination, no gross abnormality was detected in the body or the external genitalia. The personal hygiene of the patient was very poor. Ultrasound examination of the kidneys and urinary bladder revealed no abnormalities. However, a routine urine microscopic examination revealed the presence of some larvae. The larvae were isolated, washed with 0.9% normal saline, preserved in 70% alcohol, and sent for further examination. The larvae were transferred into a test tube containing 2 ml of 10% sodium hydroxide solution and heated till bubbles appeared and fatty tissues were dissolved. The larvae were then isolated, transferred onto a clean microscopic slide, mounted using Hoyer's fluid, and examined using a compound microscope (Zeiss, German). The larvae were identified to be those of *Chironomus crassicaudatus* (Diptera: Chironomidae).⁷⁻⁹

The presence of frontoclypeal apotome and medial labral sclerite anterior to the apotome, as well as the broad multi-toothed comb-like structure of the pecten epipharyngis further indicated the unique features of *Chironomus*. Besides, the pre-mandibles with a bifid nature and a pair of ventral tubules on the eleventh body segment also confirmed the generic characteristics of *Chironomus*. The mentum in the mouthpart was found with a trifid median tooth and six lateral teeth on either side. The mandibles had three inner teeth, of which the first two were darker and larger than the third one. The anteromedial margin of the ventromental plate had fine teeth. The inner apex of the ventromental plate was caudated i.e., slightly curved towards the apex. In addition to the ventromental plate, the pecten epipharyngis was provided with both larger and smaller teeth (Figure 1). The patient was, thus, diagnosed with urogenital myiasis. Tablet albendazole was administered (400 mg once a week for 4 weeks) and she was completely cured.

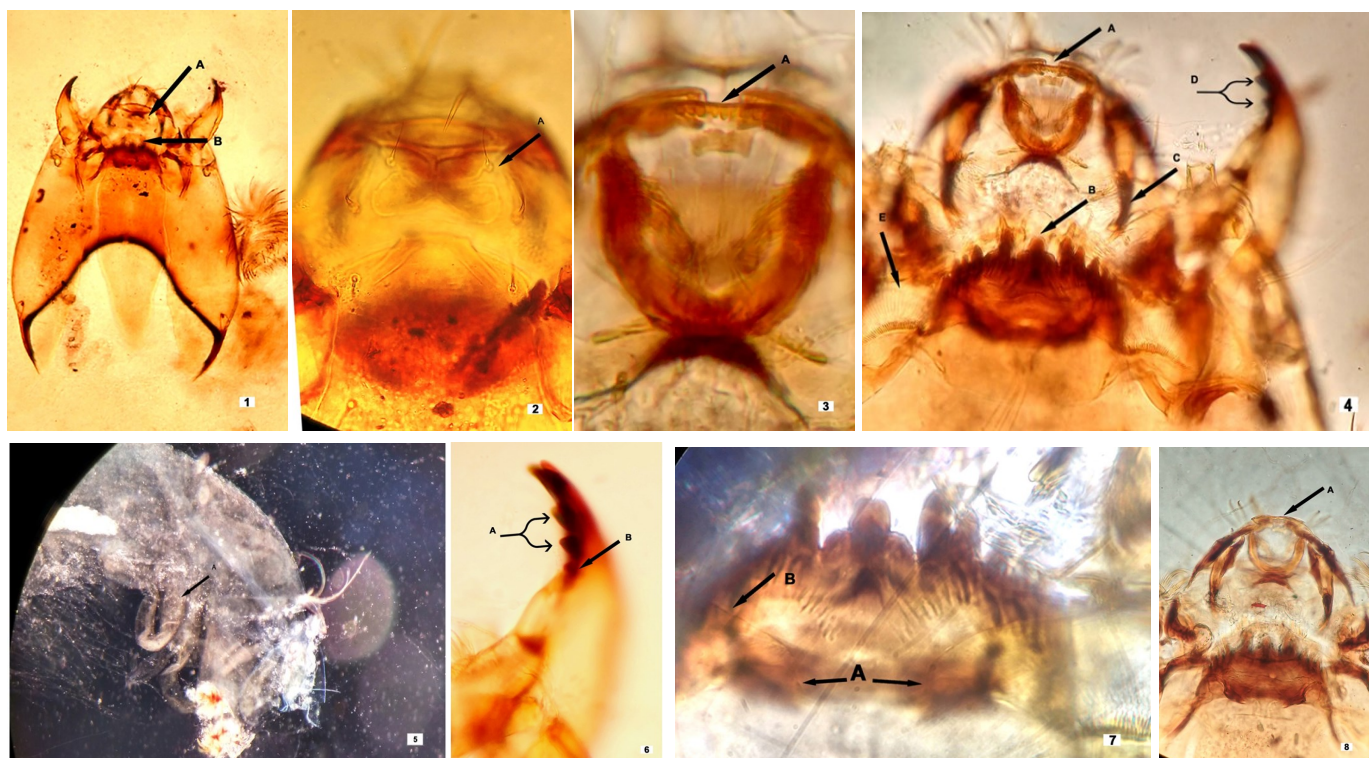


Fig. 1 A. Frontoclypeal apotome, B. Medial labral sclerite; **Fig. 2** A. Labral sclerite; **Fig. 3** A. Pecten epipharyngis with multi-toothed comb; **Fig. 4** A. Pecten epipharyngis with multi-toothed comb, B. Mentum, C. Premandible, D. Mandible with two dark inner teeth, E. Ventromental Plate; **Fig. 5** A. Paired ventral tubules; **Fig. 6** A. Mandible with two dark inner teeth, B. Mandible with a pale inner tooth; **Fig. 7** A. Inner apex of ventromental plate directed caudad, B. Anteromedial margin of ventromental plate with fine teeth; **Fig. 8** A. Pecten epipharyngis with numerous smaller teeth and larger teeth.

Discussion

To the best of our knowledge, this is the first case of urogenital myiasis caused by the larvae of *Chironomus crassicaudatus*. The flies of the species *Chironomids* and *Psychodids* co-exist with human and breed on soiled moist surfaces and low-lying water bodies. They also oviposit on soiled toilets and the free-living larvae feed on organic debris. Although several species of flies of the genera *Musca*, *Sarcophaga*, *Lucilia*, *Wohlfahrtia*, and *Calliphora* cause urinary myiasis, *Fannia scalaris* (Diptera: Fanniidae) larva is the most common. Uncommon urogenital myiasis caused by insects other than the actual myiasis-producing flies, such as the larvae of *Psychoda albipennis* (Diptera: Psychodidae),¹⁰ *Clogmia albipunctata* (Diptera: Psychodidae),¹¹ and *Megaselia scalaris* (Diptera: Phoridae)¹² has been reported in the literature. Antiparasitic agents (albendazole, mebendazole, or tiabendazole) are usually effective for the treatment of these patients¹³ like in our case.

Members of the *Chironomidae* family of flies are known as non-biting midges and resemble mosquitoes. They have a wide distribution, representing both terrestrial and aquatic environments, and can thrive in a wide range of environmental conditions, oxygen concentration, and vegetations. Although *Chironomids* family of flies have a vast distribution, information on its taxonomy is meager because they are difficult to identify. The female flies breed in almost all aquatic or semi-aquatic habitats and feed on sugar-rich food, including nectar and pollen.¹⁴ The larvae of most of the species practice anhydrobiosis, a condition wherein organisms are adapted to survive in a dry state.¹⁵ Due to this ability, the larvae that emerge from the eggs in the urethra continue their life cycle further by feeding on the microbiota and other commensals that are found in the urethra.

Conclusion

Thus, to conclude, we present a rare case of human urogenital myiasis caused by *Chironomus crassicaudatus* (Diptera: *Chironomidae*) from Kolkata, India. Implementing overall environmental and personal hygienic living conditions, eliminating fly breeding habitats, and avoiding sharing of a common toilet facility are important measures to avoid such kind of fly infestation.

Conflicts of Interest

The authors have no relevant financial or non-financial interests to disclose.

Consent for Publication

Informed consent from the patient was obtained for publication of this case report.

Funding

No funding was received to assist with the preparation of this manuscript.

References

1. Zumpt F (1965) Text Book for Physicians, veterinarians and Zoologists. Butterworth and Co Ltd., London.
2. Spradbery JP (1991) A manual for the diagnosis of screwworm flies (CSIRO, Division of Entomology, Canberra, Australia).
3. Herms WB, James MT (1961) Myiasis, Medical Entomology. Macmillan Company, New York.
4. Udgaonkar US, Dharamsi R, Kulkarni SA, et al (2012) Intestinal myiasis. Indian J Med Microbiol, 30:332–337.
5. Sima R, Rouhullah D, Hassan NK, et al (2016) Uncommon human urinary tract myiasis due to *Psychoda* sp. larvae, Kashan, Iran: A case report. Iran J Parasitol 11:417–421.
6. Punhani N, Daniel J, Srinivasan R (2009) Oral myiasis - a case report with clinical, radiographic and entomological findings from Puducherry Union Territory, southern India. J Indian Academy Oral Medicine Radiol 21:187–189.
7. Mason WT Jr (1968) An introduction to the identification of Chironomid Larvae. Publication of Federal Water Pollution Control Administration, U.S. Dept. of the Interior, Cincinnati.
8. Stewart PL, Loch JS (1972) A Guide for the Identification of Two Subfamilies of larval Chironomidae: The Chironominae and Tanypodinae Found in Benthic Studies in the Winnipeg River in the Vicinity of Pine Falls, Manitoba in 1971 and 1972. Technical Report Series No. CEN/T-73-12.

9. John HE (2001) Identification manual for the larval Chironomidae (Diptera) of North and South Carolina. North Carolina Department of Environment and Natural Resources Division of Water Quality.
10. Güven E, Kar S, Doğan N, et al (2008) Urogenital myiasis caused by *Psychoda albipennis* in a woman. *Turkiye Parazitol Derg* 32:174–176.
11. El-Badry AA, Salem HK, Edmardash YAE (2014) Human urinary myiasis due to larvae of *Clogmia* (*Telmatoscopus*) *albipunctata* Williston (Diptera: Psychodidae) first report in Egypt. *J Vector Borne Dis* 51:247–249.
12. Ghavami MB, Djalilvand A (2015) First Record of Urogenital Myiasis Induced by *Megaselia scalaris* (Diptera: Phoridae) from Iran. *J Arthropod Borne Dis* 9:274–280.
13. Francesconi F, Lupi O (2012) Myiasis. *Clin Microbiol Rev* 25:79–105.
14. Nagell B, Landahl CC (1978) Resistance to anoxia of *Chironomus plumosus* and *Chironomus anthracinus* (Diptera) larvae. *Ecography* 1:333–336.
15. Wharton DA (2015) Anhydrobiosis. *Current Biology*, 25:1114–1116.

Citation: Banerjee K, Dutta A, Roy S. A Rare Case of Human Urogenital Myiasis Caused by *Chironomus crassicaudatus* (Diptera: Chironomidae) from Kolkata, India. *SVOA Microbiology* 2024, 5:2, 30-33.

Copyright: © 2024 All rights reserved by Banerjee K., et al. This is an open access article distributed under the Creative Commons Attribution License, which permits unrestricted use, distribution, and reproduction in any medium, provided the original work is properly cited.