

Posterior Selective Callosotomy: A Case Series

Servin Moreno Oscar, MD^{*1,2}, Varela-Osorio, MD^{1,3}, Gomes Luiz Pedro, MD^{1,4}, Ordoñez Jorge, MD^{1,3}, Vieira Samuel, MD¹ and Silva Centeno Ricardo, PhD¹

¹Federal University of São Paulo, Paulista School of Medicine, Sao Paulo Hospital, Department of Functional Neurosurgery, Sao Paulo, Brazil

²Instituto de Previsión Social – Hospital Central, Neurosurgery Service, Asunción, Paraguay.

³Neurological Institute of the Pacific, Epilepsy Surgery Service, Cali, Colombia.

⁴Souza Aguiar Municipal Hospital, Neurosurgery Service, Rio de Janeiro, Brazil.

***Corresponding Author:** Dr. Servin Moreno Oscar, MD, Federal University of São Paulo, Paulista School of Medicine, Sao Paulo Hospital, Department of Functional Neurosurgery, Sao Paulo, Brazil.

Received: February 19, 2022 **Published:** February 28, 2022

Abstract

Refractory epilepsies are associated with sudden bilateral synchronization Ictal, which supports the justification for a callosotomy. The indication of posterior callosotomy was recommended in individuals with Lennox Gastaut syndrome and Drop-Attacks type crises. Used a technique of interhemispheric approach parieto-occipital, in Fowler position, with a minimum rupture of fibers. For the demonstration of the cases submitted to this technique, we seek to follow the following objectives: 1. Describe the history of the different Callosotomy techniques, 2. Describe the first four cases of callosotomy via the service, using case reports, which consisted of the description of 4 cases submitted to the surgical procedure. Compared to the pre-surgical state, case 1 decreased from 100 seizures/day to 6 crises/day for other crises and from 14 crises/day to 1 crisis/day for Drop-Attacks. Already in case 2 a reduction of 7 crises/day was obtained to 0.14 crisis/day, which gives us a value of 1 crisis per week for other crises and from 3 crisis/day to 0 crisis/day for Drop-Attacks, in case number 3 a decrease of 70 crises/day to 5 crises/day was observed for other crises and for Drop-Attacks type crises from 5 crisis/day to 0 crisis/day, in case 4 a reduction from 80 crises/day to 0.57 crises/day, which gives us a value of 4 crises per week and from 20 crises/day to 0 crises/day for Drop-Attacks type crises. Given the data exposed and the alteration of cognition we can say that in these cases a significant improvement in the quality of life of all patients was observed. This technique brings with it some advantages in relation to others used in the past, mainly related to the anatomy of the approach, the most favorable with respect to this is the interhemispheric fissure of the posterior region. The results are similar in seizure control and with potential advantage in cognitive preservation, although in our series we did not have an ideal sample for this last analysis, since all patients had a severe neuropsychomotor delay before surgery.

Keywords: Epilepsy, Posterior callosotomy, surgical technique.

Introduction

The corpus callosum (CC) is basically composed of white matter, with fibers oriented transversely. It has about 200 to 300 million axone and is located in the longitudinal fissure of the brain, acting mainly as an information bridge between the left and right hemispheres, through the extensive axon beams¹. It is anatomically divided into four parts: face (anterior portion); knee (also called anterior bulbar end); splenic (back) and the body, part located between the knee and the splenic¹.

The organization of the fibers is columnar, similar to that of the thalamus-cortical system². The initial pattern of development of sensitive fibers is diffuse. During their growth, they invade the contralateral cortex late, often after birth³.

According to Georgy⁴, fibers that originate in the inferior frontal lobe and the inferior parietal lobe and enter the knee of the Callous Body.

Only in the late 1920s, with the advent of the electroencephalogram (EEG), was it possible to determine areas containing epileptogenic tissue more accurately. Therefore, the diagnosis of epilepsy became more accurate, allowing the prior determination of the area to be resected⁵.

Van Wagenen (1897–1961) was a native of North York and attended Cornell University. After a brief stint in the military, he enrolled at Harvard Medical School and graduated in 1923. His internship was at Peter Bent Brigham Hospital, where he trained in general surgery and neurosurgery under Cushing. Callosotomy was first introduced by Van Wagenen in 1940 as a palliative treatment for uncontrollable seizures. Later, in the 1960s, Bogen differentiated two types of commissurotomies, complete and partial disconnection, as a treatment for resistant epilepsy¹⁸.

In the 1950s, surgical techniques related to the treatment of epilepsy gained greater prominence on the world stage. In Brazil, the neurosurgeon Paulo Niemeyer Soares stood out, who, inspired by the French epileptologist Henry Gastaut, idealized, and performed an amygdalo-hypocampectomy for transventricular access⁶, a pioneering technique in the surgical treatment of temporal epilepsies that quickly spread in large surgical centers.

According to Paglioli¹⁹, epileptic seizures per hour are generally refractory, and their association with sudden bilateral synchronization of ictal discharges justifies the indication of callosotomy. The procedure is indicated when focal resection is not feasible and specifically achieves sudden falls, regardless of the underlying etiology. He says selective posterior callosotomy is safe and effective in controlling fall attacks, with functional and behavioral gains in patients with intellectual disability.

In the nineteenth century, it was possible to develop modern neurosurgery due to the arrival of previously developed asepsis and anesthesia techniques, in addition to the improvement of knowledge related to the anatomy of the nervous system. From nitric oxide, the use of ether, chloroform, cyclopropane was followed until, in 1956, halothanes began to be used, promoting great advances in anesthetic techniques⁷.

In the 1970s and 1980s, new imaging methods emerged, such as computed tomography (CT), MRI, and positron emission tomography (PET-scan). Therefore, the analysis of brain tissue in a non-invasive way became a reality, greatly helping professionals in determining the epileptogenic approach⁵.

With the technical-scientific evolution that occurred at the beginning of the XXI century, several studies have demonstrated the superiority of surgical treatment in patient's refractory to pharmacological treatment, thus indicating the conception that the best therapeutic option for this group of patients is, in fact, surgical⁵.

Epilepsy surgery is one of the oldest fields of neurosurgery. Three patients operated on by Horsley in 1890, a study that ushered in modern neurosurgery, had seizures. Surgical treatment presents important results and resolves seizures in up to 80% of cases. Surgery may be indicated for the treatment of some cases of epilepsy. In patients who have fall crises (those in which the patient struggles, has spasms), callosotomy can be an interesting resource⁸.

In 1967 Griffith initially suggested disconnecting the diseased brain without removing it through an anterior callosotomy associated with capsulotomy. Preservation of the back of the corpus callosum was intended to decrease the risk of visual sequences. If surgery were effective, it would prevent a more radical procedure. In case of failure, a better understanding of the spread of seizures could allow the use of stereotactic lesions on specific targets to complete the disconnect. However, Griffith did not even publish the use of his technique in humans⁹.

But recently, the Hospital das Clínicas of the Faculty of Medicine of the University of São Paulo (HC-FMUSP), Ávila et al. reported two cases of epilepsy, with hemispherical lesions, undergoing anterior callosotomy and substantial improvement of seizures. The results proposed the use of the callosotomy technique in dozens of patients. In an attempt to avoid hemispherectomy, callosotomy was also used in patients with frontal epilepsy, Sturge Weber syndrome and congenital hemiplegia¹⁰.

Currently, there are three surgical modalities to contain epileptic seizures: resective, disconnected and neuromodulator surgeries¹¹. Resectives include lesionectomy, temporary resections, multilobar resections, and hemispherectomies. Disconnectives include callosotomies, disconnectives, and multiple subpial transections.

Neuromodulators, in turn, consist of alternative methods, used when resective or disconnective methods do not generate results or are contraindicated. They consist of vague nerve stimulation (VNS) and deep brain stimulation (DBS).

In the context of the therapeutic diagnosis, the indication of subsequent callosotomy is suggested, since it proved to be an effective treatment in the control of fall attacks, since the overall decrease in the frequency of fall crises was 89.3% ($p < 0.001$).

Younger patients at the time of surgery and with a shorter duration of epilepsy were significantly more likely to achieve a more favorable outcome ($p < 0.001$).

Callosotomy is a palliative disconnection treatment indicated for patients with generalized epileptic seizures who have seizures with fall attacks and who are not candidates for resective surgery, secondary electroencephalogram (EEG) bisynchrony, regardless of the etiology of epilepsy¹².

Within this positive outlook, then, there is an intention to report cases that had indications of subsequent callosotomy. All the work developed by the specialty of neurosurgery seeks in the selective callosotomy posterior callus to control the seizures of sudden fall to the ground, preserving to the maximum the motor, reasoning, and language capacities of the patients.

In view of the objectives of the present study, a further explanation about the callosotomy process is valid. This procedure is used for patients who are refractory to drug treatment. Callosotomy, however, does not have a curative character, but rather a palliative one.

Basically, it reduces the interhemispheric spread of epileptic activity. After the procedure, there is a decrease in bilateral synchrony of cortical epileptiform activity that interrupts the generalization of secondary seizures^{10,20,21}.

Callosotomy has already been recommended in individuals with Lennox Gastaut syndrome, with cancer, atonic, myoclonic, atypical absence or generalized tonic-clonic seizures, but cases of fall attacks, produced by atonic or tonic crises, responded better to callosotomy^{13,14}.

Currently, its main indication is that patients with direct attack attacks (tonic and atonic), and the results observed in patients with other types of seizures were generally not satisfactory¹⁵.

An important fact to keep in mind in this type of procedure is venous air embolism, which can be a serious complication in neurosurgery. The semi-sitting or sitting position is the most important risk factor for your appearance. There are different diagnostic methods available, with the transesophageal echocardiogram being one of the most sensitive, but it requires adequate training of the anesthesiologist. Treatment aims to decrease airflow when the diagnosis and the implementation of appropriate resuscitation measures in case of embolism are confirmed^{18, 19}.

Case 1

Female patient, born in 2009. He entered neurology for seizures from the age of 9 months, in which he manifested spasms and cephalic flexion, vertical ocular version and loss of urine, but without fever, he began therapy with Oxcarbazepine and Clonazepam, he could not control the seizures.

At the age of 2 he was diagnosed with West Syndrome. At 6 years, taking into account the persistence of the convulsive pattern, the diagnostic hypothesis of Lennox-Gastaut Syndrome was reached.

He has used valproic acid, pyridoxine (100 mg, 1 cp./day, for one year), Vigabatrin and prednisolone (in 2014, for seven months, he does not remember the dose). She also underwent a ketogenic diet from October 2014 to February 2015, being suspended for intolerance to treatment (it is important to note that the patient did not enter ketosis).

As for the previous medical history: depression at 5 years, resolved. I had never had hospitalizations or surgeries. Regarding Family History: Healthy Father and Mother.

In 2011, he performed an MRI indicating hypersignal in the T2 IR and Flair weighted sequences in the parahippocampal gyrus on the right, with no signs of anomalous impregnation after infusion of the paramagnetic agent, which may be related to mesial sclerosis. In 2014, he underwent another MRI, which showed cerebral parenchyma with mild diffuse T2 hypersignal in the white matter, suggesting alterations resulting from epilepsy, and hypomyelination could not be excluded. There were no alterations that could be related to the etiology of epilepsy. In 2018, it performed external EEG that demonstrated a moderate to accentuated base activity disorganized and symmetrical for age, with stretches of multifocal epileptiform paroxysms predominating in the right middle and temporo-parietal temporal region during wakefulness, in addition to prolonged stretches of discharges under slow presentation of tip waves.

The mother reports that the patient evolved into daily seizures, 100 seizures per day, lasting less than 5 minutes. Sometimes seizures occur with falling forward or forward, sometimes with tonic seizures of all 4 limbs and sometimes with absence seizures, with no predominance of any specific pattern. In some crises, the post-ictal period can reach 24 hours.

Upon his admission to the Sao Paulo Hospital, his reference was aimed at investigating Posterior Circulation Syndrome and he was using 6 medications:

- Levetiracetam 100 mg/ml 7.5 ml 1-0-1 (41 mg/kg/day) ;);
- Cannabidiol hemp oil 17% 3ml 1-0-1;
- Nitrazepam 5 mg 0-0-3 (0.4 mg/kg/day);

- Melatonin 10 mg 0-0-1;
- Biperidenum 2mg 0-0-1;
- Ospolot® 50 mg 1-0-1 (2.7 mg/kg/day) started 3 weeks ago.

The medical approach consisted of the video-EEG request at UNIPETE (17/08/2018, 12 hours), the adjustment of the dose of Ospolot to 300 mg/day and Levetiracetam for 10 ml, 12/12 hours. In addition, a refund was agreed for 05/10/2018. The Video-EEG showed a disorganized but symmetrical activity, a very frequent epileptiform activity, being the morphology of the acute waves of progression in the anterior regions, both in sleep and wakefulness, being more pronounced during sleep. Monitoring showed a very frequent generalized rapid paroxysmal activity, predominant during sleep, which characterizes the pace of recruitment. Two patterns of epileptic seizures were then recorded: lateral atonic tonic and vibratory tonic.

With the diagnosis of refractory epilepsy established, it was decided to perform subsequent callosotomy. The surgery is performed on 18/06/2019, without complications. Epileptic drugs were maintained along with phenytoin. Dexamethasone was also introduced into post-surgical drug therapy. In addition, weaning from sedation after 12 hours postoperatively was recommended if clinical stability persisted.

Case 2

The 20-year-old male patient. On May 13, 2019, he was admitted to the hospital in Sao Paulo, in the Neurosurgery service. At that time, he had, daily, about 4 absence seizures, 1 to 3 tonic seizures and 2 to 3 atonic seizures. During the anamnesis, the mother reports that, at age 6, epileptic seizures of absence began, and episodes were rare. After about a year, he began to present bilateral tonic-clonic seizures. Evaluated by the neurology service, which opted for pharmacological treatment with phenobarbital. It continued with the worsening of seizures characterized by an increase in frequency, associated with cognitive impairment and loss of motor functions. He began to have atonic seizures daily, being diagnosed with Lennox-Gastaut.

In 2011, he performed an MRI indicating hypersignal in the T2 IR and Flair weighted sequences in the parahippocampal gyrus on the right, with no signs of anomalous impregnation after infusion of the paramagnetic agent, which may be related to mesial sclerosis. On March 11, 2019, MRI was performed where diffuse cortical atrophy is reported. On April 14, an Electroencephalogram was performed where the activity is disorganized and relatively symmetrical, also with epileptiform activity with generalized projection, activated during sleep, rapid paroxysmal activity that worsens to drowsiness and sleep.

In the neurological examination, blind, disoriented, without presenting cooperation and interaction with the examiner.

In the relationship of the first hospital consultation in Sao Paulo, he used the following drugs:

- Topiramate 100 mg 12/12h,
- Lamotrigine 100 mg 12/12h,
- Ytossuximide 375 mg 8/8h,
- Clonazepam 6.5 mg/day,
- Risperidone 0.5mg/early

Video-EEG findings that were made between March 26 and 27, 2019 were evidenced by interictal recording, disorganized and symmetrical baseline intensity; RP: 4-5 Hz, epileptiform activity with acute wave morphology, spicules and polyspicle waves, of generalized projection accentuated in previous regions, outbreaks of rapid paroxysmal activity of generalized projection, interictal recording, multiple crises of atypical absences, characterized by discharges of acute waves and slow wave at 2.5 per second and 1 asymmetric tonic crisis with clonic component in sleep. With indication of posterior callosotomy was performed without complications. In the postoperative follow-up, simple control cranial tomography was indicated. Maintain anticonvulsant drugs.

Infection of the operative wound is observed in control by office, on 06/24/19. He denies fever (mother), denies local trauma. Evaluated by a neurosurgery team, surgical toilette is indicated and Meropenem and Vancomycin are started on 24/06, secretion culture is isolated *Klebsiella pneumoniae* (multi S). After 7 days, medical discharge with good evolution is indicated.

Case 3

The 25-year-old male patient arrived at the hospital service accompanied by his sister, arrives at the consultation by the endocrinology service due to panhypopituitarism. The sister reports that the patient had no pubertal development, remaining with little body hair, absence of hair in the genital region and in a beard, penis, and testicles of pre-pubertal size.

In the last consultation, the increase of Clobazam and the elimination of Carbamazepine were requested. However, they reported that they continued with the crises and worsened their aggression without Carbamazepine, so they withdrew clobazam and returned to Carbamazepine. There is an increase in falls of 2-5 per day (atonic crisis?).

At the Hospital of São Paulo, in the Neurosurgery service, the patient is evaluated with the following diagnostic hypotheses: Lennox-Gastaut Syndrome, Ectopic Neurohypophysis, Panhypopituitarism, Epilepsy and Asthma. Reported history: Neonatal meningitis; 2 episodes of febrile seizures during the acute episode, thus remaining 2 years without seizures. He abandoned the follow-up. He showed clinical signs of hypogonadism.

He performed EEG (at age 6) with a report that presented very frequent paroxysmal discharges, sometimes practically continuous, by sharp and slow waves, tips and diffuse complexes of tip waves. He reports that he only had a partial improvement after the introduction of Clobazam, but the seizures returned, the atonic seizures, falling backwards and sometimes only falling head-on, sometimes with tonic posture of the upper extremities. Topiramate begins with improvement of partial seizures.

It was not possible to perform MRI on the patient. The patient presented worsening of the respiratory pattern, fever, productive cough during the hospitalization of the Video-EEG in the last week. Antibiotic therapy, corticosteroids and inhalation were introduced with significant improvement.

In the relationship of the first hospital consultation in Sao Paulo, he used the following drugs:

- Clobazam
- Topiramate
- Phenobarbital
- Carbamazepine
- Levothyroxine 150mcg day - start no day 22/08/19
- Prednisone 5mg day - probable corticotrophic deficit.

After surgery, it was indicated to maintain without sedation. Maintain anti-epileptic drugs. CT scan of the skull without contrast (12/09/2019): there are no significant changes without hydrocephalus. During outpatient follow-up, the family member stated that there was an improvement over other 5-crisis/day seizures and no relapse-type seizures.

Case 4

A female patient, born in 1994, the first seizure was at age 15 that worsened while the frequency and intensity evolve to generalized chronic tonic. Early anti-seizure medications from the beginning of the condition gradually increased.

The first crisis while asleep, when her mother noticed hypertonia of the limbs, without cyanosis or release of the sphincter, which lasted more than 30 minutes, was taken to the emergency room, where she was briefly hospitalized for investigation. He was discharged with phenobarbital, phenytoin, and carbamazepine.

Shortly after, it began to present new crises, with a gradual increase in frequency, characterized by behavioral stop, deviation of the gaze and cephalic to the left, mainly of short duration, with evolution to the bilateral chronic tonic. He had more than 10-20 a day, with frequent falls. It evolved about a year after the beginning of the crises, 80 per day. The last perceptual focal seizure with progression to Clonic Tonic 3 months before surgery. Parents report that seizures occur almost daily, are currently behaviorally stopped, short duration (10-20 seconds), evolving with the right upper limb with Clonia, followed by hypertonia and clonias of the lower extremities (in the form of scissors), which last 1-2 minutes. You have already had episodes of status epilepticus, and the last time was less than 1 year before surgery. Mother reports that often the daughter has a crisis with behavioral alteration, turning the body to the left and assuming the hypertonic posture, lasting less than 1 minute.

Video-EEG is performed that concludes asymmetric and disorganized brain electrical activity, with predominance on the left; epileptiform discharges of acute projection waves in the posterior regions of the left hemisphere in continuous incidence; record of numerous negative focal motor crises in wakefulness, with signals located in the posterior regions to the left; record of a clonic seizure during sleep, of ictal onset in the frontal-central region on the left.

MRI was performed with diffuse accentuation of cortical grooves, with a slight predominance in the left hemisphere suggesting cortical atrophy.

A patient with a significant neuropsychological impairment, in treatment with 4 medications:

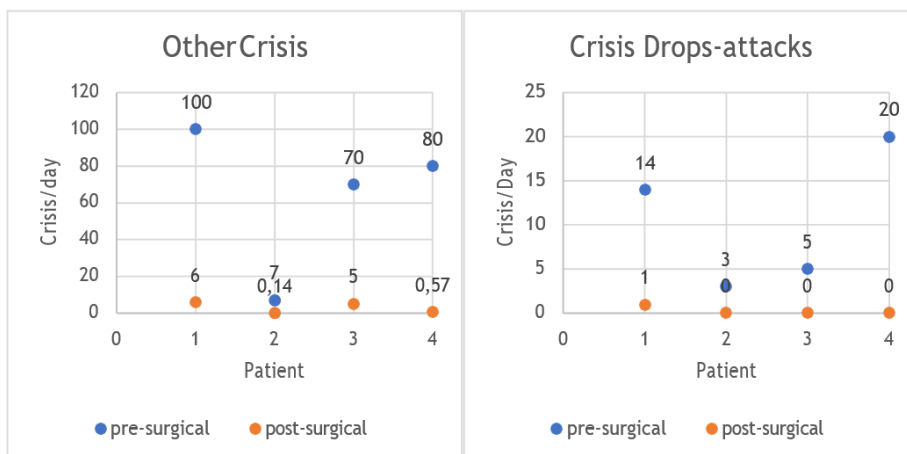
- Lamotrigine 100mg (2cp - 0 - 2cp)
- Clobazam 10mg (2cp - 2cp - 2cp)

- Carbamazepine 200mg (2cp – 2cp – 3cp)
- Gabapentin 300mg (2cp – 1cp – 1cp).

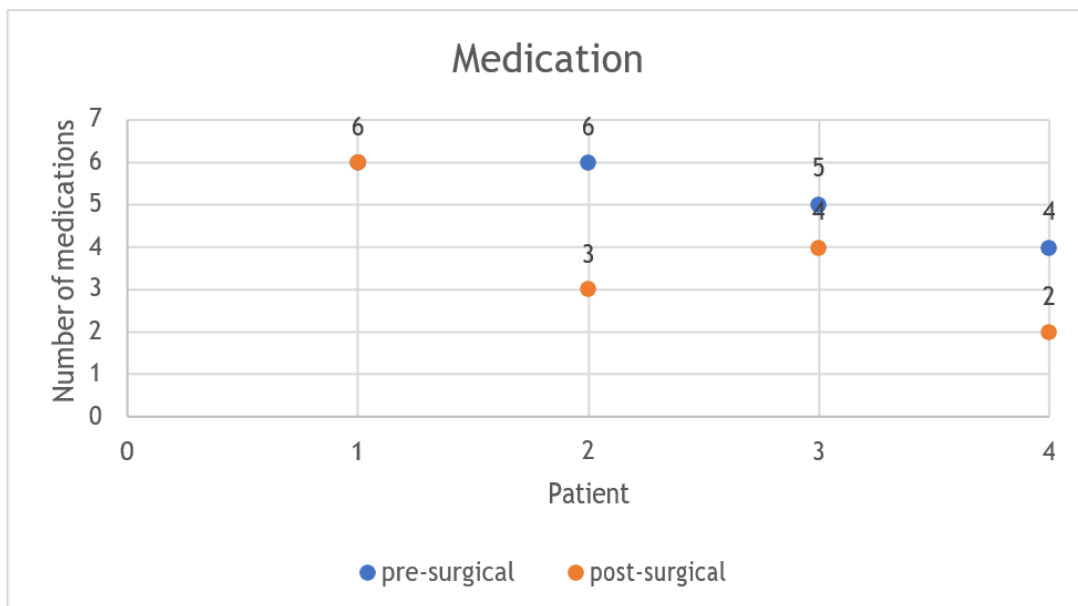
The medical approach consisted of the evaluation of the case in a meeting of UNIPETE with Epilepsy and Functional Neurosurgery, the findings of Video-EEG evidenced an asymmetric and disorganized activity, a very frequent epileptiform activity was also evident, with acute wave morphology of projection progression in the posterior regions of the left hemisphere in continuous incidence. Monitoring showed numerous waking focal motor seizures, with signals located in the posterior regions on the left and a clonic crisis during sleep, with ictal onset in the fronto-central region on the left.

With an established diagnostic hypothesis of refractory epilepsy, it was decided to perform a subsequent callosotomy. The surgical procedure is performed on 04/02/2020, had complications during the procedure, on two occasions presented a soda embolism, the first was when performing the craniectomy and the second when a vein is injured during durorafia, receiving treatment at the same time by the anesthesia team with improvement after 5 minutes of established treatment. The patient evolved after surgery without fall attack seizures, in addition to reducing the other seizures to 4 times a week.

When making a comparative table (Graph 1 and 2) in the 4 cases a notable improvement in the quality of life of these patients can be observed as well as the decrease in the consumption of anticonvulsant drugs.



Graph 1: Number of epilepsy seizures the day before and after subsequent callosotomy surgery



Graph 2: Number of medications used before and after subsequent callosotomy surgery.

Discussion

Among the four patients analyzed, the same condition, Lennox-Gastaut, may be suspected. There is still little evidence of confirmation of similar cases, as they are individuals suffering from epilepsy in childhood, with seizures that do not improve with medication. The syndrome can occur when there are brain injuries during pregnancy, as well as if post-maternity conditions such as suffocation, prematurity, low birth weight, and neonatal infections can also occur. Symptoms begin to appear progressively with their growth rate, and along with them begin seizures that become increasingly intolerant to anticonvulsant drugs.

The diagnosis of an epileptic seizure can be made clinically by obtaining a detailed history and a general physical examination. Often, the help of an eyewitness is always important.

In the reported cases, there is a great similarity in the elucidated diagnostic report. Given the important information obtained in the anamnesis described. The appearance of auras must be recorded, as well as precipitating factors of the crisis. The age of onset, the frequency of seizures, and the intervals between seizures. In addition to the use of patients' medical records, we used MRI (Image 1) and EEG to arrive at the therapeutic indication. EEG is not mandatory (nor essential) for the diagnosis of epilepsy⁵.

Image 1

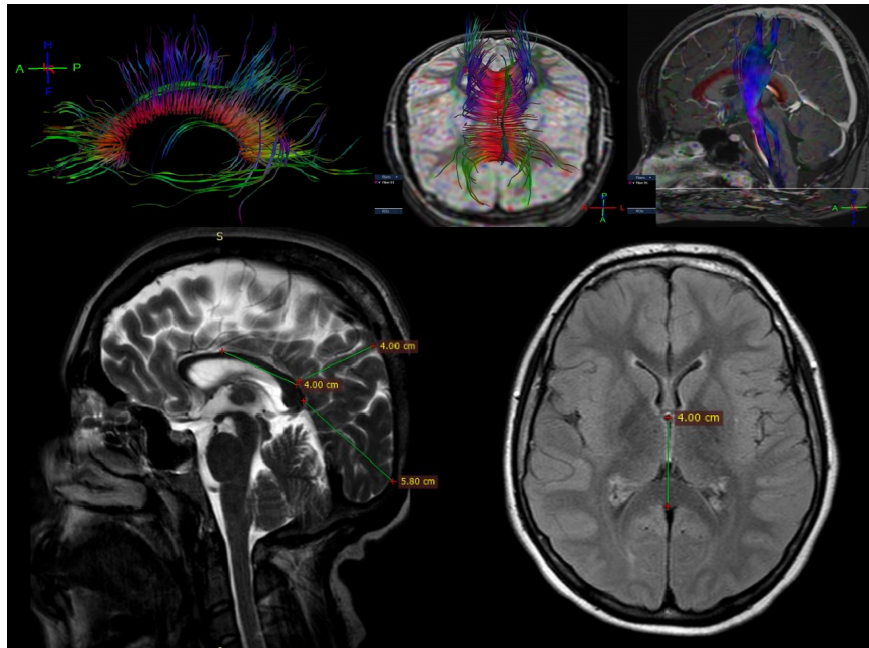


Image 2

Pre-surgical studies

The diagnosis of epilepsy is made based on the description of the epileptic seizure. In all 4 cases, magnetic resonance imaging was requested with the intention of a better diagnosis and therapeutic indication. The structural problems demonstrated by the image are important in this way that we use in the cases described.

Patients undergoing surgery at the Paulista School of Medicine during post-surgical control were classified as ENGEL 1A in relation to Drops-Attacks type seizures for patients 2, 3 and 4, in the case of patient 1 it was classified as ENGEL IIB.

Diagnosing an injury can define earlier drug-refractory treatment and support the indication for surgical treatment. About 75% of patients evaluated in tertiary centers,

specialized in refractory epilepsies, have abnormalities in the magnetic resonance imaging of the brain. Half of patients with epilepsy have structural abnormalities detected by imaging¹⁷.

During the surgical process they indicated that the patients were placed in the Fowler position (Fig 1).

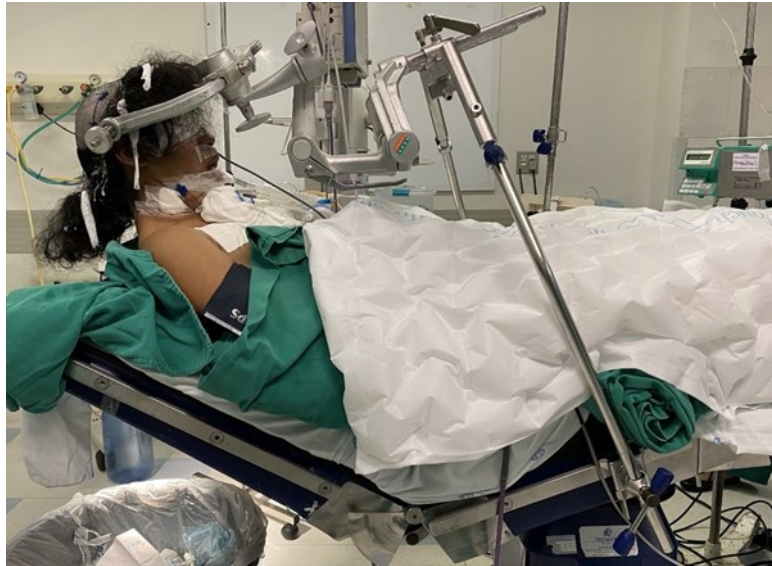

Fig1-Positioning

Patient under general anesthesia, with orotracheal intubation, subject with Maynfield head, tricotomy, washing at the surgical site with 0.2% chlorhexidine for 10 minutes. Field with clorexidine solution, placement of sterile compresses, herradura incision based on the midline on the right side, hemostasis, elevation of the flap that retracts with hooks, craniotomy with 3 holes in the midline and two holes in the distal region of the midline. 1 cm above the inion 10 cm forward and 8 cm towards side, the flap is removed (Fig 2).

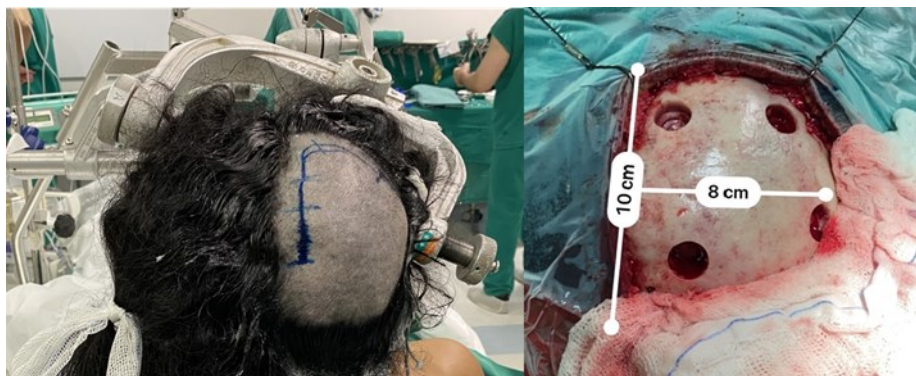

Fig 2: Measurement

It is anchored duroperiosticos. Horseshoe durotomy based on the midline, identification of the superior longitudinal sinus and bridge veins. Interhemispheric approach by separation and drainage of cerebrospinal fluid, using the technique of surgical microneurosurgery with high-resolution microscopy, release of pial adhesion, identification of the pericallosa arteries and the corpus callosum at the level of the splenium and in approximately 4 centimeters of the brain surface. The dissection and aspiration of the splene of the corpus callosum begin laterally, advancing towards the body 4 centimeters from the splenium to the body²⁰ (Fig 3)." Hemostasia, durorafia with Vicryl 3.0 thread.

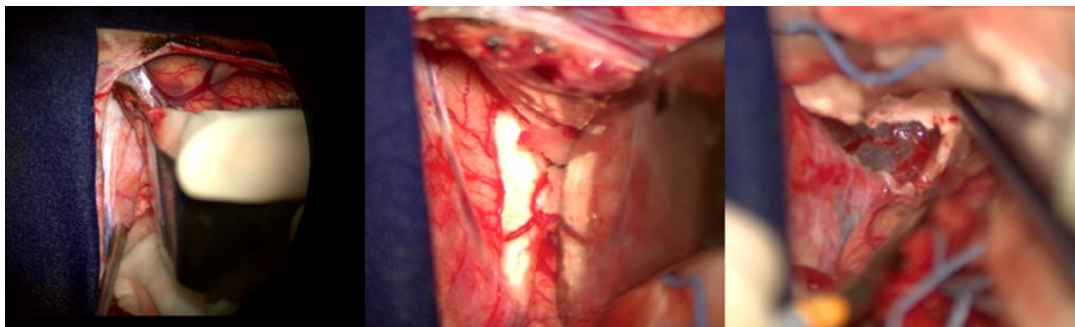

Fig 3 Approach

Colocation of flap osseus that is fixed with Mononylon 2.0 thread, deep suture with Vicryl 0 thread and skin with separate stitches with Mononylon 3.0 thread, covers the wound with sterile gauze.

The indication of posterior callosotomy is performed in order to improve the state of health of the individual with epilepsy, without altering cognition. After the operation, relatives were asked to record fall attacks and episodes of behavioral uncontrollability. They were also invited to classify the effect of the procedure as excellent, improved, unchanged or worsened depending on the well-being of patients and caregivers of the burden^{19,20,21}.

Conclusion

Through the review carried out and the results obtained in the 4 cases presented, selective posterior callosotomy plays an important role in the control of seizures in cases of epilepsy refractory to treatment with Drops-Attacks type seizures, in addition to presenting an improvement in other types of seizures. Posterior callosotomy brings some technical advantages over other techniques used in the past, mainly related to the anatomy of the focus, more favorable in the posterior region of the interhemispheric fissure. The results are like seizure control compared to previous techniques, with potential advantage in cognitive preservation, although in this series there is no ideal sample for this last analysis, since all patients had severe neuropsychomotor delay before surgery.

References

- Zicarelli CAM, Georgeto SM, Fernandes KBP, et al. Síndromes del Cuerpo Calloso. Revision de Literatura. J Bras Neurocirurg. 2015 mar 25; 121-126.
- Goldman PS, Nauta WJH. Columnar distribution of cortico-cortical fibers in the frontal association, limbic and motor cortex of the developing rhesus monkey. Brain Res. 1977 fev 25; 122: 393-414.
- Wise SP, Jones EG. The organization of postnatal development of the commissural projection of the rat somatic sensory cortex. J Comp Neurol. 1976 ago 1; 168: 313-343.
- Georgy BA, Hesselink JR, Jernigan TL. MR Imaging of the Corpus Callosum. Am J Roentgenol. 1993 mai; 949-955.
- Passos G. História y evolucion de la cirugia para epilepsia. Arq Bras Neurocir. 2017 mai 31; 1-6.
- Gusmão SS, de Souza JG. História da Neurocirurgia no Brasil. 2. ed. São Paulo: SBN; 2008.
- Romero FR. Neurocirurgia e filosofia no século XIX: como o pensamento da época influenciou o desenvolvimento da neurocirurgia moderna. Arq Bras Neurocir. 2015 jun 12; 34: 258-262.
- Marino R Jr. Neurosurgical aspects of epilepsy in adults. In: Neurological surgery. A comprehensive reference guide to the diagnosis and management of neurosurgical problems. Editor Julian
- R. Youmans. WB Saunders Company. Philadelphia. PA. 1990
- Griffith HB. Cerebral hemispherectomy for infantile hemiplegia in the light of the late results. Ann R Coll Surg Engl. 1967
- Avila JO, Radvány J, Huck FR, Pires de Camargo CH, Marino R Jr, Ragazzo PC, Riva D. Anterior callosotomy as a substitute for hemispherectomy. Acta Neurochir Suppl (Wien). 1980
- Costa JC, Portela EJ. Tratamento cirúrgico das epilepsias na criança. J epilepsy clin neurophysiol. 2006 Mar; 32-43.
- Frigeri, Thomas Moré. Controle de crises de queda (Drop Attacks) com calosotomia posterior seletiva : resultados e dados anátomo-radiológicos e prognósticos. Plataforma da PUCRS, 2019 Abril. Disponível em: <http://tede2.pucrs.br/tede2/handle/tede/9003> > Acesso em 14 de dezembro 2019.
- Lüders H, editor. Textbook of Epilepsy Surgery. Reino Unido: Informa UK; 2008.
- Gastaut H, Roger J, Soulayrol R, et al. Childhood epileptic encephalopathy with diffuse slow spike-waves (otherwise known as 'petit mal variant') or Lennox syndrome. Epilepsia. 1966;7: 139-179.
- Roberts DW. The role of callosal section in surgical treatment of epilepsies. Neurosurg Clin North Am. 1993 abril ;4: 293-300.
- Neto AR, Centeno R, Amantéa AV, et al. Tratamento Cirúrgico das Epilepsias. Rev. Neurociências. 2001; 9(3):118-126.
- Liu RS, Lemieux L, Bell GS, et al. Progressive neocortical damage in epilepsy. Ann Neurol 2003; 53: 312-24.
- Giraldo, Mauricio; Lopera, Luz María; Arango, Miguel Embolismo aéreo venoso en neurocirugía Revista Colombiana de Anestesiología, vol. 43, núm. 1, 2015, pp. 40-44.
- Gress-Mendoza, Alma Edith, Protocolo de detección y tratamiento del embolismo aéreo. Anestesia en Neurocirugía. Vol. 14 Supl. 1 Abril-Junio 2018, pp S81-S82.
- Eliseu Paglioli, Md, PhD et all, Selective posterior callosotomy for drop attacks. American Academy of Neurology. 2016.

22. Control of drop attacks with selective posterior callosotomy: Anatomical and prognostic data. Tomas Frigueri, Eliseu Paglioli, Ricardo Bernardi Soder, William Alves Martins, Rafael Paglioli, Rita Mattiello, Ricardo Paganin, André Palmini. ELSEVIER. 2021

Citation: Oscar SM, Osorio V, Pedro GL, Jorge O, Samuel V, Ricardo SC . "Posterior Selective Callosotomy: A Case Series". SVOA Neurology 3:2 (2022) Pages 51-60.

Copyright: © 2022 All rights reserved by Oscar SM., et al. This is an open access article distributed under the Creative Commons Attribution License, which permits unrestricted use, distribution, and reproduction in any medium, provided the original work is properly cited.