

Effects of Rotigotine on Motor and Non-Motor Symptoms in Vascular Parkinsonism: A Pilot Study

Sabrina Anticoli, MD¹, Francesca Romana Pezzella, MD¹, Maria Cristina Bravi MD¹ and Marilena Mangiardi, MD^{1*}

¹Stroke Unit Department, San Camillo-Forlanini Hospital, Rome, Italy

*Corresponding Author: Marilena Mangiardi MD, MSc, Stroke Unit Department, S. Camillo-Forlanini Hospital, C.ne Gianicolense 87, 00152, Rome, Italy, Tel: +39-06-58703313; Fax: +39-06-58705479

Received: April 18, 2022 Published: April 28, 2022

Abstract

Background: The effectiveness of available therapeutic interventions for vascular parkinsonism (VaP) is not yet established and still under-investigated. Levodopa can be useful for treating VP, but it may increase serum homocysteine levels resulting in cerebral arteries stiffness and thrombotic events. Our work hypothesis is that transdermal rotigotine patch, a non-ergolinic dopamine-receptor agonist (DAs), may represent a potential therapeutic alternative to levodopa.

Methods: The aim of this 12-month prospective, open-label, multi-center pilot study, has been to observe if transdermal rotigotine patch improved VP-related motor and non-motor symptoms. Eleven patients were assessed at enrolment (T0), at 6 (T1) and at 12 (T2) months after starting rotigotine by the Unified Parkinson's Disease Rating Scale (UPDRS), Mini Mental State Examination (MMSE), Montreal Cognitive Assessment (MOCA), Neuropsychiatric Inventory (NPI), Beck Depression Inventory II (BDI-II).

Results: The UPDRS score in sections I to III, MMSE, MOCA and BDI at both T1 and T2 visits, improved in treated patients with medium to large effect size (Bonferroni-adjusted p -values < 0.05). There were no changes in NPI scores over time. No serious adverse events were reported. Two patients discontinued treatment due to skin reactions at the application site.

Conclusions: The present pilot study provide preliminary suggestions that transdermal rotigotine can be a valuable therapeutic option to manage VaP-related motor and non-motor symptoms. Clinical trials are needed to confirm the clinical efficacy of transdermal rotigotine in a larger VaP-patients sample size.

Keywords: Vascular Parkinsonism, Stroke, Neuropharmacology, Rotigotine

Introduction

Vascular parkinsonism (VaP) is an extrapyramidal syndrome related to vascular encephalopathy whose clinical features are quite different from idiopathic Parkinson disease (PD) [1]. The diagnosis of VaP is based on the presence of clinical parkinsonism, with variable motor and non-motor signs that are corroborated by clinical, anatomic or imaging findings of cerebrovascular disease. Three VaP subtypes have been described:

- a) the acute or subacute post-stroke VaP subtype presents with acute or subacute onset of parkinsonism, typically asymmetric, and responsiveness to dopaminergic drugs;
- b) the insidious onset VaP subtype presents with progressive parkinsonism with prominent postural instability, gait impairment, corticospinal, cerebellar, pseudobulbar, cognitive and urinary symptoms and poor responsiveness to dopaminergic drugs;
- c) mixed or overlapping syndromes of idiopathic Parkinson's disease or other neurodegenerative parkinsonisms with cerebrovascular disease (CVD). [2]

Dopaminergic agonists, commonly used in idiopathic PD, can be administered even for treating VP [3]. However, the relationship between clinical signs, neuroimaging features, residual pre-synaptic dopaminergic function and response to dopaminergic therapy are still under investigation in VP [4-6].

Although levodopa represents the most effective dopaminergic treatment, its use can increase serum homocysteine levels with the development of cerebral vascular stiffness which in turn can potentially result in vascular encephalopathy worsening [7,8]. Rotigotine, a dopamine receptor agonist with high affinity for the dopamine D2 to D5 receptors, but with low affinity for D1 receptors [9], may represent a potential alternative to levodopa in reducing the symptoms of VP, also on the basis of its rapid onset of action [10]. Here, we explored the clinical effectiveness of rotigotine on motor and non-motor symptoms in patients with VaP.

Methods

Study design

The study protocol was conducted in compliance with the Institutional Review Board/Human Subjects Research Committee requirements and in accordance with the ethical standards laid down in the 1964 Declaration of Helsinki and its later amendments.

We conducted a prospective, open-label, multi-center pilot study on patients admitted to the Stroke Unit of S. Camillo-Forlanini Hospital, Rome and to the "Parkinson's Disease Clinical Trial Center" in San Raffaele Hospital, Cassino from December 2016 to December 2017.

Inclusion criteria

Patients of both sexes, aged ≥ 18 years, presenting with extrapyramidal disorders started within 3-6 months after an ischemic stroke in strategic thalamo-cortical areas (thalamus or internal capsule), with concomitant leukoencephalopathy.

Exclusion criteria

National Institute of Health Stroke Scale (NIHSS) >8 ; absence of vascular signs on neuroimaging; presence of malignant diseases or concomitant psychiatric disorders; concomitant use of antidopaminergic drugs or other treatment interfering with dopamine receptors; previous exposure to rotigotine. Patients who did not provide a valid written informed consent were also excluded.

Assessments

Patients were evaluated at enrolment (T0 or baseline), at month 6 (T1) and at month 12 (T2) after rotigotine initiation by means of the following clinical scales: the Unified Parkinson's Disease Rating Scale (UPDRS) sections I to III, Mini Mental State Examination (MMSE), Montreal Cognitive Assessment (MOCA), Neuropsychiatric Inventory (NPI), Beck Depression Inventory II (BDI-II).

Treatment

Eligible patients started transdermal patch of rotigotine according the drug leaflet, i.e. 2 mg/day for 4 weeks and then increased to 4 mg/day for an overall treatment duration of 12 months.

Statistical analysis

Data are expressed as median (interquartile range). The clinical effectiveness of rotigotine were explored by the non-parametric analysis of variance for repeated measures (Friedman test), with reporting of effect size rated as small ($r=0.1$), medium ($r=0.3$) or large ($r=0.5$). Nominal p-values were multiplied for the number of clinical tests ($n=7$) to correct for multiple comparisons, according to the Bonferroni procedure. Corrected two-tailed p-values less than 0.05 were considered significant.

Results

Patients

Out of 13 screened and fulfilling the eligibility criteria, 11 (84.6%) patients with a median age of 76 (68-78) years agreed to participate. Of them, 7 had a unilateral parkinsonism and 4 had a predominant lower body parkinsonism after stroke. Ischemic lesion involved internal capsule and thalamus in 6 and 5 patients, respectively.

The baseline (T0) scores in clinical assessments were as follows: UPDRS=5 (4-6), 9 (7-12) and 18 (15-20) for section I, II and III, respectively; MMSE=27 (26-28); MOCA=28 (26-29), NPI=3 (2-4), BDI-II=13 (11-16).

Follow-up data

(Table 1 and Figure 1). Motor symptoms dramatically improved, as revealed by the reduction of scores in UPDRS sections I to III over the follow-up (p -values <0.01), with large effect size ($r>0.5$); this effect was more pronounced at T1 and was maintained even at T2, although in sections I and III we noted a tendency to flatten the scores.

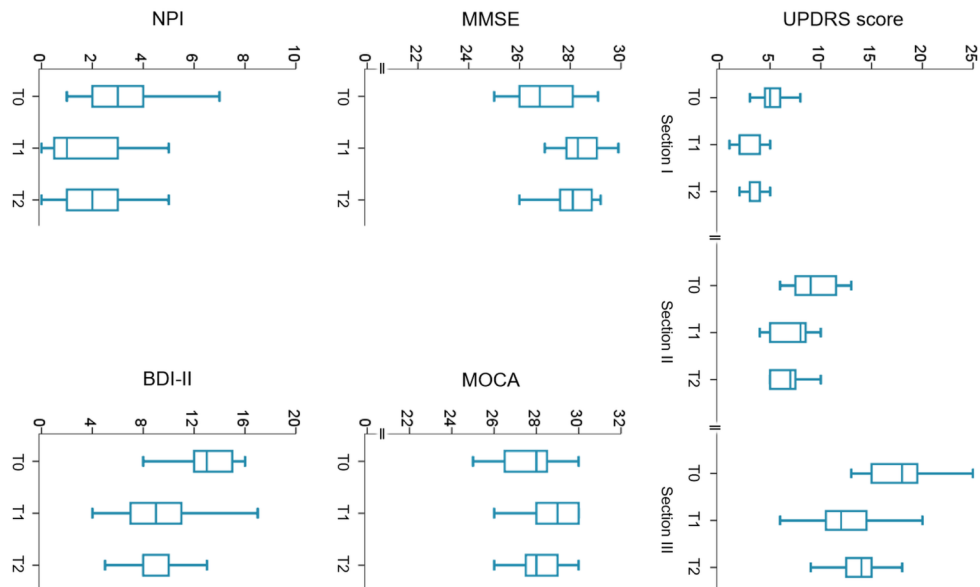


Figure 1: Changes in motor and non-motor symptoms over time expressed as median and interquartile range at different time-points.

Cognitive dysfunctions also improved, as revealed by higher scores in MMSE and MOCA (p -values <0.05), with a large effect size at T1 and medium effect size at T2.

Neuropsychiatric symptoms showed mixed results: there was no change in NPI score, whereas we found a decrease of BDI-II score at T1 that was sustained at T2, with large effect size ($r=0.63$).

Neither the clinical picture (unilateral or lower body parkinsonism) nor location of ischemic lesions (internal capsule or thalamus) affected the observed clinical improvements.

Safety

We observed skin reactions at the application site in 2 patients (18.2%) after the first month of rotigotine treatment, leading to treatment discontinuation.

Table 1: Main study findings (non-parametric analyses of the variance, Friedman test).

	χ^2 (2)	Bonferroni corrected	Effect size (r)	Effect size (r)
		p-value	at T1	at T2
UPDRS-I	21.14	0.0002	0.64	0.64
UPDRS-II	19.84	0.0003	0.63	0.63
UPDRS-III	16.05	0.002	0.63	0.63
MMSE	12.39	0.014	0.58	0.51
MOCA	9.94	0.049	0.44	0.27
NPI	7.66	0.133	0.45	0.37
BDI-II	18.20	0.0007	0.63	0.63

UPDRS: Unified Parkinson’s Disease Rating Scale; MMSE: Mini Mental State Examination; MOCA: Montreal Cognitive Assessment; NPI: Neuropsychiatric Inventory; Beck Depression Inventory II.

Discussion

VaP can be diagnosed in individual patients with possible prognostic and therapeutic consequences and therefore should be recognized as a clinical entity. In this pilot study we observed an improvement in motor and non-motor symptoms over the 12-month follow-up in VaP patients treated with transdermal rotigotine, suggesting that this patch dopaminergic treatment may be an useful strategy to manage VaP-related dysfunctions.

Atherosclerotic brain disease is common among elderly individuals, sometimes affecting also patients with idiopathic PD. These patients with so-called 'mixed disease' are likely to respond to dopamine-mimetic therapy, but to a lesser extent than patients with idiopathic PD and no atherosclerotic brain disease. A recently published systematic review and meta-analysis showed that patients with VP subjects, as operationally defined here, have a low response rate to levodopa in presence of nigro-striatal lesions that can then be used as a proxy for predicting of levodopa response [11]. Accordingly, we think that our findings may support the clinical utility of differentiating 'pure' idiopathic PD from 'mixed' extrapyramidal syndromes. The imaging features of cerebrovascular lesions, coupled with the presence of leukoencephalopathy, are important elements to determine the extent to which the extrapyramidal system is involved, i.e. the level of impairment of the pre-synaptic dopaminergic function. Therefore, our study suggests the possibility of revising the diagnostic criteria for VaP to provide a more comprehensive classification of motor and non-motor symptoms and their correlations with morphological and functional subtypes [13]. This should lead to the adoption of a more rational decision-making process in the dopaminergic treatment of VP [12].

We are aware that our pilot study is only hypothesis-generating and suffers from several limitations, mainly due to its open-label, observational design with a small sample size and the lack of a control group. Therefore, we cannot disentangle the role of spontaneous and rehabilitation-enhanced restoration of partially damaged functions after stroke from the crude effect of rotigotine on the observed clinical improvement. Nevertheless, we are confident that rotigotine contributed to clinical improvement observed in our cohort of patients.

Conclusions

The present pilot study provide preliminary suggestions that transdermal rotigotine can be a valuable therapeutic option to manage VaP-related motor and non-motor symptoms. In our observational study, we found improved motor and non-motor symptoms in 11 patients with VaP treated by transdermal rotigotine for 12 months follow-up.

The updated diagnostic approach to subtype definition of VaP is important to facilitate further research to better define this entity, and to improve treatment in different subtypes of VaP.

To date, there are no clinical trials, which discuss the dopaminergic effectiveness and safety in this population patients. In particular, we do not yet know whether aggressive treatment of the vascular risk factors can slow the progressive nature of the disease. Therefore, clinical trials are needed to confirm the clinical efficacy of transdermal rotigotine in a larger VaP-patients sample size.

Funding

None

Conflict of Interest

On behalf of all authors, the corresponding author states that there is no conflict of interest.

Ethical approval

The present study was approved by the Ethics Committee and was conducted in accordance with the ethical standards laid down in the 1964 Declaration of Helsinki and its later amendments.

Informed consent

All the patients involved in this study provided a valid inform consent.

References

1. Korczyn AD. Vascular parkinsonism--characteristics, pathogenesis and treatment. *Nat Rev Neurol*. 2005; 11:319-326.
2. Antonini A, Vitale C, Barone P, Cilia R, Righini A, Bonuccelli U, Abbruzzese G, Ramat S, Petrone A, Quatrone R, Marconi R, Ceravolo R, Stefani A, Lopiano L, Zappia M, Capus L, Morgante L, Tamma F, Tinazzi M, Colosimo C, Guerra UP. The relationship between cerebral vascular disease and parkinsonism: The VADO study. *Parkinsonism Relat Disord*. 2012; 18:775-80.
3. Siniscalchi A, Gallelli L, Labate A, et al. Post-stroke Movement Disorders: Clinical Manifestations and Pharmacological Management. *Curr Neuropharmacol*. 2012; 10:254-262.
4. Antonini A, Vitale C, Barone P, et al. The relationship between cerebral vascular disease and parkinsonism: The VADO study. *Parkinsonism Relat Disord*. 2012; 18:775-780.
5. Santangelo G, Vitale C, Trojano L, et al. Differential Neuropsychological Profiles in Parkinsonian Patients with or without vascular lesions. *Mov Dis*. 2010; 25:50-56.

6. Zijlmans J, Evans A, Fontes F, et al. [123I] FP-CIT spect study in vascular parkinsonism and Parkinson's disease. *Mov Dis.* 2007; 22:1278-1285.
7. Siniscalchi A, Mancuso F, Gallelli L, et al. Increase in plasma homocysteine levels induced by drug treatments in neurological patients. *Pharmacol Res.* 2005; 52:367-375.
8. Yong SW, Lee KY, Lee PH. The effect of levodopa treatment on cerebral hemodynamics in patients with Parkinson's disease, serial transcranial Doppler studies. *Parkinsonism Relat Disord.* 2010; 16:225-227.
9. Wood M, Dubois V, Scheller D, Gillard M. Rotigotine is a potent agonist at dopamine D1 receptors as well as at dopamine D2 and D3 receptors. *Br J Pharmacol.* 2015; 172:1124-1135.
10. Poewe WH, Rascol O, Quinn N, et al. Efficacy of pramipexole and transdermal rotigotine in advanced Parkinson's disease: a double-blind, double-dummy, randomised controlled trial. *Lancet Neurol.* 2007; 6:513-520.
11. Miguel-Puga A, Villafuerte G, Salas-Pacheco J, Arias-Carrión O. Therapeutic Interventions for Vascular Parkinsonism: A Systematic Review and Meta-analysis. *Front Neurol.* 2017; 8:481.
12. Zarola F. Vascular Parkinsonism sensitive to Rotigotine therapy is found in aged patients: a clinical case description. *Acta Biomed* 2018; 89: 99-100.
13. Rektor I, Bohnen NI, Korczyn AD, Gryb V, Kumar H, Kramberger MG, de Leeuw FE, Pirtošek Z, Rektorová I, Schlesinger I, Slawek J, Valkovič P, Veselý B. An updated diagnostic approach to subtype definition of vascular parkinsonism - Recommendations from an expert working group. *Parkinsonism Relat Disord.* 2018 Apr;49:9-16.

Citation: Anticoli S, Pezzella FR, Bravi MC, Mangiardi M. "Effects of Rotigotine on Motor and Non-Motor Symptoms in Vascular Parkinsonism: A Pilot Study". *SVOA Neurology* 3:3 (2022) Pages 97-101.

Copyright: © 2022 All rights reserved by Mangiardi M., et al. This is an open access article distributed under the Creative Commons Attribution License, which permits unrestricted use, distribution, and reproduction in any medium, provided the original work is properly cited.