

Neurophysiological Findings in a Patient with Posthypoxic Myoclonus after Cardio-Respiratory Arrest

Ruiz Navarrete PA^{1*} and Galdón Castillo A¹

¹Video-EEG Unit. Clinical Neurophysiology Service. Virgen de las Nieves University Hospital. Granada, Spain.

*Corresponding Author: Ruiz Navarrete PA, Video-EEG Unit. Clinical Neurophysiology Service. Virgen de las Nieves University Hospital. Granada, Spain.

Received: May 04, 2022 Published: June 03, 2022

Abstract

Introduction: Post-hypoxic myoclonus (PHM) are involuntary movements that occur after cardio-respiratory arrest (CRA). They are classified into myoclonic status epilepticus (MSE) that occurs in the first 12 hours and Lance-Adams syndrome that occurs later. The practical application of this division lies in the poor prognosis associated with MSE. To differentiate, it is useful to perform electroencephalogram (EEG) and somatosensory evoked potentials (SSEPs).

Objective: To assess the findings of the neurophysiological tests in a patient in a coma with PHM after CRA.

Method: Study of a patient admitted to Intensive Care at the Virgen de las Nieves University Hospital in Granada, with a bibliographic review in PubMed. Case: 56-year-old patient with a history of hypertension who suffers from CRA, after which an examination is compatible with coma of unknown etiology and associated spasms.

Results: EEG is performed 6 hours after CRA, which records isoelectric periods interspersed with cortical activity. It presents spontaneously, to tactile and sound stimulation, axial myoclonic response with spasms without epileptiform correlation. At 24 hours, an EEG is performed with tracing compatible with alpha-coma. Bilateral median nerve SSEPs without cortical response (N20). At 96 hours, SSEPs is repeated with the same results, and EEG showing tracing without cortical differentiation. After the findings, the life support measures that cause the death of the patient are limited

Conclusion: Neurophysiological tests can help determine the PHM subtype that allows establishing a prognosis.

Keywords: Post-hypoxic Myoclonus, Cardio-respiratory Arrest, Myoclonic Status Epilepticus, Lance-Adams.

Introduction

Post-hypoxic myoclonus (PHM) represents a serious neurological complication after cardio-respiratory arrest (CRA) (Lee et al., 2011). They are defined as sudden and abrupt involuntary movements that can be repetitive, generalized, focal, or multifocal from an increase in neuronal excitability (Acharya JN, 2017).

Different authors classify it into two types: acute, and chronic (Malhotra S, 2012). The acute type of PHM, called myoclonic status epilepticus (MSE), occurs within the first 12 hours and the patient is usually comatose; while the chronic or late-type, known as Lance-Adams Syndrome (LAS), begins a few days or weeks later and the patient may be awake (Lee et al., 2011). It should be noted that the MSE terminology is based on clinical and not electroencephalographic criteria (Freund et al., 2017).

To help differentiate between these two entities, neurophysiological tests such as electroencephalogram (EEG), somatosensory evoked potentials (SSEPs), and video-EEG polygraphy with simultaneous recording of myography electrodes are useful (Lee et al., 2011). Although there is no specific EEG finding of PHM, in the MSE subtype, diverse patterns occur more frequently, such as burst suppression, generalized epileptiform discharges, periodic lateralized discharges, and alpha-coma (Gupta HV, 2016). While in LAS may appear epileptiform activity in one-third of the cases of predominance in central areas and even can be normal in up to 20% (Freund et al., 2017).

Regarding SSEPs, it highlights the existence of a giant morphology in LAS while in the case of MSE may be normal or absent (Freund et al., 2017); in some studies, the origin of both entities can be mixed cortical/subcortical (Elmer et al., 2016).

According to the literature, the practical application of this subdivision lies in the poor prognosis associated with patients with MSE, with a mortality rate between 90-100% of cases (Freund et al., 2017).

Objective

To assess the findings of the neurophysiological tests in a patient in a coma with PHM after CRA.

Method

The patient was admitted to the Virgen de las Nieves University Hospital in Granada from 04/10/2019 to 04/15/2019 in Traumatology service and later transferred to the Intensive Care Unit (ICU). Each EEG is performed according to the International 10-20 system with subcutaneous needle electrodes and supernumerary sphenoid and zygomatic electrodes, as well as electrocardiogram, with impedance standard maintaining less than 5 Kilohms, low filter at 0.3 Hz and high filter at 70 Hz, with sensitivity at 7 $\mu\text{V} / \text{mm}$ and registration at 30 mm / second. Such studies include verbal stimulation (the patient is called by his name and clapped) and nociceptive (brief stimulation typically with pressure on the nail or sternum). Duration: 20-30 minutes. SSEPs are performed with a subcutaneous needle electrode at the scalp level according to the International 10-20 system and with stickers at the peripheral level to stimulate the bilateral median nerve with standard impedances at 5 Kilohms, stimulation frequency at 3.17 Hz, two acquisitions of 1000 averages, low filter at 2000 Hz, high filter at 3 Hz, with a sensitivity of 5 $\mu\text{V} / \text{D}$; whereas Brainstem auditory evoked potentials (BAEPs) are performed with headphones, with a frequency of 21.9 Hz, intensity of 107 dB, two acquisitions of 2000 averages and a sensitivity of 0.5 $\mu\text{V} / \text{D}$. Both studies have a variable duration of 30 minutes. The clinical semiology of the patient is analyzed with the results of the EEG, SSEPs, and BAEPs tests. A bibliographic review was carried out in PubMed from 2011 to 2021.

Case

A 56-year-old man with a history of alcoholism, alcoholic liver disease, hypertension, mixed dyslipidemia, and chronic venous insufficiency was treated with 10 mg of Enalapril one time per day. He was admitted to Traumatology service for a fracture of the left proximal humerus due to an accidental fall 24 hours previously without presenting head trauma. During his hospital stay, he presented two hypertensive crises and nocturnal agitation controlled with antihypertensive drugs. He suffered from CRA for which basic cardiopulmonary resuscitation (CPR) was started for 5 minutes. He was transferred to the Intensive Care Unit, presenting an examination compatible with a coma of unknown etiology (an examination of brainstem reflexes shows abolition).

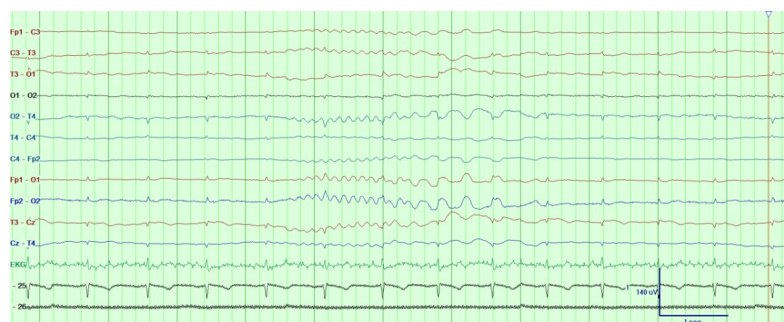
Cranial CT/Chest Angio-CT: Does not show images that justify its symptoms; it does not suggest thrombosis of the main branches of the pulmonary arteries or aortic dissection.

The patient presents sustained muscle spasms / myoclonus with verbal and tactile stimulation, for which studies are requested by the Neurophysiology Service (EEG, SSEPs, and BAEPs).

Results

The chronological sequence of the neurophysiological tests:

- 6 hours after CRA, EEG is performed in an intubated patient, with midazolam and fentanyl. Recording isoelectric periods interspersed with cortical activity. (Figure 1) It presents spontaneously, to tactile and sound stimulation, an axial myoclonic response with spasms without epileptiform correlation. (Figure 2)
- After 24 hours, a new EEG study is performed in which it presents a trace compatible with alpha-coma. (Figure 3). SSEPs of the bilateral median nerve in which low amplitude cervical and peripheral activity is recorded (absence of giant potentials) without cortical response (N20) in both hemispheres. (Figure 4). Brainstem auditory evoked potentials (BAEPs) do not present pathological alterations. (Figure 5)
- At 96 hours, the EEG study is repeated, showing very hypovolted baseline tracing without non-reactive cortical differentiation to stimuli. (Figure 6) In the result of the new SSEPs, the absence of cortical response is maintained. (Figure 7)
- After the findings of neurophysiological and clinical tests, the life support measures that cause the death of the patient are limited.



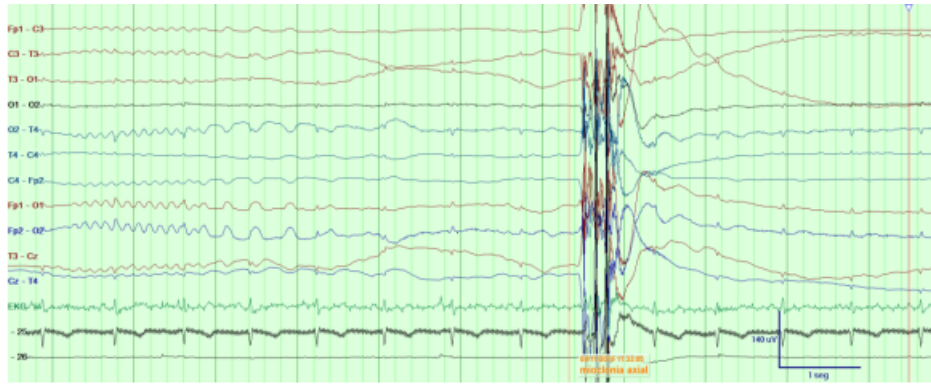


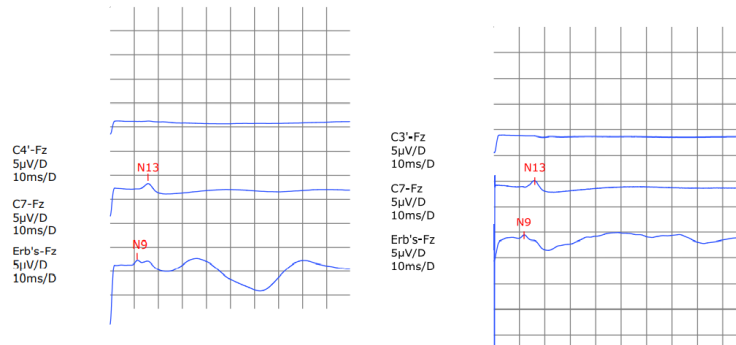
Figure 2: EEG at 6 hours

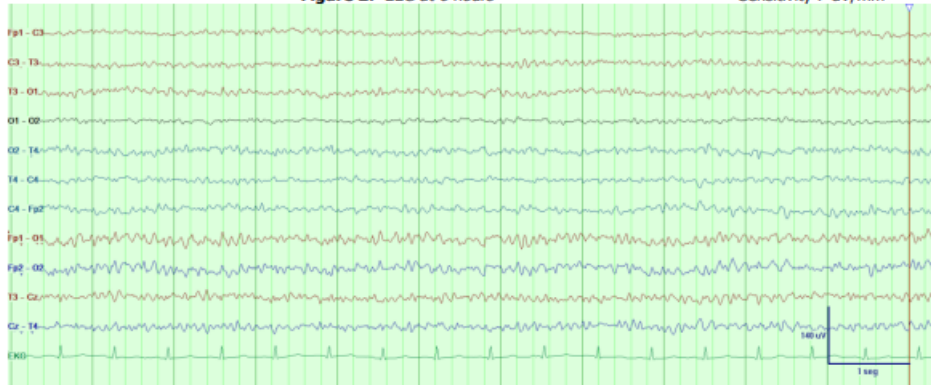

Figure 3: EEG at 24 hours

PESS MEDIANO Izquierda (Muñeca)

PESS MEDIANO Derecha (Muñeca)



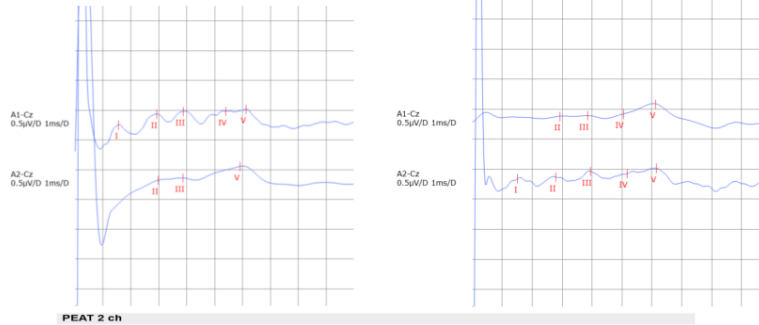
PESS MEDIANO

Individual Data					
		Left	Lat		
		ms	ms	Side Diff	
Media	C4'-Fz / C3'-Fz	N20	-	-	
	C7-Fz	N13	15.7	16.1	0.40
	Erb's-Fz	N9	11.2	11.8	0.60

Figure 4: SSEPs at 24 hours

PEAT Izquierda (Oído)

PEAT Derecha (Oído)



PEAT 2 ch

Individual Data					
		Left	Lat		
		ms	ms	Side Diff	
Media	A1-Cz	I	1.55		
		II	2.9	2.9	0
		III	3.9	3.9	0
		IV	5.4	5.1	0.30
		V	6.1	6.1	0
A2-Cz	I		1.52		
	II	3.0	2.8	0.20	
	III	3.9	3.9	0	
	IV	5.2	5.2	0	
	V	5.9	6.2	0.30	

Figure 5: BAEPs at 24 hours

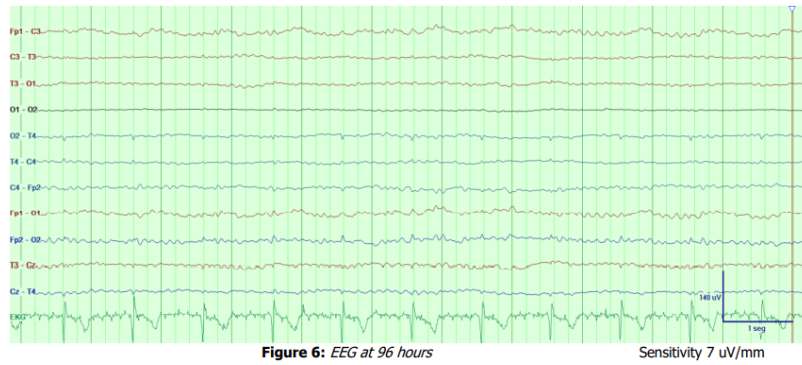


Figure 6: EEG at 96 hours

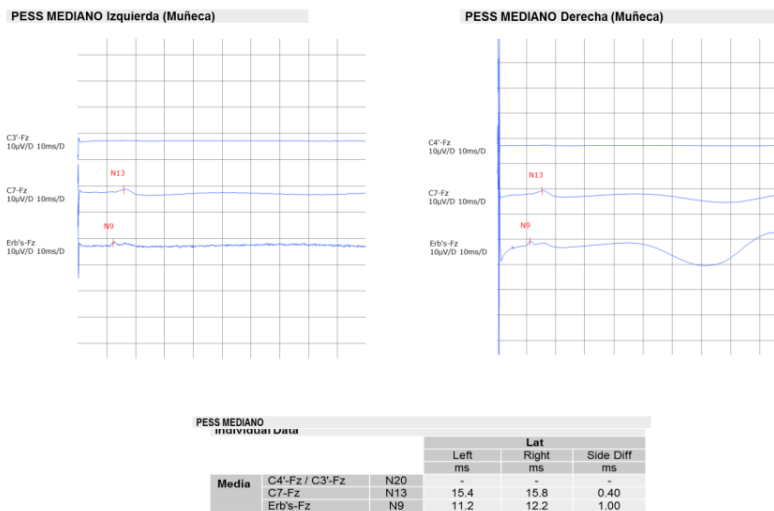


Figure 7: SSPES at 96 hours

Discussion

There are clinical differences between the types of PHM. MSE presents a comatose state of consciousness, it occurs in the first 12-24 hours (Marcellino C, et al., 2020), it can be multifocal/generalized, it is produced by ischemic brain damage with neuronal necrosis, it lasts 30 minutes, the myoclonus is usually spontaneous and has an extremely poor prognosis. On the other hand, LAS tends to have a conscious state, it starts later, it becomes chronic, myoclonus is usually due to intentional movements, it is caused by hypoxic brain damage, it lasts from minutes to hours, and it has a good prognosis. (Freund et al, 2017)

LAS occurs in patients after a state of hypoxia, mainly due to acute asthma attacks. (Bauer G et al., 2013) The most common etiologies of hypoxia are respiratory arrest, anesthetic, surgical accidents, heart disease, and drug overdose. (Malhotra S., et al., 2012) About the case, the patient had no personal respiratory pathological history, and the CRA was not related to asthma; in addition, he presented loss of consciousness within a few hours, which is why it can be classified as MSE.

In addition to the time of evolution, PHM can be classified by their semiological distribution into generalized or multifocal/focal subtypes:

- Generalized PHM usually appears on the first day after hypoxic damage; it can involve the axial and proximal muscles of the extremities. (Gupta HV, et al., 2016) Otherwise, multifocal/focal myoclonus can take up to three days to appear they are more asymmetric and have a better prognosis. (Freund et al, 2017)

It can also be classified according to their origin into cortical and subcortical myoclonus:

- Myoclonus can be cortical, with distal and asynchronous spasms, or subcortical with proximal and synchronous jerks. The myoclonic type of cortical origin has a better prognosis. (Mikhaeil-Demo et al., 2017)

MSE presents generalized myoclonus in a coma, it is believed to have a subcortical origin, it can occur spontaneously or be sensitively stimulated, while in LAS myoclonus is usually multifocal with a cortical origin. (Gupta HV, et al., 2016) Some patients may have a pattern of mixed origin because the hypoxic lesion is found in multiple structures. (Acharya JN, 2017) Those patients with generalized PHM involving axial structures that appear bilateral and synchronized may have a more severe prognosis than those without these features. (Freund et al, 2016) The patient presented axial, symmetric, and bilateral myoclonus with a generalized distribution, which occurred spontaneously, by sensory and verbal stimulation, that's why it could have a subcortical origin.

Clinical indicators allow to differentiate between MSE and LAS. They can also help to differentiate between the MSE subtypes. Those indicators are clinical characteristics of myoclonus, neurological examination (presence of a coma), and response to treatment. (Freund et al., 2017) There are no standard treatment guidelines for MSE or LAS; the response to treatment is based on anecdotal evidence focused on the cortical or subcortical origin. (Acharya JN, 2017)

Although clinical classification is useful, it can contribute to erroneous prognoses that lead to premature withdrawal of medical attention or prolong unnecessary medical treatment. (Acharya JN, 2017)

MSE with the worse prognosis is related to EEG patterns that suggest severe neurological injury: Isoelectric activity, burst suppression, status epilepticus, and alpha-coma. (Freund et al., 2016). The patient had burst suppression at 6 hours and an alpha-coma at 24 hours, which indicates a poor prognosis.

This suggests that neurophysiological tests are more helpful to the prognosis than the clinical presence of PHM. (Freund et al., 2016) In addition, they help to define whether the myoclonus has a cortical or subcortical origin, defining the subtypes of PHM and the prognosis. (Freund et al., 2017)

The absence of N20 (cortical response) in SSEPs accurately predicts a death or survival outcome with a non-conscious state (Bauer G et al., 2013), as presented by the patient at 24 hours and 96 hours.

Cortical myoclonus is represented by giant SSEPs, a correlation between epileptiform discharges on EEG and clinical myoclonus using EEG-EMG polygraphs. On the other hand, subcortical myoclonus can be differentiated from cortical myoclonus by the absence of giant potentials. (Freund et al., 2017) The EEG shows an inconsistent relationship between myoclonus and epileptiform activity. The patient's SSEPs showed an absence of giant potentials.

Imaging studies such as computed tomography scans or magnetic resonance imaging do not allow the diagnosis of LAS or MSE (Ha Lim Lee 2011). MSE predicts death or a permanent vegetative state in more than 90% of survivors. (Wijdicks et al., 2006) However; MSE can be confused with LAS in patients with persistent coma who receive sedation. (Lance J, 2011) Therefore, neurophysiological findings provide greater certainty to the prognosis.

The patient clinically presented PHM compatible with MSE, due to the time of evolution and the state of consciousness. The semiology of the PHM corresponded to the subtype with the most serious prognosis, generalized. The EEGs performed serially on the patient for 96 hours, during which he remained in the ICU, showed malignant patterns, which, when associated with the myoclonus and the findings obtained in the SSEPs worsened his prognosis. All these exposed factors contributed to the fatal outcome of the patient.

Conclusion

Neurophysiological tests can help determine the PHM subtype that allows for establishing a prognosis.

Conflict of Interest Statement

None of the authors have potential conflicts of interest to be disclosed.

Author contribution statements

Galdón Castillo conceived of the presented idea. Ruiz Navarrete acquired the data, reviewed the literature, and analyzed the results. All authors contributed to the final manuscript.

Acknowledgement

This research did not receive any specific grant from funding agencies in the public, commercial, or not-for-profit sectors.

References

1. Aicua Rapun I, Novy J, Solari D, Oddo M, Rossetti AO. Early Lance-Adams syndrome after cardiac arrest: Prevalence, time to return to awareness, and outcome in a large cohort. *Resuscitation*. 2017 Jun; 115:169-172. Epub 2017 Mar 22
2. Acharya JN. Post-hypoxic myoclonus: The good, the bad and the ugly. *Clin Neurophysiol Pract*. 2017; 2:105-106. Epub 2017 May 5
3. Bauer G, Trinka E, Kaplan PW. EEG patterns in hypoxic encephalopathies (post-cardiac arrest syndrome): fluctuations, transitions, and reactions. *J Clin Neurophysiol*. 2013;30(5):477-489. doi:10.1097/WNP.0b013e3182a73e47
4. Elmer, J., Rittenberger, J. C., Faro, J., Molyneaux, B. J., Popescu, A., Callaway, C. W. Pittsburgh Post-Cardiac Arrest Service (2016). Clinically distinct electroencephalographic phenotypes of early myoclonus after cardiac arrest. *Annals of neurology*, 80(2), 175–184. doi:10.1002/ana.24697
5. Freund, B., & Kaplan, P. W. (2017). Myoclonus After Cardiac Arrest: Where Do We Go From Here?. *Epilepsy currents*, 17(5), 265–272. doi:10.5698/1535-7597.17.5.265

6. Freund, B., & Kaplan, P. W. (2017). Post-hypoxic myoclonus: Differentiating benign and malignant etiologies in diagnosis and prognosis. *Clinical Neurophysiology*. doi: 10.1016/j.cnp.2017.03.003.
7. Gupta HV, Caviness JN. Post-Hypoxic myoclonus: current concepts, neurophysiology, and treatment. *Tremor Other Hyperkinet Mov*. 2016; 6. doi: 10.7916/D89C6XM4
8. Lance J, Adams R.D. The syndrome of intention or action myoclonus as a sequel to hypoxic encephalopathy. *Brain* 1963;86:111-36
9. Lee, H. L., & Lee, J. K. (2011). Lance-adams syndrome. *Annals of rehabilitation medicine*, 35(6), 939–943. doi:10.5535/arm.2011.35.6.939
10. Malhotra S, Mohinder K. Lance-Adams syndrome: Difficulties surrounding diagnosis, prognostication, and treatment after cardiac arrest. *Anesthesia, Essays and Researches* 2012. doi: 10.4103/0259-1162.108339
11. Marcellino C, Wijdicks EF. Posthypoxic action myoclonus (the Lance-Adams syndrome). *BMJ Case Rep*. 2020;13(4):e234332. Published 2020 Apr 16. doi:10.1136/bcr-2020-234332
12. Mikhaeil-Demo Y, Gavvala JR, Bellinski II, et al. Clinical classification of post anoxic myoclonic status. *Resuscitation*. 2017;119:76-80. doi:10.1016/j.resuscitation.2017.07.035
13. Scheibe F, Neumann WJ, Lange C, et al. Movement disorders after hypoxic brain injury following cardiac arrest in adults [published online ahead of print, 2020 May 16]. *Eur J Neurol*. 2020;10.1111/ene.14326. doi:10.1111/ene.14326
14. Sivaraju A, Gilmore EJ, Wira CR, Stevens A, Rampal N, Moeller JJ, Greer DM, Hirsch LJ, Gaspard N. Prognostication of post-cardiac arrest coma: early clinical and electroencephalographic predictors of outcome. *Intensive Care Med*. 2015 Jul; 41(7):1264-72. Epub 2015 May 5
15. Sivaraju A, Maciel CB, Youn TS, Gaspard N, Greer DM, Hirsch LJ, Gilmore EJ. Electro-clinical characteristics and prognostic significance of post anoxic myoclonus. *Resuscitation*. 2018 Oct; 131:114-120. Epub 2018 Jun 28
16. Wijdicks EF, Hijdra A, Young GB, Bassetti CL, Wiebe S. Practice parameter prediction of outcome in comatose survivors after cardiopulmonary resuscitation (an evidence-based review): Report of the Quality Standards Subcommittee of the American Academy of Neurology. *Neurology* 2006;67:203-10.

Citation: Ruiz Navarrete PA, Galdón Castillo A “Neurophysiological Findings in a Patient with Posthypoxic Myoclonus after Cardio-Respiratory Arrest”. *SVOA Neurology* 2022, 3:3, 131-136.

Copyright: © 2022 All rights reserved by Ruiz Navarrete PA., et al. This is an open access article distributed under the Creative Commons Attribution License, which permits unrestricted use, distribution, and reproduction in any medium, provided the original work is properly cited.