

# Discrete and Atypical Presentation of Giant Posterior Fossa Epidermoid Cyst: A Case Report

Andjela Gavrilovic\*

Worldwide Clinical Trials, Serbia.

\*Corresponding Author: Dr. Andjela Gavrilovic, Worldwide Clinical Trials, Serbia.

Received: June 23, 2022 Published: July 06, 2022

## Abstract

Epidermoid cysts of the brain (also called intracranial epidermoid cysts or tumors) are benign, rare tumor-like lesions, most often congenital due to maldevelopmental ectodermal inclusion during neural tube closure or acquired (post-surgical or post-traumatic implantation). The incidence is between 1% and 2% of all intracranial tumors, usually located in the parasellar region and cerebellopontine angle. Epidermoid cysts located in the posterior fossa usually arise in the lateral subarachnoid cisterns and those located in the brain stem are rare. They have cheesy and flaky white soft putty like content due to epithelial keratin and cholesterol crystals present. Epidermoid cysts grow very slowly having a similar pattern of the epidermal cells of the skin. Recommended treatment of choice is neurosurgical removal of cystic components with complete resection of capsule. This case is reporting a 34-year-old-man who underwent two neurosurgical procedures for surgical removal of almost silent and giant epidermoid cyst located bilaterally in posterior cranial fossa.

**Keywords:** Posterior fossa, epidermoid cyst, atypical facial pain and discomfort

## Introduction

Epidermoid cysts are very slow growing, most often congenital, tumor-like, benign hamartomatous structures which, from their location and size, may interfere with normal neural functions but are usually clinically silent since the slow increase in size allows adaptation and compensation by the nervous system to the presence of the space-occupying mass. They are considered to arise from remnants of embryonic epidermal elements that remain closely associated with the infolding neural tube when it separates from the overlying neural plate - during closure of the neural groove and disjunction of the surface ectoderm with neural ectoderm between the third and fifth weeks of embryonic life.

The incidence range between 1% to 2% of all intracranial tumors [1,2,3,4,5]. There may be increased prevalence in males [6]. The usual locations of epidermoid tumor are parasellar region and cerebellopontine angle and is less commonly sylvian fissure, suprasellar region, cerebral and cerebellar hemispheres [7,8,9,10,11,12,14,15,16,17,18] and lateral and fourth ventricles. Epidermoid cysts located in the posterior fossa usually arise in the lateral subarachnoid cisterns [9,14,19] and those located in the brain stem are rare [1,4,19,20,21,22]. Growth rate of epidermoid tumors is similar to epidermal cells of the skin and they grow along the cisternal spaces with very few exceptions of infiltrating the surrounding parenchyma of brain [37]. Pathologically, intracranial epidermoid cysts are identical to the petrous apex and middle ear congenital cholesteatomas. Epidermoid cysts typically have a thin capsule (stratified squamous epithelial lining) which macroscopically is white and pearly, and may be smooth, lobulated or nodular, and various amount of desquamated epithelial keratin and cholesterol crystals debris at the core, grossly appearing as a creamy, waxy material. They differ from dermoid cysts which have both epidermal and skin appendages such as hair and sebaceous cysts and mature teratomas which have all three layers. Cholesterol and keratin components account for their distinct imaging characteristics.

We are presenting an interesting case of giant epidermoid in posterior fossa with a discrete presentation in a 34-year-old man. The presentation, radiological imaging and surgical management are discussed.

## Case report

A 34-year-Caucasian male was referred to our Clinics for neurological consultation after being thoroughly examined by maxillofacial and ORL specialist where no signs of any pathology were found in relevant structures.

He complained of having stabbing pain in left side of face, especially maxillary portion, lasting few days and clustering last 7 months with slight amelioration after course of wide-spectrum antibiotics and no relief with over-the-counter prescribed analgetics, aggravated by physical activity (jogging). Estimated VAS score given was 6.

Medical history reveals no previous chronic diseases, traumas, operations, allergies, consumption of any medication, alcohol nor drugs. No familiar burden is stated in history for any specific disease or condition to be recorded.

In the examination room, patient was fully conscious, alert and cognitively intact. Language and speech intact. Fundi were normal, visual fields symmetric, extraocular muscle movements intact, pupils equally reactive to light. Dysesthesia and hyperalgesia were present in left maxillary region, left nostril and left eye inner corner. Facial expression was symmetric, grossly intact hearing to finger rub and whispering, symmetric palate elevation. Trapezius and sternocleidomastoid strength 5/5 symmetric. No fasciculations, no tongue deviation observed. All muscle groups showed no atrophy, rigidity, or spasticity with normal bulks. Strength was 5/5 overall. Reflexes of upper extremities' muscles were normal and on lower - KJ and AJ bilaterally slightly hyperactive, with left extensor and right flexor plantar response. There were no deficits in vibration, soft-touch, pin-prick sensation, or proprioception. Position - no deficit, symmetric. Intact finger to nose, heel to the shin, no dysdiadochokinesia, no dysmetria, no gait abnormalities, intact Romberg's. Normal gait.

### Laboratory investigations were within normal limits.

Magnetic resonance (MR) imaging showed giant predominant extra-axial, lobular, not well-defined, expansive bilateral parasagittal, temporo-medio-basal formation occupying prepontine, pontocerebellar and pontomedullar cisterns predominantly on the left, invaginating over left cavernous sinus subarachnoid space to suprasellar cistern, with compression and dislocation of pons, left trigeminal nerve, basilar artery, left optic tract, pituitary infundibulum and of unknown primary origin and unmeasurable diameters.

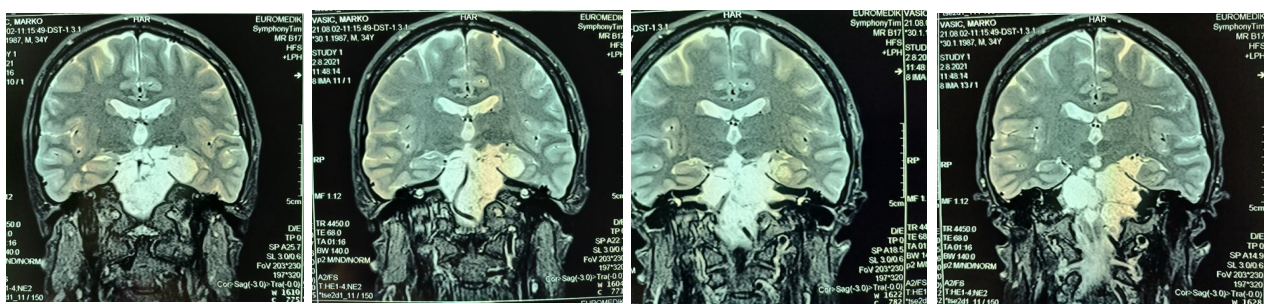
On scheduled neurological follow-up visit, Pregabalin was prescribed to ameliorate confirmed trigeminal neuralgia and patient was referred for neurosurgical consultation. Two months later, subtotal extirpation of tumor with drainage was performed through pterional osteoplastic craniotomy on the left side. Pathohistological analysis of soft, pearly material confirmed presence of lamellar keratin masses of Otho keratotic type surrounded with fragments of cist wall formed of aplatated, squamous epithelial tissue and reactive gliosis surrounding cerebral tissue consistent with epidermoid cyst.

The postoperative course was uneventful with immediate improvement of all the symptoms and post operational neurological exam showed no signs of neurological deficit.

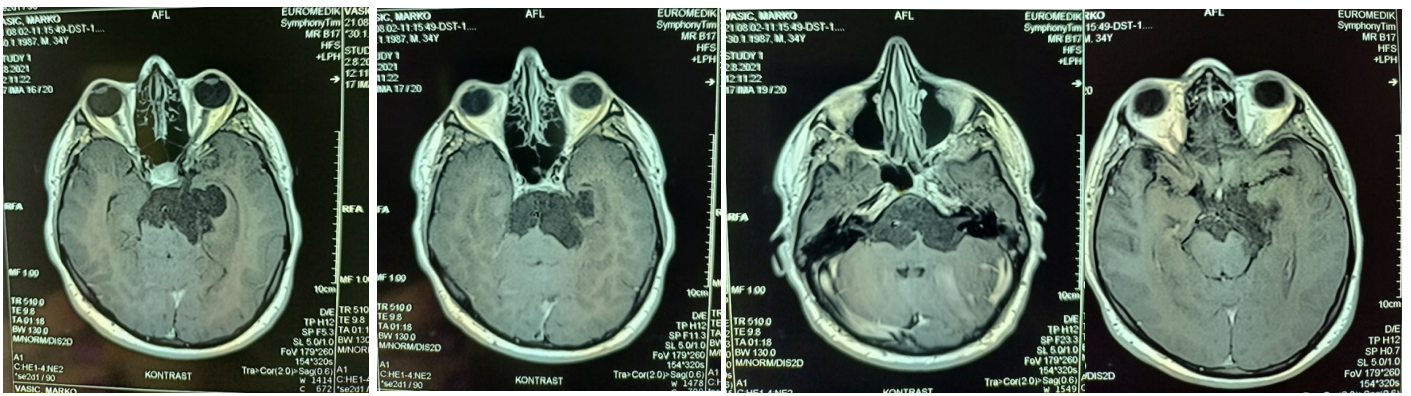
The patient was discharged on the 10th postoperative day. On follow up at second month, he was doing well and the repeat MRI showed small rest / recidivating process. Following month, resection of pontocerebellar portion of tumor via retro sigmoidal craniectomy was performed and normal neurological finding upon surgery except paresthesias in V2 trigeminal branch.

Repeated MRI after 5 months postprocedural is showing existence of significantly reduced size of cist (AP 28, LL 54, KK 47mm) located in left PCU with reactive gliosis of medio basal portions of left temporal lobe and patient complaints only about numbness and tingling on the left side of cheek.

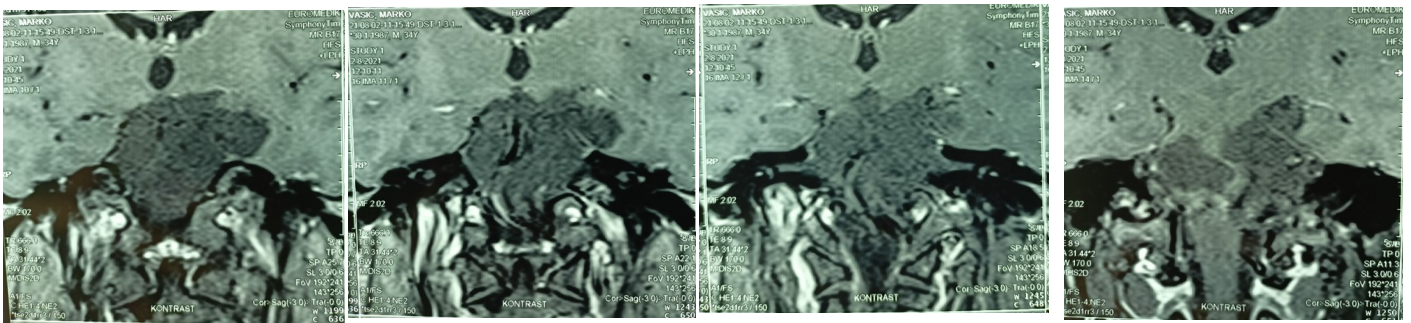
Carbamazepine in prescribed instead of Pregabalin in prophylactic doses although EEG series showed no signs of electrocortical dysfunction. and in view of very thin firmly adherent capsule to brainstem, it was not possible to do complete resection of capsule without any neurological deficits.



**Figure 1:** Brainstem epidermoid cyst: T2 FLAIR hyperintense, restriction on diffusion-weighted image with no enhancement on contrast – coronal plane.



**Figure 2:** Brainstem epidermoid cyst: T2 FLAIR hyperintense, restriction on diffusion-weighted image with no enhancement on contrast – axial plane.



**Figure 3:** Brainstem epidermoid cyst: T2 FLAIR hyperintense, restriction on diffusion-weighted image with no enhancement on contrast – targeted imaging.

## Discussion

Epidermoid cysts are very slow growing tumors with a similar growth pattern to the epidermal cells of the skin and develop from remnants of epidermal elements during closure of the neural groove and disjunction of the surface ectoderm with neural ectoderm between the third and fifth weeks of embryonic life [9,14,37,38,39,40,41]. Most of the epidermoid cysts have lateral preference in extra-axial space due to proliferation of transplanted epithelial cell remnants moved with migration of otic vesicles or developing neurovasculature [14,16]; few of the intrinsic intra-axial median located epidermoid tumors occur with separation of neuroectoderm from the cutaneous counterpart. Those located in the brainstem occur very rarely, and purely intrinsic lesions without exophytic extensions have been reported previously in six cases only [20,22,29,31,32,33]. The epidermoid cyst consists of an outer capsule, an epithelial layer, and, in some cases, an inner cystic fluid [9,40]. Enlargement of the tumor is mainly attributed to accumulation of breakdown products of desquamated epithelial cells which leads to Keratin and cholesterol accumulation in the subarachnoid space and give the milky-white or pearly appearance [14,39,40].

Epidermoids are commonly symptomatic during the adulthood and present during the 4th decade [7]. Epidermoids usually cause symptoms by compression of the surrounding neural structures and symptomatology depends on the location of the cyst. Even though the tumors can be of significant size, they present with minimal clinical symptoms and signs due to the slow growth along with the plasticity of the neural architecture, although there may be severe radiological compression of important neural structures like in our patient.

MRI scan is the modality of choice for the diagnosis. Cysts' content, derived from desquamated epithelial cells, mimics CSF on CT and MRI, with the exception of DWI which demonstrates restricted diffusion. The lesion is hypointense on T1-weighted, hyperintense on T2-weighted, FLAIR with hyperintense restriction on diffusion-weighted imaging (DWI) without any contrast enhancement [4,44,45]. If contrast enhancement occurs, it is usually at the margins of the tumor [14]. In intrinsic lesions, the absence of the tumor edema distinguishes from the gliomas. In extrinsic locations, DWI is useful to differentiate from the arachnoid cyst and abscess [46,47]. DWI is useful to know the remnant by its restriction, differentiation from abscess, and arachnoid cyst [33].



Ideal treatment of choice is removal of cystic components with complete resection of capsule [6,24,40]. These tumors should be removed with the aim of radical resection without compromising the patient's neurological condition. Although the cyst content can be aspirated easily [28], radical removal of the total tumor is not always possible because capsule is usually adherent to surrounding neurovascular structures [1,13,19,20,22,25,26,30]. Treatment of intrinsic brain stem epidermoid cysts consists of simple aspiration or subtotal excision of the tumor and may be performed due to adherence of the tumor capsule to the surrounding vital brainstem tissue. An aggressive approach may lead to disastrous complications [12,21]. Avoidance of aseptic meningitis in the post-operative period can be done with prevention of the spillage of cyst components into the surrounding subarachnoid space. Perioperative administration of steroid agents with copious irrigation with hydrocortisone has been shown to help prevent aseptic meningitis. [7,9,11,14,31,49,51]. Good long-term outcomes with minor morbidity have been achieved with a more conservative approach to difficult cases [19]. Although radical resection will prevent recurrence, in view of very thin firmly adherent capsule to brainstem, it is not always possible to do complete resection capsule without any neurological deficits.

The recurrence rate is between 1% and 54% and may be avoided to devitalize the remnant of capsule fragments during the operation [9,11,14,29,49,51]. Reoperation should be performed when the patient becomes symptomatic again, because no dissection plane between the capsule and the arachnoid during the second operation. The reoperation is usually performed for decompression. Malignant degeneration was reported for recurrent epidermoid tumors. [10,40,49,52,53]

## Conclusion

Epidermoid cysts located in the posterior fossa usually arise in the lateral subarachnoid cisterns, and those located in the brain stem are rare. Epidermoid cysts are very slow growing tumors with a similar growth pattern of the epidermal cells of the skin and develop from remnants of epidermal elements during closure of the neural groove and disjunction of the surface ectoderm with neural ectoderm between the third and fifth weeks of embryonic life. Diffusion-weighted imaging is definitive for the diagnosis. Treatment of choice is removal of cystic components with complete resection of capsule. Although radical resection will prevent recurrence, in view of very thin firmly adherent capsule to brainstem, it is not always possible to do complete resection of capsule without any neurological deficits. As the capsule is firmly adherent to the brainstem, second surgery for recurrence is only for decompression to relieve symptoms.

## Conflict of Interest

None

## Declaration of patient consent

The author certify that she has obtained all appropriate patient consent forms. In the form the patient has given his consent for his images and other clinical information to be reported in the journal. The patient understands that his name and initials will not be published, and due efforts will be made to conceal his identity, but anonymity cannot be guaranteed.

## References

1. Patibandla MR, Yerramneni VK, Mudumba VS, Manisha N, Addagada GC. Brainstem epidermoid cyst: An update. *Asian J Neurosurg*. 2016;11(3):194-200. doi:10.4103/1793-5482.145163
2. Caldarelli M, Colosimo C, Di Rocco C. Intra-axial dermoid/epidermoid tumors of the brainstem in children. *Surg Neurol*. 2001;56:97-105.
3. Caldarelli M, Massimi L, Kondageski C, Di Rocco C. Intracranial midline dermoid and epidermoid cysts in children. *J Neurosurg*. 2004;100:473-80.
4. Guidetti B, Gagliardi FM. Epidermoid and dermoid cysts: Clinical evaluation and late surgical results. *J Neurosurg*. 1977;47:12-8.
5. Kachhara R, Bhattacharya RN, Radhakrishnan VV. Epidermoid cyst involving the brain stem. *Acta Neurochir (Wien)* 2000;142:97-100.
6. Rubin G, Scienza R, Pasqualin A, Rotsa L, Da Pian R. Craniocerebral epidermoids and dermoids. *Acta Neurochir (Wien)* 1989;97:1-16.
7. DeMonte F, Gilbert MR, Mahajan A. *Tumors of the Brain and Spine*. Springer Verlag. (2007) ISBN:0387292012.
8. Tancredi A, Fiume D, Gazzeri G. Epidermoid cysts of the fourth ventricle: Very long follow up in 9 cases and review of the literature. *Acta Neurochir (Wien)* 2003;145:905-11.
9. Altschuler EM, Jungreis CA, Sekhar LN, Jannetta PJ, Sheptak PE. Operative treatment of intracranial epidermoid cysts and cholesterol granulomas: Report of 21 cases. *Neurosurgery*. 1990;26:606-4.

10. Berger MS, Wilson CB. Epidermoid cysts of the posterior fossa. *J Neurosurg.* 1985;62:214–9.
11. Netsky MG. Epidermoid tumors. Review of the literature. *Surg Neurol.* 1988;29:477–83.
12. Yamakawa K, Shitara N, Genka N, Kanaka S, Takakura K. Clinical course and surgical prognosis of 33 cases of intracranial epidermoid tumors. *Neurosurgery.* 1989;24:568–73.
13. Grant FC, Austin GM. Epidermoids: Clinical evaluation and surgical results. *J Neurosurg.* 1950;7:190–8.
14. Ogawa T, Sekino H, Fuse T, Nakamura N. Multiple intracranial epidermoids located in the brain stem and the middle cranial fossa: Case report. *Neurol Med Chir (Tokyo)* 1985;25:393–7.
15. Yasargil MG, Abernathy CD, Sarioglu AÇ. Microneurosurgical treatment of intracranial dermoid and epidermoid tumors. *Neurosurgery.* 1989;24:561–7.
16. Sabin HI, Bordi LT, Symon L. Epidermoid cysts and cholesterol granulomas centered on the posterior fossa: 20 years of diagnosis and management. *Neurosurgery.* 1987;21:789–805.
17. Eekhof JL, Thomeer RT, Bots GT. Epidermoid tumor in the lateral ventricle. *Surg Neuro l.* 1985;23:189–92.
18. Fiume D, Gazzeri G, Spallone A, Santucci N. Epidermoid cysts of the fourth ventricle. *Surg Neurol.* 1988;29:178–82.
19. Yamaki T, Takeda M, Takayama H, Nakagaki Y. Double intracranial tumours of mal developmental originteratoma at the pineal region and an epidermoid cyst in the fourth ventricle. *Neurochirurgia (Stuttg)* 1990;33:88–90.
20. Obana WG, Wilson CB. Epidermoid cyst of the brain stem. Report of three cases. *J Neurosurg.* 1991;74:123–8.
21. Fournier D, Mercier P, Menei P, Pouplard F, Rizk T, Guy G. Recurrent intrinsic brain stem epidermoid cyst. *Childs Nerv Syst.* 1992;8:471–4.
22. Leal O, Miles J. Epidermoid cyst in the brain stem. Case report. *J Neurosurg.* 1978;48:811–3.
23. Weaver EN, Jr, Coulon RA., Jr Excision of a brain stem epidermoid cyst. Case report. *J Neurosurg.* 1979;51:254–7.
24. Bhatia R, Shankar SK, Tandon PN. Pre-pontineepidermoid traversing the brain stem: A case report. *Neurol India.* 1978;26:76–8.
25. Guy G, Jan M, Guegan Y. Leslésionschirurgicales du tronc cerebral. *Neurochirurgie.* 1989;35(Suppl 1):99–101.
26. Iihara K, Kikuchi H, Ishikawa M, Nagasawa S. Epidermoid cyst traversing the pons into the fourth ventricle. Case report. *Surg Neurol.* 1989;32:377–81.
27. Kuzeyli K, Duru S, Cakir E, Pekince A, Ceylan S, Aktürk F. Epidermoid cyst of the brain stem. Case report. *Neurosurg Rev.* 1996;19:179–81.
28. Malcolm GP, Gibson R, Ironside JW, Whittle IR. Microsurgical excision of a pontomedullary epidermoid cyst with pre-pontine extension. Case report. *Neurosurgery.* 1996;38:579–83.
29. Netsky MG. Epidermoid tumors. Review of the literature. *Surg Neurol.* 1988;29:477–83.
30. Samii M, Tatagiba M, Piquer J, Carvalho GA. Surgical treatment of epidermoid cysts of the cerebellopontine angle. *J Neurosurg.* 1996;84:14–9.
31. Schwartz JF, Balentine JD. Recurrent meningitis due to an intracranial epidermoid. *Neurology.* 1978;28:124–9.
32. Sinha AK. Brain stem epidermoid cyst. *Surg Neurol.* 1999;51:687–8.
33. Yoshizato K, Kai Y, Kuratsu J, Ushio Y. Intramedullary epidermoid cyst in the brain stem. Case report. *Surg Neurol.* 1996;45:537–40.
34. Recinos PF, Roonprapunt C, Jallo GI. Intrinsic brainstem epidermoid cyst. Case report and review of the literature. *J Neurosurg.* 2006;104:285–9.
35. Takahashi M, Paz Paredes A, Scavarda D, Lena G. Brainstem epidermoid cyst in a child. Case report. *Neurol Med Chir (Tokyo)* 2007;47:140–4.
36. Ahmed I, Auguste KI, Vachhrajani S, Dirks PB, Drake JM, Rutka JT. Neurosurgical anagement of intracranial epidermoid tumors in children. *J Neurosurg Pediatr.* 2009;4:91–6.
37. Gopalakrishnan CV, Dhakoji A, Nair S. Epidermoid cyst of the brainstem in children: Case-based update. *J Child Neurol.* 2012;27:105–12.
38. Ulrich J. Intracranial epidermoids. A study on their distribution and spread. *J Neurosurg.* 1964;21:1051–8.
39. Tan TI. Epidermoids and dermoids of the central nervous system.(With two exceptional cases not represented in the literature) *ActaNeurochir (Wien)* 1972;26:13–24.

40. Toglia JU, Netsky MG, Alexander E., Jr Epithelial (epidermoid) tumors of the cranium. Their common nature and pathogenesis. *J Neurosurg.* 1965;23:384-93.
41. Cobbs CS, Pitts LH, Wilson CB. Epidermoid and dermoid cysts of the posterior fossa. *Clin Neurosurg.* 1997;44:511-28.
42. Toglia JU, Netsky MG, Alexander E., Jr Epithelial (epidermoid) tumors of the cranium. Their common nature and pathogenesis. *J Neurosurg.* 1965;23:384-93.
43. Ziyal IM, Bilginer B, Bozkurt G, Cataltepe O, Tezel GG, Akalan N. Epidermoid cyst of the brain stem symptomatic in childhood. *Childs Nerv Syst.* 2005;21:1025-9.
44. Braun IF, Naidich TP, Leeds NE, Koslow M, Zimmerman HM, Chase NE. Dense intracranial epidermoid tumors: Computed tomographic observations. *Radiology.* 1977;122:717-9.
45. Doll A, Abu Eid M, Kehrl P, Esposito P, Gillis C, Bogorin A, et al. Aspect of FLAIR sequences, 3D-CISS and diffusion weight MR imaging of intracranial epidermoid cysts. *J Neuroradiol.* 2000;27:101-6.
46. Karantanas AH. MR imaging of intracranial epidermoid tumors: Specific diagnosis with turbo-FLAIR pulse sequence. *Comput Med Imaging Graph.* 2001;25:249-55.
47. Bergui M, Zhong J, Bradac GB, Sales S. Diffusion-weighted images of intracranial cyst-like lesions. *Neuroradiology.* 2001;43:824-9.
48. Tsuruda JS, Chew WM, Moseley ME, Norman D. Diffusion weighted MR imaging of the brain: Value of differentiating between extraaxial cysts and epidermoid tumors. *AJNR Am J Neuroradiol.* 1990;11:925-34.
49. Fiume D, Gazzeri G, Spallone A, Santucci N. Epidermoid cysts of the fourth ventricle. *Surg Neurol.* 1988;29:178-82.
50. Salazar J, Vaquero J, Saucedo G, Bravo G. Posterior fossa epidermoid cysts. *Acta Neurochir (Wien)* 1987;85:34-9.
51. Zhou LF. Intracranial epidermoidtumours: Thirty-seven years of diagnosis and treatment. *Br J Neurosurg.* 1990;4:211-6.
52. Rubin G, Scienza R, Pasqualin A, Rotsa L, Da Pian R. Craniocerebral epidermoids and dermoids. *Acta Neurochir (Wien)* 1989;97:1-16.
53. Dubois PJ, Sage M, Luther JS, Burger PC, Heinz ER, Drayer BP. Malignant change in an epidermoid intracranial epidermoid cyst. *J Comput Assist Tomogr.* 1981;5:433-5.
54. Goldman SA, Gandy SE. Squamous cell carcinoma as a late complication of intra cerebroventricular epidermoid cyst. *J Neurosurg.* 1987;66:618-20.

**Citation:** Gavrilovic A. "Discrete and Atypical Presentation of Giant Posterior Fossa Epidermoid Cyst: A Case Report". *SVOA Neurology* 2022, 3:4, 137-142.

**Copyright:** © 2022 All rights reserved by Gavrilovic A., et al. This is an open access article distributed under the Creative Commons Attribution License, which permits unrestricted use, distribution, and reproduction in any medium, provided the original work is properly cited.