

Vertex Epidural Hematoma (VEDH): Review Article and Experience of One-Piece Central Craniotomy for Evacuation

Fawaz Eljili, MRCS, MSc, MPH^{1*}, Ahmed Zaidan, MD², Mohammed Mustafa, MD³ and Honida Ali, MD⁴

¹Registrar of neurosurgery, Al tamyouz (haj almardi) trauma center, Khartoum, Sudan.

²Neurosurgeon, Al tamyouz (haj almardi) trauma center, Khartoum, Sudan.

³Registrar of neurosurgery, National center for neurological sciences (NCNS), Khartoum, Sudan.

⁴Neurosurgeon, Neurospine center, Ribat university hospital, Khartoum, Sudan.

*Corresponding Author: Dr. Fawaz Eljili, MRCS, MSc, MPH, Registrar of neurosurgery, Al tamyouz (haj almardi) trauma center, Khartoum, Sudan.

Received: August 24, 2022 Published: September 10, 2022

Abstract

Introduction: Vertex EDH is rare type of EDH found in the highest skull vault and account for 0.024% of all head injuries and 0.47-8.20% of all intracranial extradural hematomas. Some cases of VEDHs extended beyond the anatomical area of the vertex. It is commonly caused by linear crossing skull fracture over the sinus caused by direct insult to the vertex or diastasis of the sagittal suture. VEDH presentation is usually atypical with non-specific symptoms and signs, and can be presented as acute, subacute or chronic. VEDH radiological feature and diagnosis is considered challenging and this is explained by its higher location in the skull vault. Ct brain with coronal cut is the best or sometimes may MRI be requested.

Method: This a review article done through the engine search PubMed and google scholar, using the key words and terms (vertex), (epidural) or (extradural hematoma) presentation, management or surgical technique, case report, case series or other relevant reviews are revised for the relevant information for our title without specification to period of time.

Our department experience and technique: Five cases out of 115 case of EDH (4.34%) were diagnosed as VEDH during the period of June 2019-june 2020. All five cases were operated through central vertex craniotomy with one bone flap including the bone over the sinus unlike the way that mentioned in the literature by doing biparietal separate parasagittal craniotomy with central bone strip left in place over the sinus.

Reviewed articles critique: Discomfort during the evacuation and difficulty to conduct direct sinus repair in case of significant tear when using the mentioned approach in the literature. Addition to that the risk of injury of the important draining veins during dural tack up.

Conclusion: Vertex EDH is a rare type of EDH but challenging in both diagnosis and surgical treatment. In the literature the commonly used approach for surgery was biparietal parasagittal craniotomy. We add our department approach and experience through one-piece craniotomy without leaving central bone strip. It was a comparison between each regarding the advantages and disadvantages. We encourage to utilize this approach craniotomy and report any advantages or disadvantages may have encountered to the literature.

Keywords: Vertex EDH, Central Craniotomy, extradural hematoma

Introduction

Vertex EDH is rare type of EDH and account for 0.024% of all head injuries and 0.47-8.20% of all intracranial extradural hematomas (1) with Mortality rate of this kind of acute hematoma is still high, ranging up to about 50% (2). The vertex is the highest anatomical area in the skull vault which is bounded anteriorly by bregma and coronal sutures, posteriorly by lambda and lambdoid suture, laterally by the parietal eminence (1). Some cases of VEDHs extended beyond the anatomical area of the vertex (1).

It is commonly caused by skull fracture mostly linear crossing over the sinus caused by direct insult vertex or diastasis of the sagittal suture (2). With other common possible cause is the dural tear of the superior sagittal sinus.

Other causes also mentioned are bleeding from the diseased vascular skull bone, as in Paget's disease; an arterio-venous fistula of meningeal artery created by a laceration of dura underlying a linear skull fracture; rebleeding in chronic cases; and spontaneous VEDHs also have been reported (1) and had vertex EDH after cranial surgery (resection of a falx meningioma in patient 1 and following resection of a high cervical arachnoid cyst in patient (2).

VEDH presentation is usually atypical with non-specific symptoms and signs (3), and can be presented as acute, subacute or chronic (1). Some mentioned that it can be oligo symptomatic for a variable period of time even if it is large.

VEDH radiological feature and diagnosis is considered challenging for many, this is explained by its higher location in the skull vault which can be missed by the radiologist if large cuts were taken and also because of its similarity in density to the surrounding bone (1). So thin slice cuts of CT brain with coronal and sagittal cuts reconstructions were advised or even requesting MRI brain (4).

Method

This a review article done through the engine search PubMed and google scholar, using the key words and terms (vertex), (epidural) or (extradural hematoma) presentation, management or surgical technique, case report, case series or other relevant review is revised for the relevant information for our title without specification to period of time.

Summary of relevant articles

Eight relevant articles fulfilling the mentioned criteria were found and summarized in their main points as follows:

Article (1): (Vertex extradural hematomas: when to operate? A case report)

Vertex extradural hematoma (VEDH) represents the blood in the quadrangular area of the skull, bounded anteriorly by bregma and coronal sutures, posteriorly by lambda and lambdoid suture, laterally by the parietal eminence. But it may extend beyond this area. VEDHs account for 0.024% of all head injuries and 0.47-8.20% of all intracranial extradural hematomas. The source bleeding is commonly from a tear in the superior sagittal sinus (SSS) followed by bleeding from the fracture line itself; dural stripping from the inner table of the skull; bleeding from the diseased vascular skull bone, as in Paget's disease; an arterio-venous fistula of meningeal artery created by a laceration of dura underlying a linear skull fracture; rebleeding in chronic cases; and spontaneous VEDHs also have been reported. They may present with unusual clinical signs that can delay diagnosis and present a dilemma as to indication for and timing of surgery. It has 18-50% of mortality rate. The decision to surgery is vital for good outcome (1).

The onset is variable and can be acute, subacute or even chronic (more than 7 days). The diagnosis of VEDHs may be postponed because of the nonspecific symptoms and clinical findings.

Diagnosing VEDHs in axial CT scans could be difficult due to near-iso density of the EDH with adjacent bone. It could be misinterpreted as artifacts or even overlooked altogether (1).

Secondly, the vertex may fall outside the scanning plane. The last, the true size of the lesion, as well as the actual mass effects on the underlying brain tissue, may be dramatically underestimated when CT slices are relatively thick. Some suggested that the use of Magnetic Resonance Imaging (MRI) for diagnosing VEDHs to supplement standard axial CT scans due to the size of the lesion and the significance of its effect on the SSS and brain tissue are more evident than in CT scans (1).

In our center, MRI is difficult to schedule on an emergency basis, and it is much more challenging to perform for neuro-trauma patients who are restless or in unstable condition. Thus, the medical team suggest a sagittal or coronal reconstruction of fine-cut axial CT images through the cranial vertex as better options for diagnosing VEDH as it showed the extent of the hematoma much more clearly than did axial images. The occurrence of VEDHs is rare (1).

This paper concluded that VEDH represents both a diagnostic and therapeutic challenge (1).

Article (2): Acute Traumatic Vertex Epidural Hematomas Surgically Treated:

The scope of this paper was to assess the early diagnosis on the outcome and this is to be achieved by neuro-radiological diagnosis and prompt surgical treatment. They noted that VEDHs represent 1 to 8% of all EDHs and Mortality rate of this kind of acute hematoma is still high, ranging up to about 50% (18). They mentioned that they have been unable to find any report of cases of acute VEDH studied with CT scan in the literature. They did bilateral parietal osteoplastic flap in ten cases out of 20 cases operated (4).

They found that Skull fractures across and suture diastasis at the vertex are associated with hematomas in a large number of cases, Vertex hematomas even if large, may be oligo symptomatic for a variable period of time, The absence of direct or indirect hematoma signs on axial CT scan does not rule out the presence of hematomas and Coronal projection CT scan or a coronal and/ or sagittal reconstruction make the blood collection visible (4).

Article (3): Vertex epidural hematomas: imaging findings and diagnostic pitfalls:

This paper focused on radiological findings with the diagnostic pitfalls. It is mentioned that small vertex EDHs can be difficult to diagnose on routine CT. MR imaging or thin section CT should be performed instead especially in patients with trauma to the skull vertex (2).

It mentioned also there are Two patients developed vertex EDHs following head trauma and two other patients had vertex EDH after cranial surgery (resection of a falx meningioma and following resection of a high cervical arachnoid cyst). Fractures were seen in both the patients with a history of trauma, at the vertex in one patient and high parietal bone in the other patient. At surgery, venous bleeding sites were identified in all four patients (2).

It concluded that Vertex EDHs are usually post-traumatic, and often follow fracture at the level of the vertex or diastasis of the sagittal suture (2).

Article (4): Extradural hematoma at the vertex: case report

In this paper, they presented a case of vertex EDH and they mentioned that it can cause increased ICP due to compression on the sinus and lacunae and impairment of the venous return. Also, they mentioned that CT scan can miss VEDH if high cuts involving the vertex area is not taken or masked by the surrounding bone. They suggest that MRI display hematoma very clearly (5).

Article (5): Vertex epidural hematomas

This paper concluded that vertex EDH should be anticipated in all patients with vertex fracture, and CT brain with coronal cut is mandatory for appropriate radiological diagnosis (6).

Article (6): Clinical features and treatment strategies for vertex epidural hematoma: a systematic review and meta-analysis from individual participant data:

This is a systematic review and meta-analysis done about clinical features and treatment strategies for vertex epidural hematoma and they mentioned that Vertex epidural hematoma (VEDH) is a rare extradural hematoma and often misdiagnosed because of its variety of clinical symptoms and characteristic location. Determining optimal timing and technique for VEDH surgery is difficult because of its midline location and atypical clinical course. This study aims to understand the clinical manifestations and current treatment strategies for VEDH (6)(3).

Decision-making regarding when and how to remove the VEDH might be challenging for surgeons because of its midline location adjacent to the injured SSS or slow symptomatic exacerbations due to bleeding from the venous origin. Unfortunately, the literature regarding VEDH is limited to case reports or technical notes, and surgical indications and techniques have not been fully established. They included all case reports, technical notes, and original articles that presented the details of the neurological status of the patient (s), radiologic images or clear documentation of VEDH characteristics, reason for decision, clinical courses, and outcomes (3).

Article (7): A surgical strategy for vertex epidural hematoma:

This paper focused mainly on the surgical strategy of the Vertex EDH which is considered an unusual consequence of head injury, and represents 1.2–8.2% of epidural hematomas (EDH). they summarized their surgical strategy as follows, the patient was positioned 30° head up with suitable head immobilization to allow Trendelenburg positioning in the event of the sagittal sinus being opened. A bicoronal skin incision was made and the linear midline fracture identified. Several burr holes were sited 2 cm either side of the midline using a high-speed drill burr rather than a perforator to prevent undue pressure on the fracture fragments. Separate left and right fronto-parietal bone flaps were raised incorporating the fracture line, leaving a 3-cm strip of bone along the midline. The clot was identified and cautious evacuation revealed several areas of bleeding, which were controlled. The exterior surface of the sinus was inspected and found to be intact. A strip of wet gelfoam was placed over the sinus and dural hitch stitches placed with assistance of pilot holes drilled obliquely through the outer table on the lateral edge of the midline strip of bone. The subdural space was inspected to exclude the presence of concomitant subdural hematoma. The bone flaps were secured using a standard method and extradural and subgaleal drains placed. They concluded that their operative approach is advantageous as it avoids using the craniotome over the potentially torn sagittal sinus and preserves a bar of bone over the sinus to allow effective dural hitch and tamponade whilst still allowing full evacuation of the hematoma, and it may be used in cases of epidural bleeding from other venous structures (e.g. transverse sinus) (7).

Article (8): Surgical management of vertex epidural hematoma: Technical case 2 report and Literature Review:

In this paper also they dealt with surgical management of Vertex epidural hematoma (VEH) which comprises 1-8% of all extradural hematomas. They mentioned that its diagnoses can be missed or delayed on presentation due to inadequacy of plain axial CT, clinical awareness is required and fine cut coronal CT head reconstruction or contrast CT should be used. It mentioned also that Literature regarding surgical management, particularly surgical technique, is lacking and due to the infrequent incidence of this extra-axial hematoma modality, neurosurgeons may be exposed to relatively few, or no cases during their careers. Importantly, the displacement and potential disruption of the SSS increases surgical risks, which mandates appropriate surgical planning and strategy (8).

The potential presence of an injured superior sagittal sinus (SSS) makes advisable to plan a surgical technique that allows both easy access and effective repair of the SSS without increasing the risk of further venous injury during the approach.

Therefore, key point to consider regarding the surgical management of VEH with sagittal suture diastasis is to spare the diastatic fracture from the craniotomy to ensure a stable anchor point for tacking up the underlying displaced dura and SSS preventing further re-accumulation, extensive bleeding from the diastatic fracture and eliminating the risk of further tearing in an injured sinus during bone flap elevation. If full access to the SSS is needed for direct repair, the sagittal island of bone can be subsequently removed, and dural or fascial flaps then used to repair the sinus when indicated. The existing medical literature regarding surgical management of VEH is scant, lack of details, and outdated. Although previous reports have addressed VEH, none of them have provided a detailed step-wise and illustrated approach that could serve as an aid for neurosurgeons facing this otherwise uncommon presentation of traumatic extra-axial bleeding. For instance, cases treated using primarily burr holes, could be more susceptible for re-accumulation of blood, and might require additional surgery. Other cases have been treated with a single bilateral craniotomy. 1, 11, 15 188 Although, this technique allows for a complete exposure of the SSS, 189 potential complications such as further tearing and bleeding of the SSS, and air embolism might happen more frequently. The use of bilateral craniotomies with preservation of the middle strip of bone, as described herein, allows for dural tack ups and prevention of further bleeding. In a 192 case of a diastatic fracture over the sagittal suture, as the one presented here, preservation of the middle bone strip is a critical decision that must be addressed by the surgeon in order to prevent further hemorrhage from the diastatic fracture, and for a better and more stable bone reconstruction (8).

Our department experience

During the period from June 2019 - June 2020 we had 115 case of traumatic EDH operated in our department of neurosurgery for neurotrauma cases at Al tamyouz (haj al mardi recently) accident and trauma hospital, only 5 cases (Table:1) are diagnosed as vertex EDH and operated successfully. The diagnosis of such type of hematoma was challenging because it is not seen frequently and most of cases were clinically stable and hematoma was not so clear in the axial cuts and confusing. But seen clearly when we requested coronal or sagittal reconstruction of the CT scan.

Our department Surgical technique

All five cases were operated through central vertex craniotomy with one bone flap including the bone over the sinus (figure 4A/5C). Patients were positioned supine with head in neutral position on headrest, bicoronal skin incision (figure 4B/5D) is used with the craniotomy area exposed either by applying two large self-retractors or by reflecting the skin flap away with rubber with silk retraction. The craniotomy were centered over the sinus and its width in the anterior posterior diameter or lateral extension depends on the extension size of the underlying hematoma (figure 4A/5C). Burr holes were done by manual hand held Hudson drill or by battery supported hand held craniotome, the location were usually two anterior and two posterior with two additional burr holes at the center sometimes and laterally away from the midline depends on the extend of hematoma laterally but usually large width is preferred with minimum distance from the midline about 4cm. Such craniotomy advantages is the direct exposure of the whole hematoma taking into consideration that the sinus is already pushed away downward by the hematoma and itself causing tamponade effect on the sinus so the risk of facing early sinus bleeding is less, such opening facilitate Dural tack up which is done at the periphery away from the area of dura near the sinus (figure 5C) and so less risk to cause injury to the important draining veins and lacunae, and for ensuring the efficacy of Dural tack up and closure of the epidural potential space we add other paracentral tack up suture mostly 2cm away from the sinus and suture is exist through the craniotomy gap to be wrapped over the bone flap and so more securing to the bone flap in its position. Other technique used to minimize the bleeding when hematoma is exposed is that evacuation done gently under normal saline irrigation and not necessary to remove all the hematoma over the sinus and let the attached part to act as auto craft dural sealant to cover any possible tear in the dural sinus with hemostatic agent used to reinforce this either by surgical or gelfoam or any other, another benefit for such approach is the good exposure to make repair for any sinus dural tear or doing craft and this in comparison to the approach mentioned in other papers with central bone strip but need to take all consideration and preparation to prevent massive blood loss which may happen during the trial of the repair. After bone flap repositioned, it will be fixed and secured in place with absorbable or non-absorbable suture, after which galea closed over external drain, skin is sutured as used (figure 4B/5D) in all operated cases there was not sinus tear seen or active sinus bleeding happened after applying this technique and before bone repositioning. The most common cause found in our cases was linear fracture crossing the midline without depressed segment followed by sagittal sutural diastasis, with bleeding from the bone controlled by applying bone wax. Early follow up imaging (figure 6 ABC) always done for the operated cases and showed adequate evacuation with excellent closure of the potential epidural space and early clinical improving.

Reviewed articles critique

The surgical technique that were used in the reviewed cases mentioned in the literature were inform of skin incision through bicoronal and craniotomy inform of bilateral parasagittal sparing the bone over the sinus (figure 1AB) and this bone strip left for dural tack up (figure 2), but we can see such approach may firstly make the evacuation process uncomfortable because we cannot see the sinus directly and if any tear is faced the repair will be difficult.

Also, if no tear is faced and dural tack up that used to be done as mentioned in this approach there will be a risk to cause injury to the draining veins and lacunae if done this way near the sinus which may lead to catastrophic consequences.

Table 1: The underlying found cause behind the VEDH in the five mentioned cases.

NO of case	Intraoperative found cause of hematoma
Case 1	Sutural diastatic fracture
Case 2	Crossing fracture at the vertex
Case 3	Crossing fracture at the vertex
Case 5	Crossing fracture at the vertex
Case 6	Sutural diastatic fracture

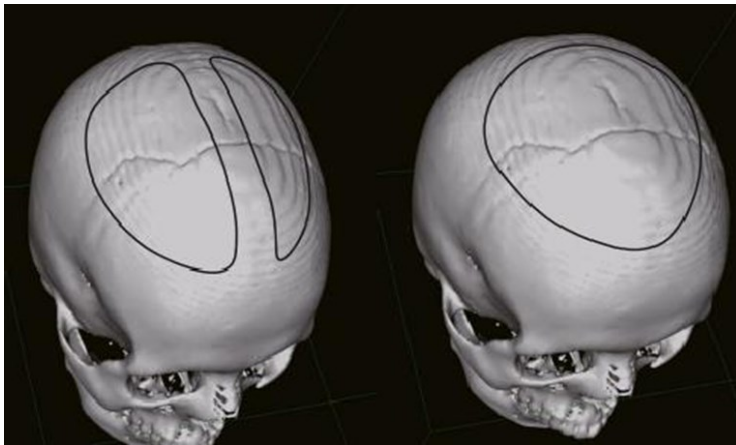


Figure 1A: 3D skull view demonstrating the area of craniotomy with biparietal bone flap and central bony strip left in place as used to be done for VEDH surgery.

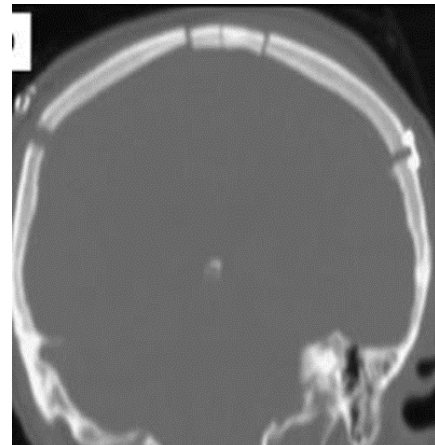


Figure 1B: CT bone window, coronal cut, showing the biparietal bony craniotomy with the central bony strip in place.

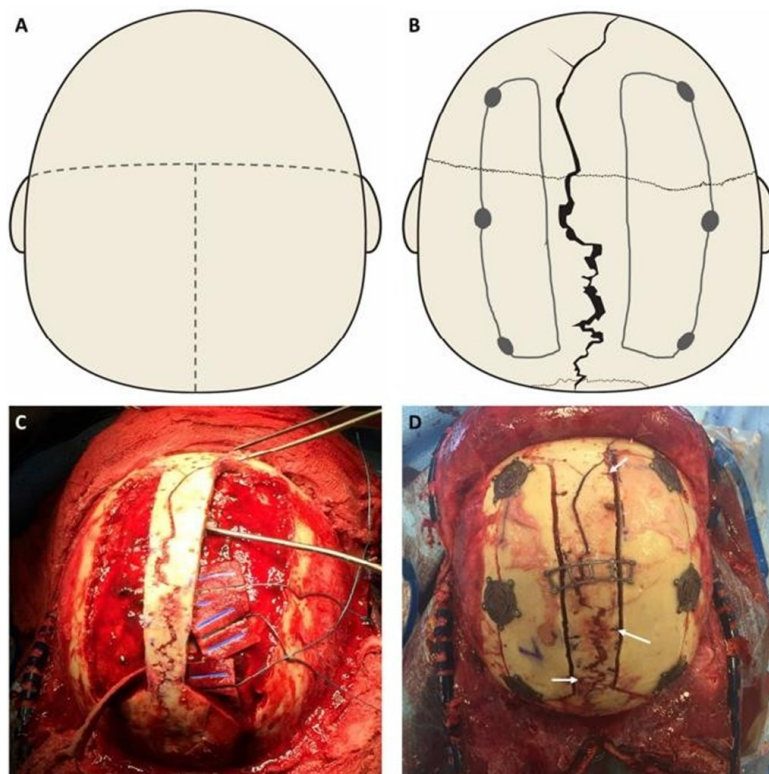


Figure 2: Intraoperative photo to the area of craniotomy and the configuration which is used to be utilized as mentioned in the previous literature technical approach to the

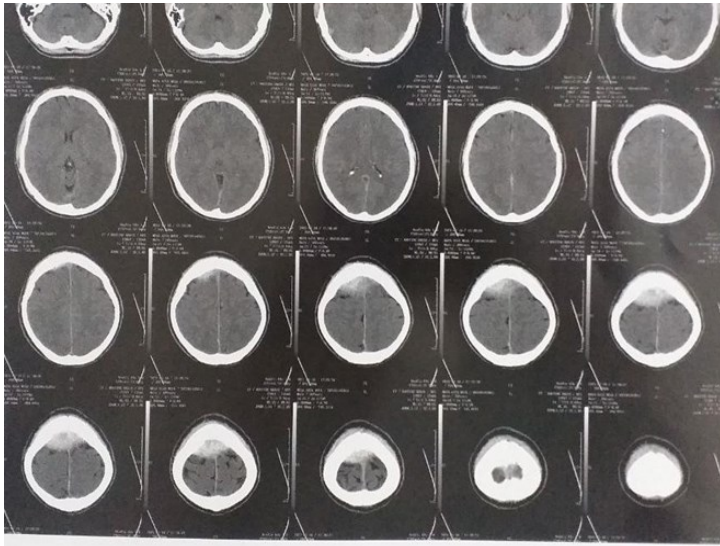


Figure 3A: Axial CT brain, soft tissue window, showing VEDH, mainly fronto-parietal

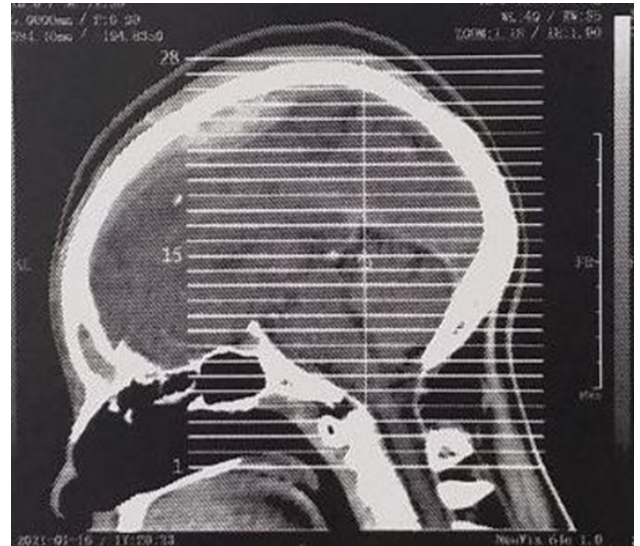

Figure 3B: CT brain soft tissue window, sagittal cut with more demonstration to the hematoma (fronto-parietal VEDH)

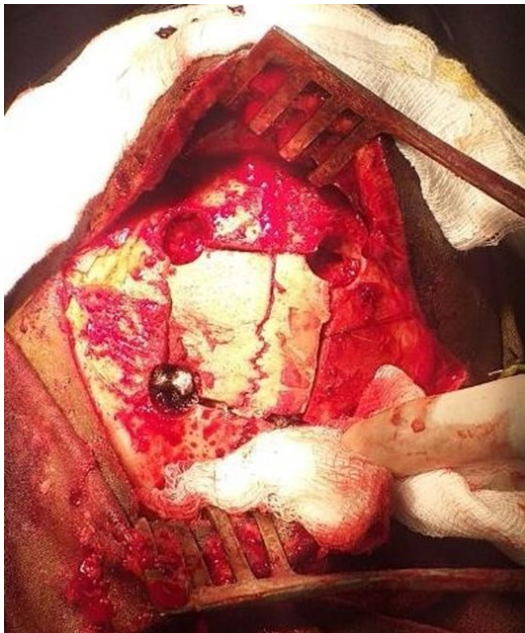


Figure 4A: Intraoperative photo showing bicoronal skin incision done with skin retracted with self-retained retractor with bone flap done over the sinus and elevated as one piece after four burr holes done lateral, both anterior and posterior. notice the diastatic sagittal suture fracture which was the underlying cause of the hematoma in this case.

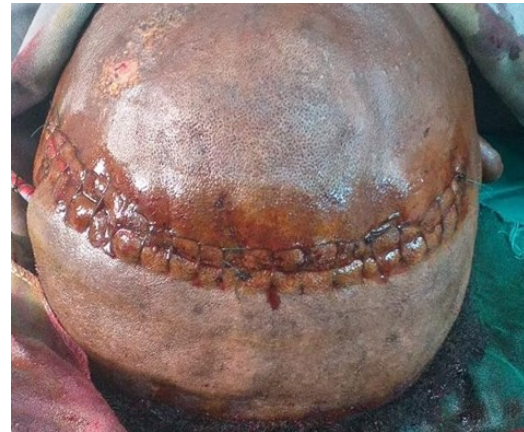

Figure 4B: Showing one of the option for skin approach which is the bicoronal c shaped skin and incision closed here by continuous lock suturing.

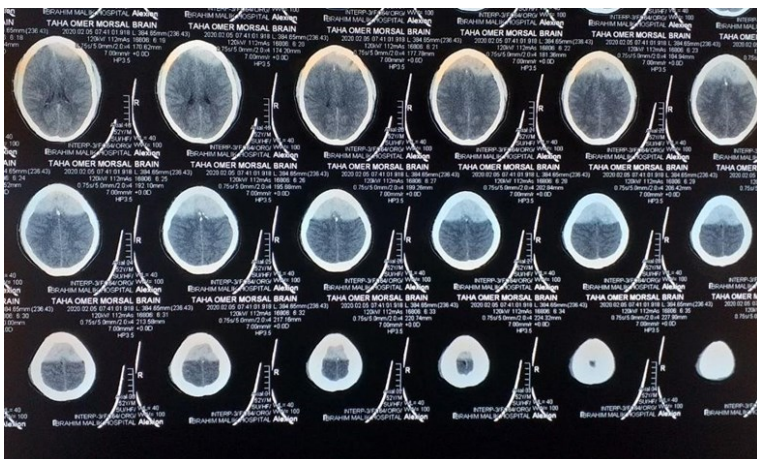


Figure 5A: Another example of VEDH with significant volume and mass effect and mainly located frontally

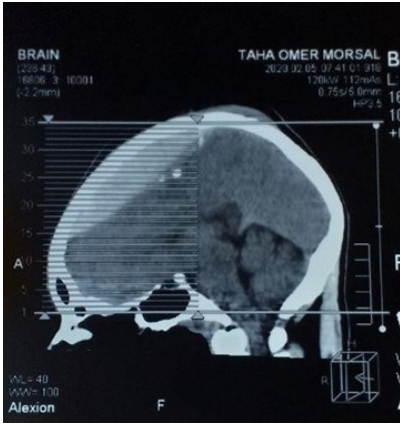

Figure 5B: CT brain sagittal cut for the same previous case with more demonstration to the hematoma

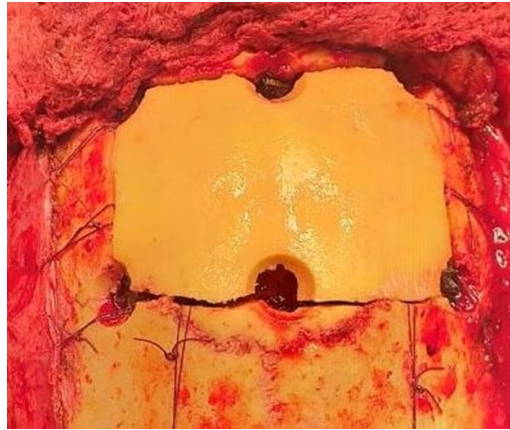


Figure 5C: Intraoperative photo showing the configuration of the craniotomy which is centered over the sinus with the four laterally placed burr holes and the additional two that were placed over the sinus in the midline so as to avoid any risk for sinus injury, noticed also the tack up sutures extending laterally with paracentral ones done and directed posteriorly to attached to the pericranium.

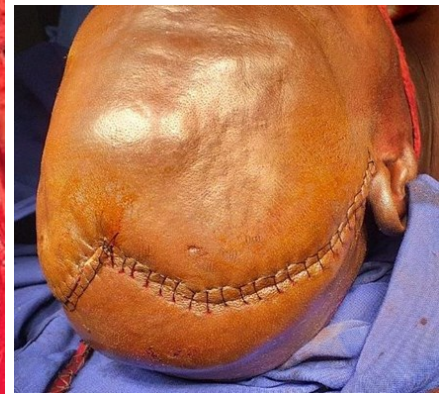

Figure 5D: Other modality of skin incision which is bicornal with central sharp angle to facilitate the reflection of skin flap

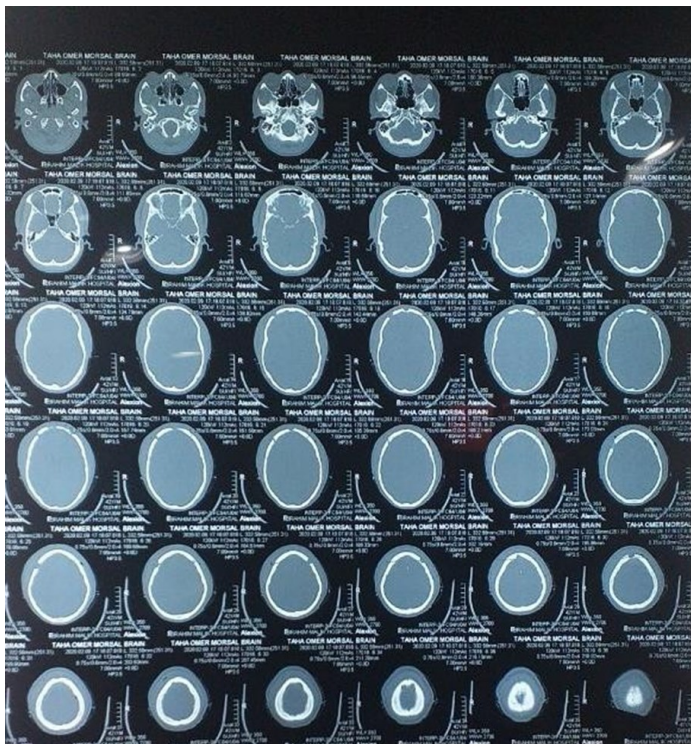


Figure 6A: Follow up CT brain bone window showing the craniotomy bone flap well fixed in place

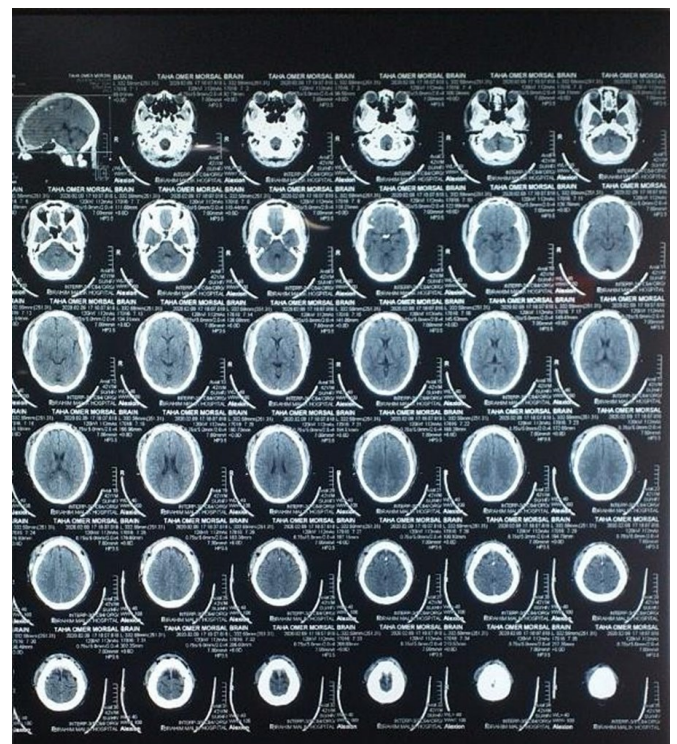


Figure 6B: Follow up CT brain, soft tissue window showing adequate evacuation of the hematoma with relaxed brain and sinus in place.

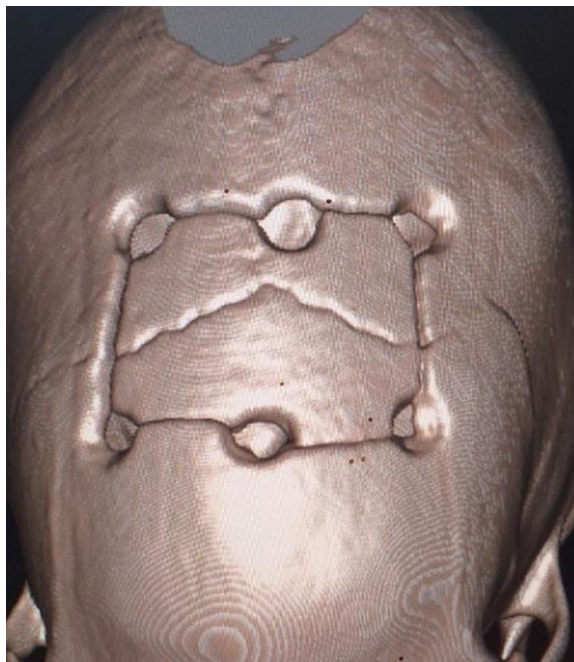


Figure 6C: 3D reconstruction of the follow up CT showing the configuration of the craniotomy and the burr holes.

Conclusion

Vertex EDH is a rare type of EDH but a challenging one in its diagnosis and surgical treatment, in the literature they mentioned the approach for evacuation by biparietal parasagittal craniotomy. We add another approach experienced in our hospital department through one-piece craniotomy without leaving central bone strip. It was a comparison between each regarding the advantages and disadvantages. we encourage to utilize this approach craniotomy and figure out any further benefits or risks may come up and to mention that to the literature. The aim was not to collect and enroll all mentioned papers or articles in the literature, but to enroll the most relevant ones especially those about the surgical approach and technique. So this is not a conclusive review article but rather an article to present our new approach in comparison to the few ones mentioned in the literature.

Conflict of Interest

The authors declare no conflict of interest.

References

1. Aji YK, Rasi M, Apriawan T, Bajamal AH. Vertex extradural hematomas : when to operate ? : Acase report. 2018; (August 2017):2016–9.
2. Harbury OL, Provenzale JM, Barboriak DP. Vertex epidural hematomas : imaging findings anddiagnostic pitfalls. 2000;36:150–7.
3. Hun J, Won K, Yoon K, Hyun T, Jong K, Kim H. Clinical features and treatment strategies forvertex epidural hematoma : a systematic review and meta - analysis from individual participantdata. Neurosurg Rev [Internet]. 2021; (0123456789). Available from: <https://doi.org/10.1007/s10143-021-01589-z>
4. Borzone M, Rivano C, Altomonte M, Capuzzo T. : Acta Neuro & irurgica. 1988;(1):55–60.
5. The AT. At the. :2–3.
6. 00006123-198911000-00023.pdf.
7. Jones TL, Crocker M, Martin AJ. A surgical strategy for vertex epidural haematoma. 2011;1819–20.
8. Fernandes-cabral DT, Kooshkabadi A, Panesar SS, Sc M, Celtikci E, Borghei-razavi H, et al.Surgical Management Of Vertex Epidural Hematoma: Technical Case Report and Literature Review. 2017;

Citation: Eljili F, Zaidan A, Mustafa M, Ali H. “Vertex Epidural Hematoma (VEDH): Review Article and Experience of One-Piece Central Craniotomy for Evacuation”. *SVOA Neurology* 2022, 3:5, 168-175.

Copyright: © 2022 All rights reserved by Eljili F., et al. This is an open access article distributed under the Creative Commons Attribution License, which permits unrestricted use, distribution, and reproduction in any medium, provided the original work is properly cited.