

# Adie's Pupil, Migraine, and Neurovascular Conflict of the III Nerve in a Young Patient. Case Report.

Ignacio Saguier Padilla<sup>1\*</sup>, Juan Cao<sup>1</sup>, Santiago Cutillier<sup>1</sup>, Carolina E. Siracusa<sup>1</sup>, Daniel Gestro<sup>1</sup>, Maria Figuerola<sup>1</sup> and Lidia Saroto<sup>2</sup>

<sup>1</sup> Neurology Department, Hospital de Clínicas José de San Martín, Buenos Aires, Argentina.

<sup>2</sup> Ophthalmology Division, Neuro-ophthalmology, Hospital de Clínicas José de San Martín, Buenos Aires, Argentina.

\*Corresponding Author: Ignacio Saguier Padilla, Residente de tercer año, Neurología, Hospital de clínicas José de San Martín, CABA, Argentina.

DOI: <https://doi.org/10.58624/SVOANE.2023.04.088>

Received: March 28, 2023 Published: April 20, 2023

## Abstract

The pathogenesis of Adie's pupil would be postganglionic parasympathetic dysfunction, with no defined cause. There are some case reports of its association with migraine. Few cases of anisocoria secondary to non-aneurysmal neurovascular conflict of the III pair due to preganglionic deficit with response to pilocarpine 0.125% have also been reported. We present the case of a patient with anisocoria, migraine without aura and neurovascular conflict, diagnosed with Adie's pupil.

**Keywords:** Adie's Pupil, Migraine, Neurovascular variant, III cranial nerve.

## Abbreviations

PCA: Posterior cerebral artery; ESR: Erythrocyte sedimentation rate ; PAN tc: Panoramic TC, P1: First portion Ach: Acetylcholine

## Introduction

Young patient with a history of recently diagnosed and untreated migraine without aura, who presented anisocoria days after the migraine episode without other associated symptoms. Neuroimaging was performed in which neurovascular conflict of the ipsilateral third nerve was evidenced, and a positive pilocarpine test. The picture was interpreted as Adie's pupil secondary to migraine with a finding of ipsilateral neurovascular conflict.

## Clinical Case

A 25-year-old female patient, with a personal history of recently diagnosed migraine without aura without preventive treatment, who consulted for detecting pupillary asymmetry in the mirror. He commented that he had suffered an episode of sudden, oppressive left-sided headache three days before, with an intensity of 10/10 and associated with photophobia. She denies nausea, vomiting, ptosis, or diplopia.

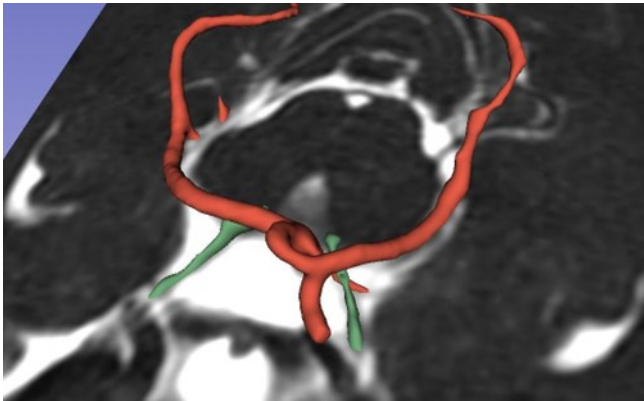
On physical examination, a mydriatic left pupil with an efferent defect and slight contraction in converging gaze was confirmed. Eye movements preserved. No alteration in any other cranial nerve. Visual acuity by Snellen test 10/10. He referred persistent left hemicrania's headache of intensity 9/10, throbbing, and photophobia of the left eye. He never had an aura.

Laboratory studies are requested with the following results: negative serologies (HIV, HBV, HCV, IgM toxoplasmosis, VDRL), ESR 8mm/sec. Lumbar puncture with physicochemical within normal parameters, cellularity of 1/mm<sup>3</sup>. Brain tomography with intravenous contrast that evidences variant of the birth of PCA. PANtc without particularities.

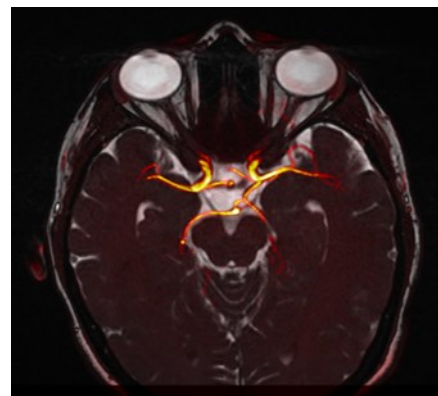
She was evaluated by neuro-ophthalmology, confirming an ocular fundus without pathological findings. In the 1.5 Tesla MRI with Angio resonance of intracranial vessels, it is reported that at the level of the P1 segment of the PCA there is a posterior communicating LOOP surrounding the left III nerve, and below the superior cerebellar in close relationship with it, with no evidence of aneurysms (Fig 1 and 2). The headache subsided with analgesics and metoclopramide, while the anisocoria associated with photophobia persisted. Suspecting Adie's pupil, a 0.125% pilocarpine test was performed, which was positive (Fig 3).

The condition was interpreted, in conjunction with neurosurgery and neuro-ophthalmology, as Adie's pupil associated with migraine without aura with a neurovascular conflict as a neuroimaging finding. It was decided to start amitriptyline 12.5 mg per day as preventive treatment.

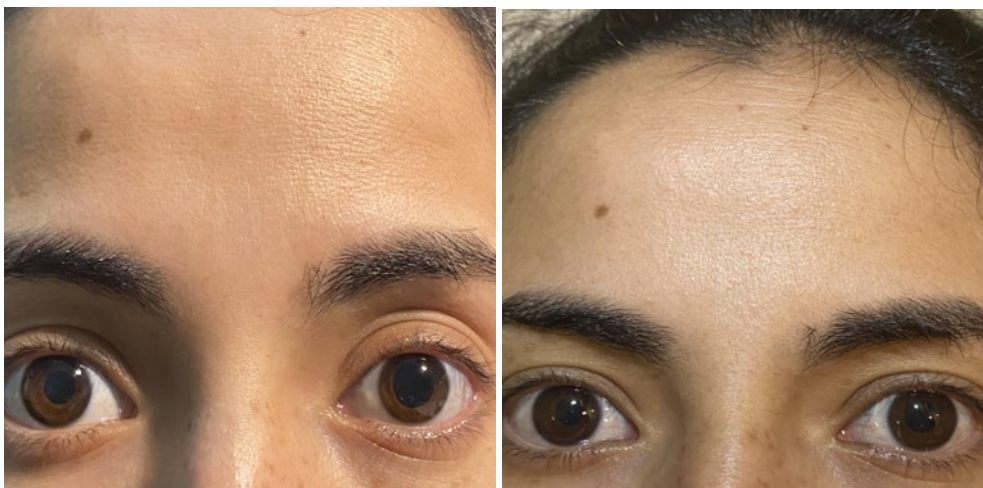Two months after hospital discharge, an outpatient follow-up reported improvement in the frequency and intensity of the headaches, but the photophobia secondary to anisocoria with the efferent pupillary defect persisted.



**Fig 1:** 3D reconstruction showing a posterior cerebral artery of transitional origin that contacts the third nerve. Below it there is close contact with the superior cerebellar artery.



**Fig 2:** Steady-state Acquisition (FIESTA) sequence with 3D TOF fusion showing vascular anatomical variant with LOOP of P1 segment of PCA that makes contact with the third nerve.



**Fig 3:** Pilocarpine test in left pupil. Pre and Post application.

## Discussion

The tonic or Adie's pupil is characterized by being a mydriatic pupil that is not reactive to light stimulation with slight contraction upon accommodation and great contraction upon the application of low-dose pilocarpine. It is more frequent in young women (20-40 years), monosymptomatic and transient, although it can last up to 36 months. Its pathophysiological basis is not entirely clear, but it is postulated that it would be secondary to damage to the postganglionic parasympathetic fibers, with an upgrade of the Ach receptors at the muscle level that generate an exaggerated response to low doses of the cholinergic agonist. This pupil can be part of syndromes such as Holmes-Adie Syndrome when it presents with generalized hyporeflexia, Ross Syndrome if it presents together with segmental anhidrosis, and Harlequin Syndrome when the anhidrosis is only hemifacial. Its association with giant cell arteritis, Sjogren's Syndrome, Paraneoplastic with Anti-Hu Antibodies and infections has been described. All of them were ruled out during hospitalization and despite the fact that paraneoplastic antibodies were not requested, it did not seem to be a suspected etiology in the patient and tcPAN was normal. Regarding migraine, there are few case reports of its association.(3,4,5,13)

In 1981 Massey described 22 patients with Adie's pupil and a history of migraine. Purvin, in 1995, described the first case of migraine and concomitant Adie's pupil. Since vasoconstriction occurs during a migraine attack, it is believed that the pathogenesis would be due to ischemia of the postganglionic parasympathetic fibers. Due to both the response to pilocarpine and the partial response to accommodation, and its transient nature (days to months), the term ganglioplegic ciliary migraine has been proposed for patients who present pupillary atony during or as a consequence of the headache episode. Some authors consider it as a variant of recurrent painful ophthalmoplegic neuropathy (NODR) or Ophthalmoplegic Migraine. In the case of our patient, she did not present ocular motility alterations, so this diagnosis is excluded. (1,2,3,9,10,12)

All the patients described up to now with Adie's pupil and migraine presented an anodyne neuroimaging. This is not the case of our patient, in whom a non-aneurysmal neurovascular conflict was evidenced. There are few reports in the literature of asymptomatic non-aneurysmal unilateral mydriasis. These are due to the presence of anatomical variants such as arterial LOOPs, fetal PCA or persistent trigeminal artery, due to compression of the pial vessels that injure the parasympathetic fibers of the nerve. However, cases of patients with these anatomical variants as a finding, who are asymptomatic, have also been reported. Based on what has been stated so far, the detection of these variants would have high sensitivity but low specificity. What is unusual and interesting about our patient is that she presented mydriasis after a maximum intensity migraine episode, but routine neuroimaging revealed an anatomical variant that could justify parasympathetic involvement. Even the pilocarpine test, which determines parasympathetic postganglionic involvement, can also be positive in long-standing preganglionic lesions of the III nerve, since the postganglionic ones are later compromised. In our case, since the pupillary asymmetry was found in the patient hours after presenting the headache episode, we are led to think that its pathogenesis would be related to concomitant migraine and not to a late manifestation of a possible neurovascular conflict. (6,7,8,11)

To date, we have not found another case in the literature presenting adie's pupil, migraine, and neurovascular conflict in the same patient. The final interpretation was a tonic pupil associated with migraine with the finding of a neurovascular anatomical variant.

## Conclusion

The presented case is interesting and infrequent, since although Adie's pupil and migraine are associated in various reports, proposed as ganglioplegic migraine as an entity, the presence of neurovascular conflict in the same patient made the final interpretation challenging.

## Conflict of interest

The authors declare no conflicts of interest.

## References

1. Adie 's tonic pupil secondary to migraine. Purvin VA J Neuro-ophthalmol. 1995;15:43-44.
2. Pupillary dysautonomia and migraine: is Adie's pupil caused by migraine? Massey EW. Headache. 1981; 21:143-146.
3. Status Migrainosus and Adie's Syndrome Daniel E. Jacome, MD Headache. 2002;42:793-795
4. Pupillary Dysautonomia and Migraine: Is Adie's Pupil Caused by Migraine? E. Wayne Massey, M.D.Headache 21:143-146, 1981
5. Adie's pupil during migraine attack: case report and review of literature Abbas Tafakhori, Vajihah AghAmollai, Amirhossein modAbbarniA, hossein PourmAhmoodiAn Acta Neurol. Belg, 2011, 111, 66-68

6. Mydriasis revealing vascular and osteodural compression of the oculomotor nerve: An observational study on five cases. F. Tréchet a,b, R. Tonnelet b,c , J.-B. Conart a ,F. Legouc , M. Braunb,c , K. Angioia 0181-5512/
7. The oculomotor neurovascular conflict: Literature review and proposal of management Francesco Belotti\*, Luca Zanin, Marco Maria Fontanella, Pier Paolo Panciani. doi.org/10.1016/j.clineuro.2020.105920
8. Computed Tomography and Magnetic Resonance Imaging Findings in Ophthalmoplegic Migraine Laura Miglio, MD\*, Paola Feraco, MD†, Giovanni Tani, MD\*, and Paolo Ambrosetto, MD† doi:10.1016/j.pediatrneurol.2010.02.005
9. Migraña con midriasis unilateral benigna o migraña ciliar gangliopléjica M. Marín Gracia doi.org/10.1016/j.neurop.2021.03.014
10. Ophthalmoplegic Migraine With Persistent Dilated Pupil Ine's Sobreira, Ca'tia Sousa, Ana Raposo, Fernando Fagundes, and Ana Isabel Dias, DOI: 10.1177/0883073812467255

**Citation:** Padilla IS, Cao J, Cutillier S, Siracusa CE, Gestro D, Figuerola M, Saroto L. Adie's Pupil, Migraine, and Neurovascular Conflict of the III Nerve in a Young Patient. Case Report. *SVOA Neurology* 2023, 4:2, 33-36.

**Copyright:** © 2023 All rights reserved by Padilla IS., et al. This is an open access article distributed under the Creative Commons Attribution License, which permits unrestricted use, distribution, and reproduction in any medium, provided the original work is properly cited.