

Effect of Vertical Cervical traction Combined with Conventional Neurodynamic Mobilization and SNAGs in an Individual with Neck Pain and Cervical Radiculopathy: A Case Report

Shilpa Vaishy^{1*} and Supriya Kondal²

¹ Orthopaedic Physiotherapy Fellow, Department of Sancheti physiotherapy, Sancheti Hospital, Shivajinagar, Pune - 411005, Maharashtra, India.

² Clinical head at Sancheti Physiotherapy Department, Department of Sancheti physiotherapy, Sancheti Hospital, Shivajinagar, Pune - 411005, Maharashtra, India.

*Corresponding Author: Dr. Shilpa Vaishy (PT), Department of Sancheti physiotherapy, Sancheti Hospital, Shivajinagar, Pune - 411005, Maharashtra, India.

Received: August 30, 2021 Published: September 16, 2021

Abstract

Neck pain is a common term which signifies any musculoskeletal disorders arising from the cervical spine region. Cervical radiculopathy falls under subgroup of neck disorders. Although the analgesic action of Vertical cervical traction, Conventional neurodynamic mobilization and SNAGs has been recognized in many studies, the effect of these can be applied simultaneously has not been previously investigated. Therefore, the objective of this study is to present the effect of Vertical cervical traction combined with Conventional neurodynamic mobilization and SNAGs on pain and disability in an individual with neck pain and Cervical radiculopathy. A 37-year-old male patient presented with a chief complaint of neck pain and right upper limb weakness for 3 months. He had tingling sensation on his right arm & forearm and numbness of medial half of middle, ring and little finger. Vertical cervical traction, conventional neurodynamic mobilization and SNAGs were applied to reduce patient's pain and disability measured at baseline and at 1 week using the Numeric Pain Rating Scale and Neck Disability Index. Outcome scores revealed that patient's pain, tingling and numbness had almost disappeared and able to perform his daily activities and job tasks without difficulties. In conclusion, the findings of this study support that the use of vertical cervical traction combined with conventional neurodynamic mobilization and SNAGs are beneficial in reducing pain and disability in an individual with neck pain and cervical radiculopathy.

Keywords: Vertical cervical traction, conventional neurodynamic mobilization, SNAGs, Cervical Radiculopathy

Introduction

Neck pain is a common term which signifies any musculoskeletal disorders arising from cervical spine region. Cervical radiculopathy falls under subgroup of neck disorders. It is defined as clinical description of when a nerve root in cervical spine becomes inflamed or impinged resulting changes in neurological functions such as numbness, altered reflexes, pins and needle sensation that may radiate from neck into shoulder, arm, hand or fingers. The commonest aetiology of cervical radiculopathy primarily results from an inflammation of cervical nerve root induced as a result of lesion that reduces the intervertebral foramen space.¹

The tendency to stay seated for prolonged periods is increasing as is proportion of population that uses smartphone or personal computer. This can produce changes in alignment of spine lead improper posture such as forward head posture caused by several factors like sleeping with head elevated too high, extended use of computers & cell phones and sitting at a desk for long time. Maintaining a continuous posture produces damage to ligaments around spine.²

Several researchers have reported that Cervical radiculopathy pain is caused by mechanical and chemical stimuli found around the cervical nerve roots. Presence of these stimuli around cervical nerve roots change their normal structure & function leading neural inflammation, hypoxia, ischaemia & limited gliding movement. Based on this, many manual therapy interventions have been suggested and consequently remove pain and disability caused by cervical radiculopathy.

Vertical cervical traction, Conventional neurodynamic mobilization and SNAGs have been used in treatment of cervical radiculopathy due to their instant pain relieving effect.

Cervical traction is applied to give pain inhibition, widening of cervical neural foramina & reduction of intradiscal pressure. Furthermore, conventional neurodynamic mobilization are used to normalize the cervical nerve root structure & function by possible reduction of nerve adherence, decreased neural mechanosensitivity & facilitation of nerve gliding.³

Mulligan described two neurodynamic mobilization techniques namely neurodynamic SNAGs and neurodynamic spinal mobilization with arm movement. In Neurodynamic SNAGs, affected arm is kept in neurodynamic test position just below pain limits while therapist delivers SNAGs at affected spinal level & patient is asked to actively perform painful neck movements. This is effective for radiating pain and cervical movements provoking the pain in affected nerve distribution.⁴

Although the analgesic action of Vertical cervical traction, Conventional neurodynamic mobilization and SNAGs has been recognized in many studies, the effect of these can be applied simultaneously has not been previously investigated. Therefore, the objective of this study is to present the effect of Vertical cervical traction combined with Conventional neurodynamic mobilization and SNAGs on pain and disability in an individual with neck pain and Cervical radiculopathy.

Case History

2.1. History

On June 8, 2021, a 37-year-old male patient presented with a chief complaint of neck pain and right upper limb weakness for 3 months with NPRS 8/10. He had tingling sensation on his right arm & forearm and numbness of medial half of middle, ring and little finger. Symptoms were reported as continuous tingling and numbness. Symptoms aggravated by certain neck (extension, ipsilateral rotation, lateral flexion), shoulder(abduction), elbow (full extension) & wrist (extension) movements. He had similar episodes of symptoms on and off for many years, but he neglected and tried to reduce symptoms by medications. There was no history of injury to neck. The patient was a software IT engineer. He had to work on his computer and used his mobile phone for an average 10-12hrs and 6-8hrs daily.

2.2. Examination findings

The systemic examination was grossly normal.

The observation of patient's posture in standing and during sitting at a computer revealed forward head posture.

Examination of bilateral upper trapezius(right side) revealed tenderness and spasm.

However, the motion of cervical spine was limited, especially on right side.

Neck movements		Normal ROM (in degrees)	AROM (in degrees)
Cervical Flexion		80-90	55
Cervical extension		70	30
Cervical side flexion	Right	20-45	20
	Left	20-45	35
Cervical rotation	Right	90	30
	Left	90	45

On neurological examination, C7-C8 dermatome demonstrated reduced light touch sensation. Decreased strength was noted for triceps (3/5), wrist flexors(4/5) and finger flexors(4/5) but triceps reflex was normal. Application of neck extension combined with ipsilateral rotation and lateral flexion exacerbated pain while application of neck flexion combined with contralateral rotation and lateral flexion was less painful.

The ULTT, Spurling and cervical distraction test were unilaterally positive for radicular pain on right side.

Tests	Positive	Negative
ULTT -Median nerve -Ulnar nerve -Radial nerve	Median nerve (right side)	-Ulnar nerve (left side) -Radial nerve (left side)
Spurling test	Right side	Left side
Cervical distraction test	Right side	Left side

2.3. Physiotherapeutic treatment plan

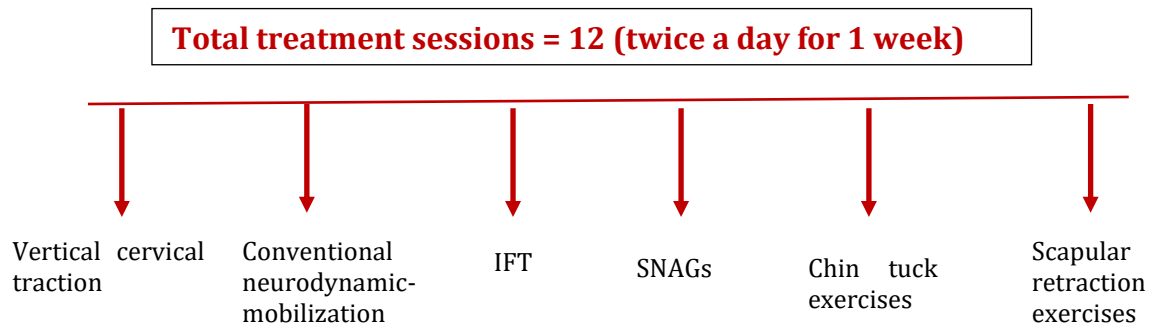
For treatment, it was planned to give vertical cervical traction, conventional neurodynamic mobilization, IFT, SNAGs, Chin tucks and Scapular retraction exercises.

Outcome measures were collected at baseline and at 1 week by using Numeric Pain Rating Scale & Neck Disability Index.

2.4. Procedure

The patient was asked to attend for 12 treatment sessions. At each session he was placed in a sitting position and give vertical cervical traction with 7kg weight of 1sec hold and 1sec rest time for 15mins. Conventional neurodynamic mobilization (median nerve) were given for 5-7 times in 3reps with shoulder depression and abduction 110°, elbow extension, forearm supination, wrist extension and finger and thumb extension, IFT with 15Hz sweep frequency for 15mins, SNAGs were given for 10reps of 3 sets, Chin tucks and Scapular retraction exercises for 10reps in sitting position. The total treatment time for each session was 45mins.

After 1 week, he reported that there was improvement in neck and shoulder pain & episodic tingling in right arm & forearm and numbness in medial half of middle, ring and little finger resolved completely. The cervical ROM became almost normal (neck extension became 70°, lateral bending improved 40° on both sides & rotation became 70° on right and 80° on left side). However, flexion did not improve to normal range but improved considerably from 60-65°. The ULTT, Spurling & Cervical distraction test all became negative, which were earlier positive on right side. Patient provided informed consent to publish this case study.



Results

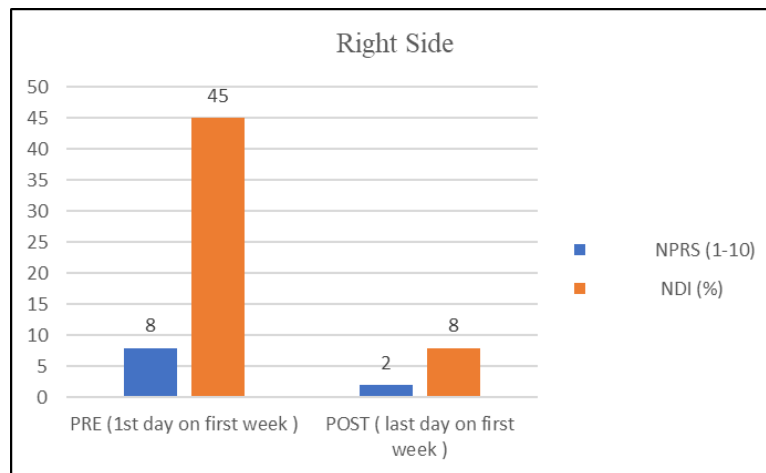
Initial evaluation: The results of outcome measures are presented in Table 1.

On NPRS, the patient score was 8. According to NDI questionnaire, the patient exhibited the severe degree of neck disability due to cervical radiculopathy. As a patient was software IT engineer, he was unable to work with a desktop for > 30mins. His daily activities and car driving were executed with a lot of difficulty.

Re-evaluation 1week post initial evaluation: Scores on NPRS and NDI had mostly all improved. Pain improved by approx.80%, tingling sensation on right arm & forearm and numbness on medial half of middle, ring and little finger disappeared. Thus, patient was able to perform the affected daily activities by approx.60% easier compared to last 1 week. His forward head posture was also corrected. There was significant decrease in NDI score indicating that the degree of his disability was reduced to last 1 week.

Table 1: Results of questionnaires related to Patient's Pain and Disability at initial evaluation and at 1week post initial evaluation.

Questionnaire	Initial evaluation	1 week post initial evaluation
NPRS (1-10)	8	2
NDI (%)	45	8

Graph 1:

Graph 1 shows NPRS and NDI on right side interprets that pain and disability scores were significantly reduced post intervention.

Discussions

The present case report study has looked at the effect of vertical cervical traction combined with Conventional neurodynamic mobilization and SNAGs in an individual with neck pain and cervical radiculopathy. Its findings demonstrated significant improvement in terms of pain and disability. At the end of 1st week, patient showed reduction in pain and disability scores.

Several imaging studies with the use of CT scans and MRI have revealed that cervical traction can increase intervertebral space leading to elongation of neural foramen and reduction of intradiscal pressure.³

SNAGs is a popular manual therapy technique, the exact mechanism by which it works is unknown. The rationale for technique was initially based on biomechanical explanation where repositioning of superior articular facet using a SNAGs would cause correction of positional fault thus resulting in reduction of pain and increased ROM in neck. Furthermore, the normal movement in articular surface is necessary for maintaining the mobility of adjacent nerves where the altered biomechanics can influence the nerve's excursion. Thus, restoration of normal mechanics at joint interface can normalize the adverse neurodynamics present as a result of limited joint movement. In this patient, after a SNAGs given at C6-C7 level, there were immediate improvements in cervical right rotation and ULNT-1 testing were noted which could be allocated to restoration of normal mechanics of spinal articular at facet joint.⁵

The reduction in pain intensity could be reduced that SNAGs develops a sympathoexcitatory effect helps to produce analgesic response in C5-C6.⁶ SNAGs reduces pain intensity significantly at last day of 1st week of intervention since SNAGs produces instant pain relieving effect due to pain gate theory by Mendell.⁷

As per result of the study, the effects of neural tissue mobilizations can be due to the fact that the sliding techniques result larger longitudinal excursion of nerve with minimal increase in strain on impinged nerve. The beneficial effects on hydration of nerve as it facilitates the evacuation of intra neural oedema when correctly applied and hence brings about a decrease in symptoms.⁸ In case study by Christos Savva et.al was found that cervical traction combined with neural mobilization significantly effective in improving pain and disability in a patient with cervical radiculopathy.³

The effect of mechanical intermittent cervical traction on decreasing neck & arm pain and neck disability in cervical radiculopathy is well-defined in previous studies done by Joghataei et al. 2004 and Cleland et al. 2005. The mechanism by which intermittent cervical traction reduces neck & arm pain is possibly by unloading the components of spine by stretching ligaments and muscles, nerve root decompression within central foramina and reducing adhesions within dura sleeve.⁹

Conclusion

This case study was concluded that the use of vertical cervical traction combined with conventional neurodynamic mobilization and SNAGs are beneficial in reducing pain and disability in an individual with neck pain and cervical radiculopathy.

Limitations

This is a case report of showing benefit of vertical cervical traction combined with Conventional neurodynamic and SNAGs in a single patient.

Future Scope

Study can be done with bilateral cervical radiculopathy patients.

Long term follow up of patients can be taken.

Using larger sample size.

Conflicts of Interest

None

Acknowledgment

The author thanks Dr. Supriya K for their assistance in this manuscript.

References

1. Langevin P, Roy JS, Desmeules F. Cervical radiculopathy: Study protocol of a randomized clinical trial evaluating the effect of mobilisations & exercises targeting the opening of intervertebral foramen. *BMC Musculoskelet disord* 2012;13(10):1-8.
2. Rattandeep Singh, Vinay Jagga and Sharanjeet Kaur. Effect of Combining Stretching and Strengthening Exercises of Neck Muscles in Forward Head Posture among Desk Job Operators. *AJORR* 2021;5(1):1-5.
3. Christos Savva, Giannis Giakas. The effect of cervical traction combined with neural mobilization on pain and disability in cervical radiculopathy. A case report. *Manual Therapy* 2013;5(18):443-446.
4. Shacklock M; *Clinical neurodynamics: a new system of musculoskeletal treatment*. Elsevier Butterworth-Heinemann, 2005.
5. Sudarshan Anandkumar. The effect of sustained natural apophyseal glide (SNAG) combined with neurodynamics in the management of a patient with cervical radiculopathy: a case report. *Physiother Theory Pract* 2015;31(2):140-145.
6. Moulston A. A preliminary investigation into the relationship between cervical SNAGS and sympathetic nervous system activity in the upper limbs of asymptomatic Population. *Manual therapy* 2006(11);214-224.
7. Mendell LM. Constructing and deconstructing the gate theory of pain. *J Neurophysiol morphologic and neurophysiologic effects*. *Spine* 2014;22(9):946-957.
8. Dilley A, Lynn B, Greening J, DeLeon N. Quantitative in vivo studies of median nerve sliding in response to wrist, elbow, shoulder and neck movements. *Clinical Biomechanics*. 2003;18(10):899-907.
9. Sharma et al, effectiveness of TENS versus intermittent cervical traction in patients with cervical radiculopathy. *Int J Physiother Res* 2014;2(6):787-92.

Citation: Vaishy S, Kondal S. "Effect of Vertical Cervical traction Combined with Conventional Neurodynamic Mobilization and SNAGs in an Individual with Neck Pain and Cervical Radiculopathy: A Case Report". *SVOA Orthopaedics* 1:1 (2021) Pages 10-14.

Copyright: © 2021 All rights reserved by Vaishy S. This is an open access article distributed under the Creative Commons Attribution License, which permits unrestricted use, distribution, and reproduction in any medium, provided the original work is properly cited.