

# Hybrid Posterior Instrumentation and Mini-Open Anterior Release for Treatment of Adolescent Idiopathic Scoliosis: A Retrospective Analysis

Charanjit Singh Dhillon<sup>1\*</sup>, Nilay Chhasatia<sup>1</sup>, Rishi Dwivedi<sup>1</sup> and Vijay Loya<sup>1</sup>

<sup>1</sup>MIOT International, Hospital in Chennai, Tamil Nadu, India.

\*Corresponding Author: Dr. Charanjit Singh Dhillon, MIOT International, Chennai, India.

Received: August 25, 2021 Published: September 23, 2021

## Abstract

**Objective:** A retrospective analysis of the role of hybrid instrumentation, mini-open anterior release in the treatment of adolescent idiopathic scoliosis.

**Methods:** Medical records and imaging of 43 patients operated between January 2008 to June 2014 were retrospectively analyzed. Subgroup analysis was done for patients managed with mini-open anterior release+ posterior instrumentation [APSF] (13 patients) vs. all posterior approach [PSF] (30 patients). Hybrid instrumentation was used involving the use of hooks and sublaminar wires in conjunction with pedicle screws. A mini open thoracotomy (<10 cm incision) was used for anterior release. The free-hand technique was used to insert all the pedicle screws. Stagnara wake up test was used after correction manoeuvres. Appearance scores were collected before and after the surgery.

**Results:** The mean age of operated cases was 15.2 (range 10-28) years, and majority cases were females (86.05%). The average follow-up time was 46.86 months. Lenke 1 was the most common curve pattern [74.42%]. Significant correction was achieved and maintained at the end of the follow-up period for all the curve patterns [PT 66.67%, MT 75.20%, DL/L – 70.83%]. The sagittal plane alignment was maintained in all but one patient. Mean [81.25° vs. 49.16°] and bending [66.89° vs. 32°] Cobb angles were significantly higher in the APSF group. Improvement in the appearance scores was significant for both the groups [APSF - 25 vs. 10.78, PSF - 18.9 vs. 9.03]. Two of the APSF patients had prolonged ICU stay. Two patients required secondary suturing for wound dehiscence. One case had chylothorax, which was medically managed. One patient required revision surgery for hook pull-out after 34 months of index surgery. There were no neurological deficits, vascular or visceral injuries.

**Conclusion:** Adolescent idiopathic scoliosis represents a different set of challenges in developing nations with limited resources. Hybrid instrumentation with the use of sublaminar wires is still an effective and valid strategy to reduce the cost of spinal deformity surgeries. A mini-open anterior release, along with the use of posterior hybrid instrumentation, helps achieve optimal coronal and sagittal correction, especially in bigger and stiffer curves, compared to all posterior hybrid constructs. A decision tree is provided to guide the treatment selection for the adolescent idiopathic scoliosis cases.

**Abbreviations:** PT- Proximal Thoracic, MT – Main Thoracic, DL/L – Dorsolumbar/ Lumbar

**Keywords:** Adolescent idiopathic scoliosis, hybrid instrumentation, anterior release, posterior approach, spinal deformity, pedicle screws, sublaminar wires

## Introduction

Idiopathic scoliosis, a three-dimensional deformity is the most common structural spinal deformity among adolescents. While the prevalence of curves with a Cobb angle of more than 10 degrees is 1-4% in children aged 10-16 years, only around 10% of these patients progress to more severe deformity requiring intervention(1,2). While cosmetic appearance is the most common reason for seeking treatment, other complaints such as pain and symptoms related to pulmonary restriction become more common as the severity of curves increase. The awareness efforts and school screening programs have yet to become common in developing countries, and as a result, more extensive and stiffer curves are frequently encountered.

Similarly, newer imaging modalities such as the 3-dimensional CT-scan and EOS are not readily available, and the whole spine x-ray remains the gold standard for assessment and treatment planning of the spinal deformities(3).

Progressive curves, significant deformity (Cobb's>50°), mechanical back pain, thoracic kyphosis leading to respiratory restriction and unappealing cosmetic appearance necessitate operative treatment in adolescent idiopathic scoliosis. While optimally balanced correction, successful fusion, and improvement of aesthetic appearance remain common goals of any operative strategy, employment of a specific surgical plan, such as an anterior, a posterior, or a combined approach, remains the surgeon's preference(2). Similarly, the choice of an all pedicle screw construct or a hybrid construct is dictated not only by the operating surgeon's comfort and patient's anatomy but by the economic constraints, especially in developing countries.

The authors report their experience with anterior release and hybrid instrumentation in adolescent idiopathic scoliosis patients and present a decision tree to guide the treatment approach.

**Study Design:** Retrospective analysis.

## Methods

A total of 56 patients underwent deformity correction for adolescent Idiopathic scoliosis during the period of January 2008 to June 2014 at our institute. Of these, the patients with at least two years or more of regular follow-up were included in the study (n=43). A total of thirteen patients were excluded, of which nine patients had incomplete evaluation details, and four lacked adequate follow-up. All the clinical records and radiological images were analyzed retrospectively.

All the patients underwent long cassette standing coronal and sagittal radiographs and supine side-bending radiographs. Computerized tomographic (CT) scans with pedicle sizing were obtained to assess the morphometry of pedicles. Clinical evaluation and magnetic resonance imaging were done to rule out intraspinal malformations.

The treatment plan was decided depending on the severity and rigidity of the curve, as documented in the decision tree (Fig.1). The indications for operative treatment are summarized (Table.1). Based on the approach utilized for deformity correction, patients were divided into groups APSF [anterior release + posterior instrumentation, deformity correction and fusion], and PSF [all posterior instrumentation, deformity correction, and fusion]. For group APSF, an uninstrumented anterior release of around 4-5 apical discs depending on the curve magnitude and stiffness was performed through a mini-open thoracotomy, followed by posterior instrumentation and deformity correction. For a mini open thoracotomy, an incision of less than 10 cms was used when compared to an open thoracotomy where the incisions usually measure 15-20cms. Mini open thoracotomy has a less detrimental effect on pulmonary function compared to open Thoracotomy. The mini open thoracotomy incision is taken on the convex side of the curve over the apical region. PSF patients underwent instrumentation and deformity correction through an all-posterior approach. Hybrid instrumentation was used involving the use of hooks and sub-laminar wires in conjunction with pedicle screws. Pedicle screws were used at the distal end of the construct, pedicle screws and hooks at the proximal end and sub-laminar wires in between. All the pedicle screws were inserted using the free-hand technique. The Stagnara wake-up test was utilized following major deformity correction maneuvers. Neuromonitoring and navigation were not used due to a lack of availability. Standing anteroposterior and lateral radiographs were taken at an immediate post-operative period, 3 weeks, 6 weeks, 3 months, 6 months, and then at yearly intervals. The follow-up period was defined as an interval from the time of surgery to the last OPD visit. Patients with a minimum follow-up of 2 years were included in the study.

**Table 1**

Indication for Deformity Correction	N	Percentage(%)
Cobb's >50°	26	57.44%
Documented Progression of Curve	11	27.66%
Unacceptable Cosmetic Appearance	6	14.9%
Total	43	100%

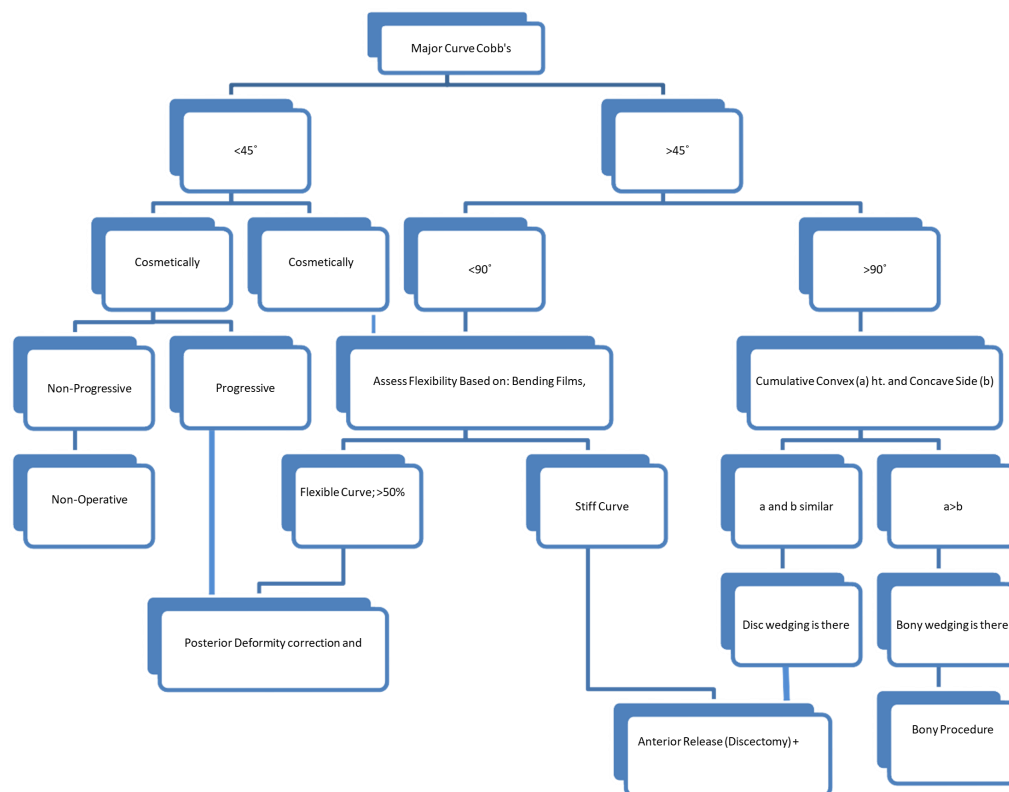


Fig. 1: Decision Tree

**Results**

A total of 43 patients were included in the study, with a mean age of 15.2 years (range 10-28 years). The majority of the patients were females (n=37, 86.05%). Lenke 1(main thoracic, MT) was the most common curve pattern noted (n=32, 74.42%). Of these, the most common subtype was 1A, followed by 1AN. Lenke 2 (double thoracic, DT) curve pattern was noted in 1 (2.32%) patient, while 3(6.98%) patients presented with a Lenke 3 curve (double major, DM) and one patient (2.32%) presented with a Lenke 4 (triple major, TM) curve. There were 6 patients (13.95%) with a Lenke 5 (thoracolumbar/lumbar, DL/L) curve pattern. None of the patients had Lenke 6 curve pattern (Fig. 2). The type A lumbar spine modifier was seen in 24 (55.81%) patients, while type B was seen in 9 patients (20.83%). A total of 10 (23.26%) patients had a type C lumbar modifier. A total of 20 patients (46.51%) presented with thoracic hypokyphosis (-), while 19 patients (44.19%) had a normal thoracic kyphosis. A positive thoracic kyphosis modifier was noted in 4 (9.3%) patients.

The mean follow-up period was 46.8 months. A coronal plane correction was maintained in all patients at the final follow-up (Table 2). A significant correction was achieved and maintained at the end of the follow-up period for all the curve patterns [PT 66.67%, MT 75.20%, DL/L 70.83%]. The sagittal plane alignment was maintained in all but one patient (2.32%). Hook pullout from the upper instrumented vertebra (D3) was noted at 34 months follow-up in one patient necessitating the removal of a displaced hook.

Table 2

	Proximal Thoracic (Structural)	Main Thoracic (Structural)	Dorsolumbar/Lumbar (Structural)
n=	2	37	10
Pre-Op Cobb's (Mean)	45°	55.92°	50.4° (± 15.18)
Bending Cobb's (Mean)	34°	40.18°	38.4° (± 14.61)
Correction on Bending	11°	15.76°	12°
Mean Post-Op Cobb's	15°	13.87°	14.7° (± 17.23)
Post-op Correction	66.67%	75.20%	70.83%
		P<.05	P<.05

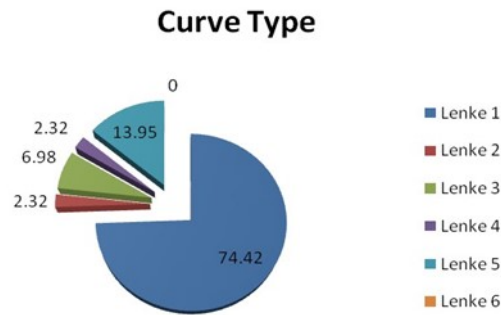


Fig. 2: Curve Patterns

**Posterior Surgery Vs. Posterior and Anterior Surgery**

Mean age at the time of deformity correction was significantly higher in APSF ( $16.25^{\circ} \pm 1.98^{\circ}$  vs.  $14.33^{\circ} \pm 2.9^{\circ}$ ,  $P=0.045$ ). Mean [81.25° vs. 49.16°] and bending [66.89° vs. 32°] Cobb angles were significantly larger in the APSF group. The number of operated levels was significantly higher in APSF vs. PSF ( $11.23^{\circ} \pm 2.19$  vs.  $14.38^{\circ} \pm 3.46$ ).

**Appearance Score:** As cosmetic appearance is the most common reason for seeking surgical treatment(2), a patient’s post-operative appearance directly correlates with the patient’s and the parent’s satisfaction following surgery. Since social and cultural aspects precluded the complete spinal assessment questionnaire (SAQ) in most of our patients, an appearance scoring was done by an independent observer not directly related to the study. A patient’s pre-operative and post-operative appearance was compared to the standardized drawings (Fig. 3) used in SAQ12(4). Patients were assessed on seven points: body curve, rib prominence, flank prominence, head chest hip, the position of head over the hip, shoulder prominence, and spine prominence. For each aspect, patients were ordinaly graded from 1 to 5; grade 1 being a normal appearance and grade 5 being the most severe deformity. A cumulative score was taken for the comparison, with the worst possible score being 35 and a score of 7 designating a normal appearance.

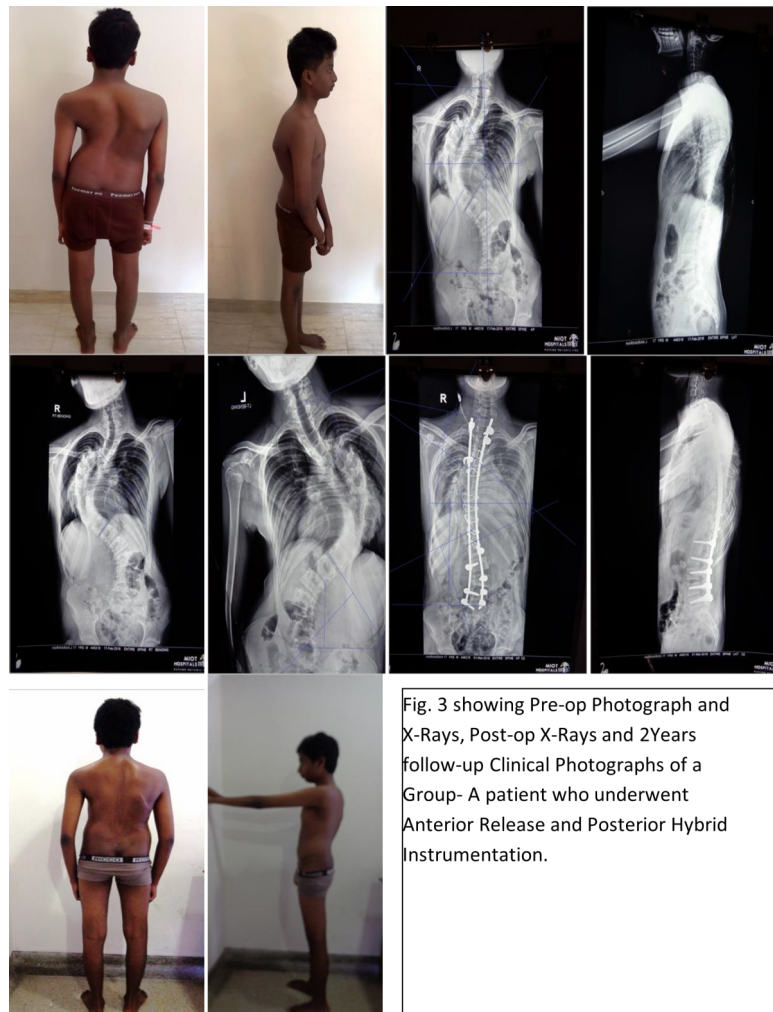


Fig. 3 showing Pre-op Photograph and X-Rays, Post-op X-Rays and 2Years follow-up Clinical Photographs of a Group- A patient who underwent Anterior Release and Posterior Hybrid Instrumentation.

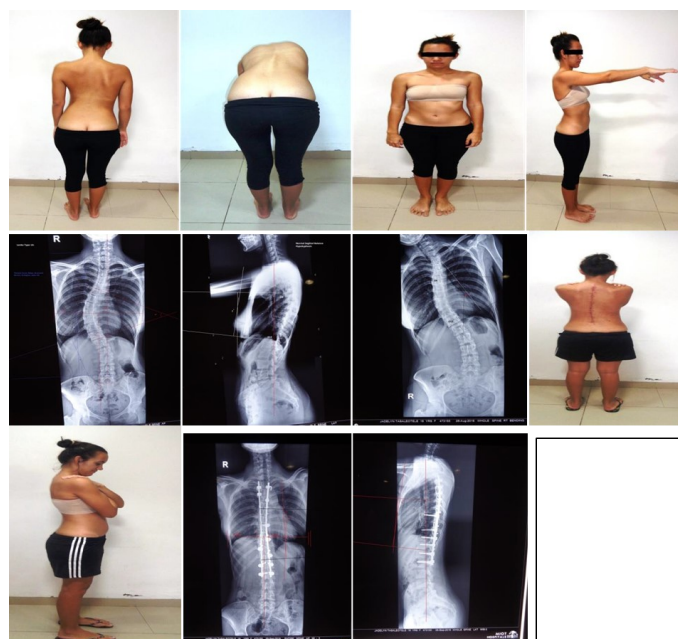**Table 3**

	Posterior Deformity correction alone (PSF)	Anterior Release+ Posterior Deformity Correction (APSF)	Significance
	N=30	N=13	
Age	14.33 (± 2.9)	16.25 (± 1.98)	P = .045
Mean Cobb's	49.16° (±12.91)	81.25° (± 31.40)	P< .00001
Bending Cobb's	32° (± 9.61)	66.89° (±24.56)	p< .00001
Pre-op Appearance Score	18.9 (± 4.32)	25 (± 5.31)	P= .00057
Post-op Cobb's	9.23 (± 6.25)	28.3 (± 20.48)	P= .5
Instrumented Levels	11.23 (± 2.19)	14.38 (± 3.46)	P= .0015
Post-op Appearance Score	9.03 (± 1.63)	10.78 (± 1.92)	P= .005

**Table 4**

	Pre-op Appearance Score	Post-op Appearance Score	
Mean	19.77	9.30	T -17.9 P<.00001
±	5.25	1.81	

A significant improvement in appearance score was noted following surgery (Table 4). The appearance score improved from a mean pre-operative score of 19.77 ± 5.25 to 9.30 ± 1.81 post-operatively. The mean appearance score of the APSF group improved from 25 ± 5.31 to 10.78 ± 1.92. The patients in the PSF group improved from a mean pre-op appearance score of 18.9 ± 4.32 to (9.03 ± 1.63) following deformity correction. The pre-operative mean appearance score in the APSF group was significantly higher than in the PSF group (p=0.005).



**Fig. 4:** Showing Pre- op Photograph and X-Rays, Post-op X- Rays and Clinical Photographs of a Group- B patient who underwent Posterior Hybrid instrumentation.



At follow-ups, patients were scrutinized to rule out pseudoarthrosis. Patients reporting increasing back pain (n=3, 6.98%), perception of increasing deformity, sudden popping sensation in back (n=1, 2.33%), underwent CT scan evaluation. Pseudoarthrosis was suspected in the presence of implant failure, a halo around screws, absence of bridging bone, loss of correction, and progression of the deformity. None of the patients in our series had a documented pseudoarthrosis.

**Complications:** Two of the APSF patients had prolonged ICU stay. Two patients, one from each group, both being posterior incisions, required secondary suturing for wound dehiscence. One case had chylothorax, which was medically managed. No pseudoarthrosis was encountered. One patient required revision surgery for hook pull-out after 34 months of index surgery, however solid fusion mass was noted intra-operative. There were no neurological deficits, vascular or visceral injuries.

## Discussion

Medical treatment of idiopathic scoliosis has been recognized since the time of Hippocrates and has evolved significantly since Hibbs' early attempts at uninstrumented fusion followed by long-term casting and Risser's seminal identification of the radiological markers of skeletal growth(5). While non-operative treatment, with an ever-expanding array of braces, have been tried over the last few decades; surgical correction has been the mainstay for larger and progressive curves (2,5,6). With the modern era of segmental pedicle screw-based deformity correction and fusion, the complications such as pseudoarthrosis and flat back, the bane of historical treatments, have been minimized. However, pedicle screws present with their own set of complications, such as neurological and visceral injury, junctional failures, and implant breakage(7,8). While the evolution of the freehand technique(9) and recently, navigation has reduced the surgical time, the cost of implants remains a significant factor in developing countries.

The efficiency of surgical correction of idiopathic scoliosis has been extensively reported in the literature. Lehman et al., in their study of 114 patients, achieved an average curve correction of 72.1% for MT, 50.7% for PT, and 67.5% for the DL/L curves(10). Similarly, Suk et al., in their series of 203 patients with AIS obtained an average of 69% of correction for the MT and 66% correction for the DL/L curves(11). Our correction profile in PT (66.7%), MT (75.02%), and the DL/L(70.83%) curve patterns affirm the effectiveness of surgical correction.

However, the strategy to achieve optimal correction remains a surgeon's preference, and the consensus regarding whether to utilize and isolated anterior or posterior approach or a combination thereof is still developing. Larger Cobb's angles ( $\geq 80^\circ$ ), diminished curve flexibility (side bending Cobb's  $>50^\circ$ ) and significant sagittal plane decompensation have been described as indications for an anterior release prior to anterior/ posterior instrumentation to achieve the optimal correction (12-14). Luhmann et al. reported greater intraoperative ( $48.3^\circ$  vs.  $31.7^\circ$ ) and final overall ( $47.2^\circ$  vs.  $34.2^\circ$ ) correction of thoracic curves between  $70^\circ$  to  $90^\circ$  with APSF(15). Minimally invasive thoracoscopic approaches to perform anterior release have been described to reduce the morbidity associated with traditional anterior approaches. In their series of 21 patients with a mean pre-op curve of  $82^\circ$  (Range:  $41^\circ$ -  $125^\circ$ ) Lenke et al. achieved an average post-op Cobb angle of  $28^\circ$  (Range  $5^\circ$ - $60^\circ$ ) with an anterior endoscopic release prior to PSF(14). Recently, Hsu et al. have published their experience with uniportal video-assisted thoracoscopic surgery [UniVATS] in achieving anterior release while minimizing operative time ( $75 \pm 13$  mins) and ICU stay ( $0.3 \pm 0.7$  days). An open thoracotomy involves an incision of around 15-20cms while a mini open thoracotomy involves an incision of around 7.5-10cms, thereby decreasing the pulmonary morbidity. We utilized this mini-open anterior approach with prolonged ICU stay in two of the patients being the only adverse consequence (16).

While the anterior release allowed us to achieve a similar magnitude of deformity correction in spite of larger and more rigid curves, the difference in the absolute average post-operative Cobb angle between the groups was not statistically significant ( $9.23^\circ \pm 6.25^\circ$  (PSF) vs.  $28.3^\circ \pm 20.48^\circ$  (APSF)). Despite all the radiological parameters being worse in the APSF group, both pre and postoperatively, the slightly worse appearance scores in the APSF group were not clinically significant ( $9.03$  PSF vs.  $10.78$  APSF). The overall improvement in appearance scores ( $19.77 \pm 10.50$  to  $9.30 \pm 3.62$ ,  $p < 0.05$ ) in all the patients, before and after the surgery, was significant. These findings have been reported by multiple studies and might be a consequence of higher pre-operative curves being taken up for anterior release.(10,12,14,17).

### Hybrid Instrumentation in Scoliosis Surgery:

Over the last hundred years, the goal of surgical treatment of scoliosis has been the same; to achieve sound multi-segmental spinal fusion with optimal correction. The early non-instrumented fusion and long-term casting efforts, spearheaded by Hibbs and subsequently Risser and colleagues, resulted in unacceptable morbidities such as skin reactions, intestinal obstruction, and pseudoarthrosis. After world war II, Paul Harrington ushered in the new era of rigid multi segmental internal fixation with concave distraction over the eponymous steel rod and hook construct(6,18). The lesson of resulting flat-back was learned over the intervening decades until a new era was ushered in by Luque with the introduction of sub-laminar wires attached to the trolley system. This was a non-rigid mono-column segmental fixation, and fusion rates improved. Finally, Roy-Camille helped bring the concept of three-column stable segmental fixation with pedicle screws in the 1960s. Subsequently, Cotrell and Dubousset incorporated the use of pedicle screws, hooks, rods, and transverse connectors—a framework of armamentarium on which multiple systems have consequently improved upon(6).

However, the concerns with pedicle screws such as neurological/visceral injuries, hardware failure, and radiation exposure required a demanding skillset(8,19). These concerns were compounded with deformed scoliotic pedicles. Suk and colleagues are credited with being among the first to report the safety of pedicle screw instrumentation in the thoracic spine in scoliosis cases(20). Subsequently, widespread adoption of the pedicle screws for three-column fixation in the developed nations has made the all-pedicle screw construct a standard of care.

Multiple studies have shown that the all-pedicle screws construct, in conjunction with posterior based soft-tissue and bony releases, provides optimal correction in most cases and obviates the need of anterior release(10,12,17,21,22). However, a closer look at the literature reveals that the same is not correct when an all-pedicle screw construct is not feasible. Luhmann et al. reported that while not significant when compared to the all-pedicle screw construct, anterior release resulted in better coronal correction compared to PSF in cases with hybrid instrumentation(15). Yilmaz et al., in their study of 105 AIS patients operated with PSF approach, reported that a hybrid construct with pedicle screws yielded better correction compared to a hook only construct(23). In developing countries, the prohibitive cost of implants, combined with the economic constraints of the patients, rule out an all-pedicle screw construct in most cases. In this scenario, a surgeon has to be aware of the alternatives to ensure that the optimal deformity correction is achieved and maintained. Also, pedicle fixation might not be possible due to small pedicle diameters (<5mm), dysplastic pedicles, pedicle perforation, or in very large curves [ $>100^\circ$ ]. Lack of availability of navigation and neuromonitoring also increases the chances of an adverse event related to pedicle screws.

Stainless steel (SS) wires are inexpensive and can be safely anchored to laminae at all levels and, in case of the lumbar spine, to the pars interarticularis too. They are especially useful for mobilization of the apex of the curve in hybrid constructs. While there is a possibility of neurological injury with the sub-laminar passage of wires, with sound technique, it is uncommon(24). Meticulous surgical technique and use of hemostatic agents can minimize the epidural bleeding. Cheng et al. compared the pedicle screws and apical sublaminar wires for correction of AIS in 50 patients and found similar average major curve corrections (67.4% SS wire vs. 68.1% pedicle screws)(25). In a similar study, Crawford et al. reported similar coronal correction for significant curves in the screw group vs. hybrid instrumentation group. However, they reported better sagittal profile correction with hybrid instrumentation. Chaiyamongkol et al. reported an average correction of 71.1% at 3.4 years with apical sublaminar wires across all the Lenke subtypes comparable to published literature on all-pedicle screw constructs. They also reported harmonious sagittal plane correction even in the presence of pre-existing thoracic hypokyphosis and fewer junctional kyphosis related complications. They did not report any neurological complications with the use of SS wires(26).

All our cases utilized hybrid instrumentation. In 39(90.70%) patients, hooks were used proximally, and sublaminar SS wires were used at the apex and periapical region to mobilize the apex, while pedicle screws were used at the base of the construct. In the remaining four patients, pedicle screws were used at the upper instrumented vertebra. We achieved a significant coronal plane curve correction of the major and secondary curves (Table.2) and did not have any neurological complications.

Proximal and, to a lesser extent, distal junctional failure, remain significant concerns with the use of pedicle screws despite of meticulous technique and preservation of facet capsules and posterior ligament complex at the end of constructs(27,28). The use of transverse process hooks at the upper instrumented vertebra in a claw configuration reduces the incidence of junctional failure(28). However, hooks at the proximal junction can dislodge or become prominent. One (2.56%) of our patients presented 34 months following index procedure with implant prominence as a result of left side hook dislodgement requiring re-surgery and removal of the prominent implant. In their retrospective series of 52 patients, Di Silvestre et al. reported a higher incidence of dural perforations and screw misplacements in screw-only constructs (44.0%) vs. Hybrid constructs (25.9%). They reported similar radiological and clinical results in all-screw vs. hybrid constructs (22).

## Conclusion

Adolescent idiopathic scoliosis represents a different set of challenges in developing nations with limited resources. Hybrid instrumentation with the use of sublaminar wires is still an effective and valid strategy to reduce the cost of spinal deformity surgeries. A mini-open anterior release, along with the use of posterior hybrid instrumentation, helps achieve optimal coronal and sagittal correction, especially in bigger and stiffer curves, compared to all posterior hybrid constructs. A decision tree is provided to guide the treatment selection for the adolescent idiopathic scoliosis cases.

## References

1. Fong DYT, Lee CF, Cheung KMC, Cheng JCY, Ng BKW, Lam TP, et al. A meta-analysis of the clinical effectiveness of school scoliosis screening. *Spine*. 2010 May 1;35(10):1061–71.
2. Weinstein SL. The Natural History of Adolescent Idiopathic Scoliosis. *J Pediatr Orthop*. 2019 Jul;39(Issue 6, Supplement 1 Suppl 1):S44–6.
3. Langensiepen S, Semler O, Sobottke R, Fricke O, Franklin J, Schönau E, et al. Measuring procedures to determine the Cobb angle in idiopathic scoliosis: a systematic review. *Eur Spine J Off Publ Eur Spine Soc Eur Spinal Deform Soc Eur Sect Cerv Spine Res Soc*. 2013 Nov;22(11):2360–71.

4. Sanders JO, Harrast JJ, Kuklo TR, Polly DW, Bridwell KH, Diab M, et al. The Spinal Appearance Questionnaire: results of reliability, validity, and responsiveness testing in patients with idiopathic scoliosis. *Spine*. 2007 Nov 15;32(24):2719–22.
5. Khan MJ, Srinivasan VM, Jea AH. The History of Bracing for Scoliosis. *Clin Pediatr (Phila)*. 2016 Apr;55(4):320–5.
6. Hasler CC. A brief overview of 100 years of history of surgical treatment for adolescent idiopathic scoliosis. *J Child Orthop*. 2013 Feb;7(1):57–62.
7. Floccari LV, Larson AN, Crawford CH, Ledonio CG, Polly DW, Carreon LY, et al. Which Malpositioned Pedicle Screws Should Be Revised? *J Pediatr Orthop*. 2018 Feb;38(2):110–5.
8. Suk SI, Kim WJ, Lee SM, Kim JH, Chung ER. Thoracic pedicle screw fixation in spinal deformities: are they really safe? *Spine*. 2001 Sep 15;26(18):2049–57.
9. Fichtner J, Hofmann N, Rienmüller A, Buchmann N, Gempt J, Kirschke JS, et al. Revision Rate of Misplaced Pedicle Screws of the Thoracolumbar Spine—Comparison of Three-Dimensional Fluoroscopy Navigation with Freehand Placement: A Systematic Analysis and Review of the Literature. *World Neurosurg*. 2018 Jan;109:e24–32.
10. Lehman RA, Lenke LG, Keeler KA, Kim YJ, Buchowski JM, Cheh G, et al. Operative treatment of adolescent idiopathic scoliosis with posterior pedicle screw-only constructs: minimum three-year follow-up of one hundred fourteen cases. *Spine*. 2008 Jun 15;33(14):1598–604.
11. Suk S-I, Lee S-M, Chung E-R, Kim J-H, Kim S-S. Selective thoracic fusion with segmental pedicle screw fixation in the treatment of thoracic idiopathic scoliosis: more than 5-year follow-up. *Spine*. 2005 Jul 15;30(14):1602–9.
12. Arlet V, Jiang L, Ouellet J. Is there a need for anterior release for 70-90 degrees masculine thoracic curves in adolescent scoliosis? *Eur Spine J Off Publ Eur Spine Soc Eur Spinal Deform Soc Eur Sect Cerv Spine Res Soc*. 2004 Dec;13(8):740–5.
13. Cheng MF, Ma H-L, Lin H-H, Chou P-H, Wang S-T, Liu C-L, et al. Anterior release may not be necessary for idiopathic scoliosis with a large curve of more than 75° and a flexibility of less than 25. *Spine J Off J North Am Spine Soc*. 2018;18(5):769–75.
14. Lenke LG. Anterior endoscopic discectomy and fusion for adolescent idiopathic scoliosis. *Spine*. 2003 Aug 1;28(15 Suppl):S36–43.
15. Luhmann SJ, Lenke LG, Kim YJ, Bridwell KH, Schootman M. Thoracic adolescent idiopathic scoliosis curves between 70 degrees and 100 degrees: is anterior release necessary? *Spine*. 2005 Sep 15;30(18):2061–7.
16. Hsu C-M, Wu K-W, Lin M-W, Kuo KN, Chang J-F, Wang T-M. Pioneering Experience of Uniportal Video-Assisted Thoracoscopic Surgery for Anterior Release of Severe Thoracic Scoliosis. *Sci Rep*. 2020 Jan 21;10(1):841.
17. Hero N, Vengust R, Topolovec M. Comparative Analysis of Combined (First Anterior, Then Posterior) Versus Only Posterior Approach for Treating Severe Scoliosis: A Mean Follow Up of 8.5 Years. *Spine*. 2017 Jun 1;42(11):831–7.
18. Harrington PR. Treatment of scoliosis. Correction and internal fixation by spine instrumentation. *J Bone Joint Surg Am*. 1962 Jun;44-A:591–610.
19. Chen G, Li H, Li F, Chen W, Chen Q. Learning curve of thoracic pedicle screw placement using the free-hand technique in scoliosis: How many screws needed for an apprentice? *Eur Spine J*. 2012;21(6):1151–6.
20. Suk SI, Lee CK, Kim WJ, Chung YJ, Park YB. Segmental pedicle screw fixation in the treatment of thoracic idiopathic scoliosis. *Spine*. 1995 Jun 15;20(12):1399–405.
21. Burton DC, Sama AA, Asher MA, Burke SW, Boachie-Adjei O, Huang RC, et al. The treatment of large (>70 degrees) thoracic idiopathic scoliosis curves with posterior instrumentation and arthrodesis: when is anterior release indicated? *Spine*. 2005 Sep 1;30(17):1979–84.
22. Di Silvestre M, Bakaloudis G, Lolli F, Vommaro F, Martikos K, Parisini P. Posterior fusion only for thoracic adolescent idiopathic scoliosis of more than 80 degrees: pedicle screws versus hybrid instrumentation. *Eur Spine J Off Publ Eur Spine Soc Eur Spinal Deform Soc Eur Sect Cerv Spine Res Soc*. 2008 Oct;17(10):1336–49.
23. Yilmaz G, Borkhuu B, Dhawale AA, Oto M, Littleton AG, Mason DE, et al. Comparative analysis of hook, hybrid, and pedicle screw instrumentation in the posterior treatment of adolescent idiopathic scoliosis. *J Pediatr Orthop*. 2012 Aug;32(5):490–9.
24. Girardi FP, Boachie-Adjei O, Rawlins BA. Safety of sublaminar wires with Isola instrumentation for the treatment of idiopathic scoliosis. *Spine*. 2000 Mar 15;25(6):691–5.



25. Cheng I, Kim Y, Gupta MC, Bridwell KH, Hurford RK, Lee SS, et al. Apical sublaminar wires versus pedicle screws-- which provides better results for surgical correction of adolescent idiopathic scoliosis? *Spine*. 2005 Sep 15;30(18):2104-12.
26. Chaiyamongkol W, Klineberg EO, Gupta MC. Apical wiring technique in surgical treatment of adolescent idiopathic scoliosis: the intermediate outcomes between Lenke types. *J Spinal Disord Tech*. 2013 Feb;26(1):E28-34.
27. Arlet V, Aebi M. Junctional spinal disorders in operated adult spinal deformities: Present understanding and future perspectives. *Eur Spine J*. 2013;22(SUPPL.2).
28. Fradet L, Wang X, Crandall D, Aubin C-E. Biomechanical Analysis of Acute Proximal Junctional Failure After Surgical Instrumentation of Adult Spinal Deformity: The Impact of Proximal Implant Type, Osteotomy Procedures, and Lumbar Lordosis Restoration. *Spine Deform*. 2018 Oct;6(5):483-91.

**Citation:** Dhillon CS, Chhasatia N, Dwivedi R, Loya V. "Hybrid Posterior Instrumentation and Mini-Open Anterior Release for Treatment of Adolescent Idiopathic Scoliosis: A Retrospective Analysis". *SVOA Orthopaedics* 1:1 (2021) Pages 15-23.

**Copyright:** © 2021 All rights reserved by Dhillon CS. This is an open access article distributed under the Creative Commons Attribution License, which permits unrestricted use, distribution, and reproduction in any medium, provided the original work is properly cited.