

Capitellum Reconstruction Using Metatarsal Head Vascularized Transfer

Pilar Aparicio, FEBOT^{1*}, José Torres¹, Enric Domínguez¹, Juan Castellanos¹ and Óscar Izquierdo^{1,2}

¹ Hand and Microsurgery Unit, Orthopaedics Department, Parc Sanitari Sant Joan de Déu de Sant Boi de Llobregat, Barcelona, Spain.

² Hand and Microsurgery Unit, Egarsat, Barcelona, Spain.

*Corresponding Author: Pilar Aparicio, FEBOT, Hand and Microsurgery Unit, Orthopaedics Department, Parc Sanitari Sant Joan de Déu de Sant Boi de Llobregat, Barcelona, Spain.

DOI: <https://doi.org/10.58624/SVOAOR.2023.03.060>

Received: November 09, 2023 Published: December 15, 2023

Abstract

Treatment for the sequelae of capitellum fractures is not commonly described in the literature. We present a unique case of a capitellum reconstruction with a vascularized osseous graft from the second metatarsal bone. A woman of 53 years old fell down and presented a capitellum fracture that was fixed with two cannulated screws, after 6 months the radiograph showed signs of necrosis of the capitellum, the patient was disabled and a surgery was offered. We reconstructed her capitellum by means of a vascularized osteochondral flap from the second metatarsal bone, and end-to-side anastomosis to the radial artery was performed and two cannulated screws were used to fix the graft to the humeral lateral column. After almost two years of follow up the patient is free of pain and is able to perform the activity of the daily live. The vascularized transfer from the foot is a valid technique for the reconstruction of the capitellum in non-synthesizable fractures mainly when the lateral column of the humerus is affected. The complications in the donor site are minimal.

Keywords: Capitellum Reconstruction, Vascularized Transfer, Vascularized Osseous Graft, Capitellum Fractures

Introduction

The reconstruction of the capitellum is a challenge for the reconstructive surgeon, although the vascularized transfer of the second metatarsal has been used for the reconstruction of other joints, this is the first documented case in which the reconstruction of the capitellum is achieved through the vascularized transfer of the second metatarsal.¹⁻²

Case Presentation

A 53-year-old lady presented a comminuted capitellum fracture of her left elbow that was treated by ORIF with cannulated screws (Figure 1).

A secondary displacement of the fracture occurred post-operatively. A CT scan was performed showing a complex capitellum fracture with extension to the lateral column and with few possibilities for a synthesis ([Video 1](#)). A posterolateral instability of the elbow was also identified. A reconstructive surgery was proposed by means of the vascularized transfer of the second metatarsal.

One surgical team performed the debridement of the fracture of the capitellum through a posterior approach and prepared the radial vessels for the anastomosis. The second surgical team harvested the second metatarsal of the left foot pediculated by the pedis vessels. The transfer was performed in a free manner with an end to side anastomosis to the radial artery and an end-to-end anastomosis to the radial vein. The lateral collateral ligament was reinserted using an anchor (DePuySynthes®). The synthesis was performed using 2 cannulated screws (Figure 2). Olecranon osteotomy was fixed using a compression cannulated screw 3.5mm following AO principles.

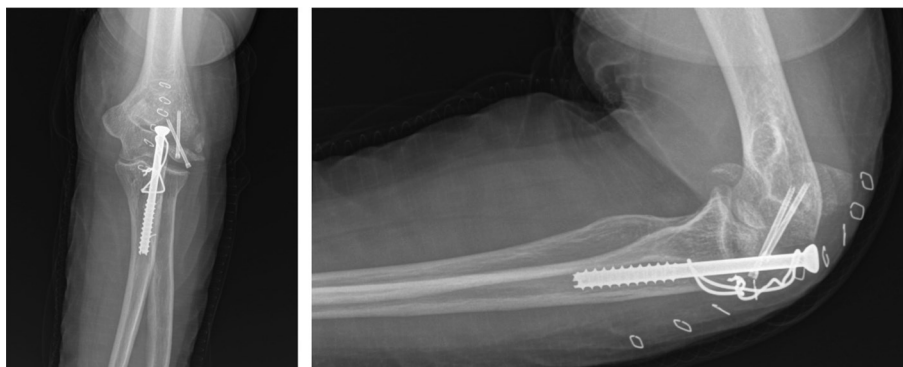


Figure 1: AP and lateral view of radiographs showing osteonecrosis of the capitellum after initial osteosynthesis.

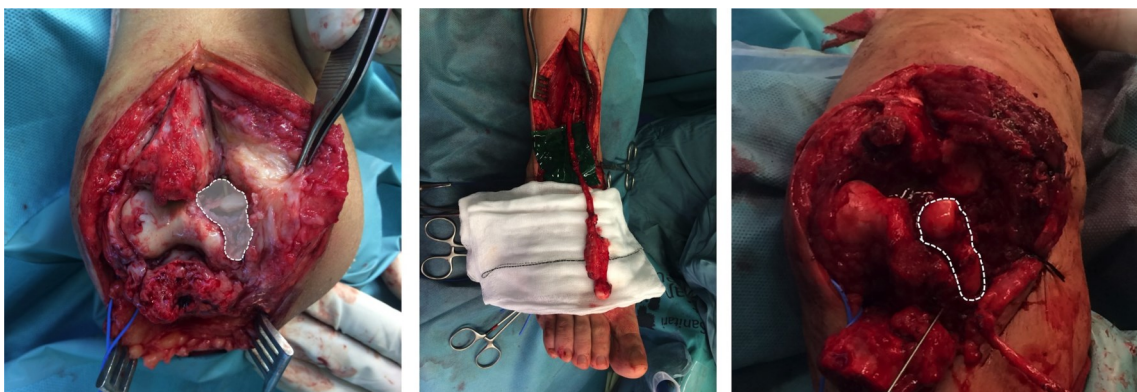

Figure 2: Intraoperative images showing the bone defect, the vascularized flap, and the finale aspect of the vascularized osteochondral flap osteosynthesis.

The patient initiated anti-reabsorptive treatment after developing osteoporosis (femoral head -2,15 and lumbar column -3.31), after three months post-operatively.

After a follow-up of 28 months, the joint balance was 120° (flexion) and -30° (extension), the pronosupination range of movement was complete and free of pain. (VAS =1). Complete stability of the elbow was achieved ([Video 2](#)).

The radiographic images demonstrated a correct integration of the vascularized flap (Figure 3).

The radiographic controls of the donor area did not objectify a developmental trend of hallux valgus and the cosmetic results were satisfactory (Figure 4), the patient exhibits a correct gait wearing a corrective orthosis.

She is able to perform her daily pleasure and working activities with no pain.

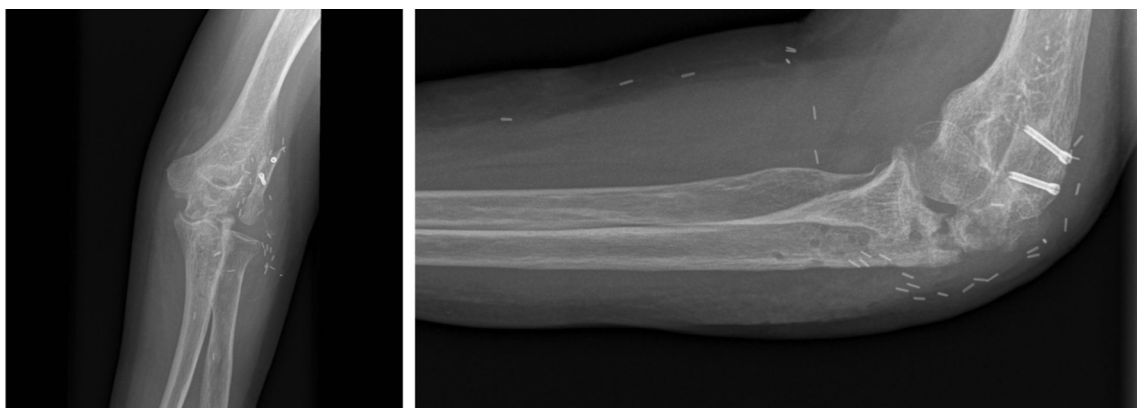


Figure 3: AP and lateral view of radiographs showing the complete integration of the flap after 28 months of follow up.

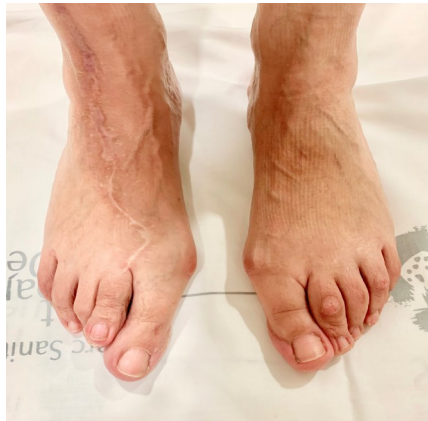

Figure 4: Clinical pictures showing the final cosmetic result at the donor site.

Discussion

A synthesis might fail due to several factors: a poor surgical technique, a low quality of bone or most of the times a combination of both. Our patient had antecedents of a previous synthesis failure (proximal humeral fracture, initially synthesized with plate and screws, and then converted to a total prosthesis of the shoulder after a hardware failure). Osteoporosis is not a contraindication for performing a synthesis¹⁻³, although this previous condition can explain the evolution of our patient.

The majority of fracture synthesis failures can be solved by means of arthrodesis, joint excision or joint replacement^{4,5}.

The replacement of the capitellum after a comminuted fracture can be done by different methods. We decided to use a vascularized transfer from the second metatarsal due to the microsurgical experience of the surgical team and the joint similarity between the capitellum and the head of the second metatarsal. According to our knowledge, the only reference of an articular reconstruction in this region by means of an osteochondral graft was provided by Bürguer through the transfer from the internal femoral condyle⁶.

We think that in this case, in which the replacement of the entire capitellum was necessary, the defect created in the knee joint would be too big. On the other hand, the high rate of re-interventions using partial elbow prostheses, lead us to choose the substitution by the second metatarsal.

Although there are several authors who published the use of metatarsal vascularized grafts for the treatment of reconstruction of upper limb joint defects⁷⁻¹⁰, this is the first documented case in which the reconstruction of the capitellum is achieved through the vascularized transfer of the second metatarsal. This technique allows the reconstruction of the humerus lateral column enabling the synthesis of the metacarpal to the humerus and the insertion of the lateral collateral ligament complex. The vascularized transfer of chondral tissue is superior to the non-vascularized one, as a result to the subchondral perfusion of the osteochondral grafts, this allows an increase in the integration rate of the graft and less local reabsorption^{11,12}.

Articular reconstruction of the capitellum allows surgery salvage in case of failure. Currently none of the available options have good outcomes. Elbow partial replacement shows a high re-intervention rates, up to 100% in some series⁵. While excision arthroplasty can lead to an elbow instability⁴.

Conclusion

The vascularized transfer from the metatarsal is a valid technique for the reconstruction of the capitellum in non-synthesizable fractures mainly when the lateral column of the humerus is affected. The complications of the donor site are minimal.

Conflict of Interest

The authors have no conflicts of interest to declare.

References

1. Edwards SG, Martin BD, Fu RH, et al. Comparison of olecranon plate fixation in osteoporotic bone: do current technologies and designs make a difference? *J Orthop Trauma*. 2011;25(5):306-311. doi:10.1097/BOT.0b013e3181f22465.
2. Miranda MA. Locking plate technology and its role in osteoporotic fractures. *Injury*. 2007;38 Suppl 3(3):S35-S39. doi:10.1016/j.injury.2007.08.009.
3. Mudgal CS, Jupiter JB. Plate fixation of osteoporotic fractures of the distal radius. *J Orthop Trauma*. 2008;22(8 Suppl):S106-S115. doi:10.1097/BOT.0b013e31815e9fcd.
4. Garner MR, Schottel PC, Hotchkiss RN, Daluiski A, Lorich DG. Capitellum Fracture Fragment Excision: a Case Series. *HSS J*. 2015;11(3):204-208. doi:10.1007/s11420-015-9452-x.
5. Rangarajan R, Papandrea RF, Cil A. Distal Humeral Hemiarthroplasty Versus Total Elbow Arthroplasty for Acute Distal Humeral Fractures. *Orthopedics*. 2017;40(1):13-23. doi:10.3928/01477447-20161227-02.
6. Higgins JP, Bürger HK. Osteochondral flaps from the distal femur: expanding applications, harvest sites, and indications. *J Reconstr Microsurg*. 2014;30(7):483-490. doi:10.1055/s-0034-1372484.
7. del Piñal F, Klausmeyer M, Moraleda E, et al. Vascularized graft from the metatarsal base for reconstructing major osteochondral distal radius defects. *Journal of Hand Surgery*. 2013;38(10):1883-1895. doi:10.1016/j.jhssa.2013.07.013.
8. Vilkki SK, Paavilainen P. Vascularized second metatarsophalangeal joint transfer for radial deficiency - an update. *The Journal of hand surgery, European volume*. 2018;43(9):907-918. doi:10.1177/1753193418793597.
9. Pallapati SCR, Thomas BP, Anderson GA. En bloc Excision and Matched Metatarsal Transfer for Expansive Benign Osteolytic Lesions of the Metacarpal. *Journal of Hand Surgery*. 2016;41(11):e417-e423. doi:10.1016/j.jhssa.2016.08.004.
10. Chen H, Yin G, Hou C, Zhao L, Lin H. Repair of a lateral malleolus defect with a composite pedicled second metatarsal flap. *J Int Med Res*. 2018;46(12):5291-5296. doi:10.1177/0300060518801461.
11. Sato K, Sasaki T, Nakamura T, Toyama Y, Ikegami H. Clinical outcome and histologic findings of costal osteochondral grafts for cartilage defects in finger joints. *Journal of Hand Surgery*. 2008;33(4):511-515. doi:10.1016/j.jhssa.2008.01.003.
12. Higgins JP, Borumandi F, Bürger HK, et al. Nonvascularized Cartilage Grafts Versus Vascularized Cartilage Flaps: Comparison of Cartilage Quality 6 Months After Transfer. *Journal of Hand Surgery*. 2018;43(2):188.e1-188.e8. doi:10.1016/j.jhssa.2017.09.014.

Citation: Izquierdo O, Aparicio P, Domínguez E, Castellanos J. Capitellum Reconstruction Using Metatarsal Head Vascularized Transfer. *SVOA Orthopaedics* 2023, 3:6, 188-191.

Copyright: © 2023 All rights reserved by Aparicio P., et al. This is an open access article distributed under the Creative Commons Attribution License, which permits unrestricted use, distribution, and reproduction in any medium, provided the original work is properly cited.