

# Therapeutic Attitude to the Seizures of an Epileptic Suffering of Malaria

Mulakwa Morisho, MD\*

*Pediatrics Department of Nyamibungu general hospital / kitutu / South-Kivu/R.D.Congo*

*\*Corresponding Author: Mulakwa Morisho, Pediatrics Department of Nyamibungu general hospital / kitutu / South-Kivu/R.D.Congo*

**Received:** May 09, 2022 **Published:** June 30, 2022

## Abstract

Epilepsy is a neurological illness touching more children. Epileptic children are particular patient, because malaria puts problems and unbalance as well as in pick-up charge. We report, the case of 8 years hold child that present, demonstrations of epileptic crises and suffering malaria. The patient treated initially by anti-convulsivant and anti-malaria as arthemeter; after 5 days of treatment, there was persisted crises and fever, quinine initiate and there was amendment. In our observation, we demonstrate and let's reveal the relation between malaria and epilepsy, in the sense of the unbalance of epileptic patient.

**Keywords:** epilepsy, malaria, crises, unbalances.

## Introduction

The epilepsy is one of the important neurological illnesses in the world notably in tropical zone, touch more-part of children. Malaria due to Plasmodium falciparum is a serious pathology of red blood cell and is influenced by certain group of age, essentially young people. Since long years, malaria is known as making part of reasons of intervening of epilepsy. (2, 4, 13, 14) Would epileptic patient be unbalanced by malaria? Little work exists in this sense, that malaria would be the origin of the unbalance or the convulsive crises for a patient known epileptic. In order to bring some elements of answers to this questioning, we led the survey. The main objective of this work, being to demonstrate the tie between these two pathologies in the sense that malaria would cause an unbalance on epileptic patient.

## Case Report

An 8 years old boy, 27kg weight body brought emergency pediatric for generalized crises, screaming with laxity sphincter in end of crises, on July 13, 2015.

He was followed in emergency as making some convulsive crises, the treatment based to diazepam was managed and the patient was kept in hospitalization. In spite of the treatment to basis of anti-convulsivant 1 day after, persisted symptoms; 2 to 3 crises by 24 hours in no fever context. Epilepsy, metabolic unrest as the hypoglycemia as well as the ionic trouble notably the hypocalcaemia has been evoked like diagnoses on July 15, 2015.

He reveals a trauma notion in birth times, 4240g a weight of birth for a term gestation age. He was hospitalized for the same types of crises in 2013 and the EEG pleads in favor of epilepsy and he had left hospital under Phenobarbital. A psychomotor stunt and an unsuccessful school life attract the attention. Other family's members were in good health.

The general state faded by the coma level II, the body temperature of 37, 2C, the cardiac frequency of 98b/min, the breath frequency 23cycles /min and the arterial pressure of 120/74mmHg. The mucosa were colored well, the cardio-pulmonary auscultation as well as the abdominal exam were without details. The neurological exams of which kernig sign and brudzinsky sign were no contributive.

## Biology Exam

The white blood cell of 5650/mm<sup>3</sup>; the lymphocyte to 36% and the neutrophilic to 64%; the hemoglobin of 9g/dl; the thick drop for a cross (either 1-9tromphons/100champs); the sedimentation speed of 32mm/h; the blood calcium of 2,3mmol/l; the blood sugar of 3,2mmol/l; the other balances were no contributive.

The simple malaria and the epilepsy have been evoked to the 2<sup>nd</sup> day of hospitalization.

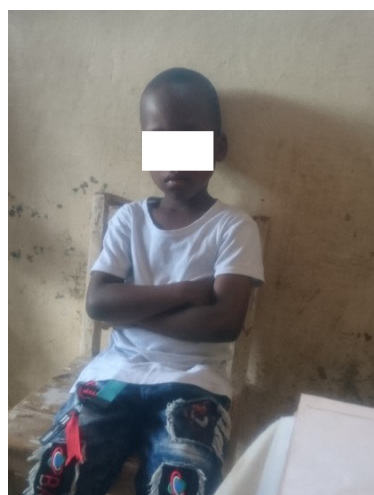We had kept the diazepam for crises, and had added Phenobarbital and the arthemeter. To the 3<sup>rd</sup> day of hospitalization, we had noted the apparition of the fever in progress in spite of the treatment.

On hospital day 4, the physical exam testifying a cerebral reach, translated by a quadriplegia following the persistence of crises under the regime, signing a pyramidal characteristic syndrome of a paralysis of TODD. The pick-up in charge adapted to Phenobarbital raised in two holds, physiotherapy, as well as the sodium valproate was added to the previous treatment.

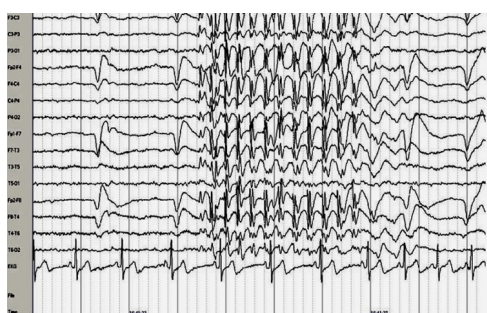
To the 5<sup>th</sup> day, we had replaced arthemeter by quinine and on day 7, we had noted the convulsive crisis disappearance even fever. As well as quadriplegia to paresis of members.

To the 10<sup>th</sup> day, we had adjusted his treatment in giving also calcium. We discharge him, on 14<sup>th</sup> day of hospitalization without effect or crises noted in hospitable environment. We continue to follow-up him, as an ambulant and making the prophylaxis of malaria.

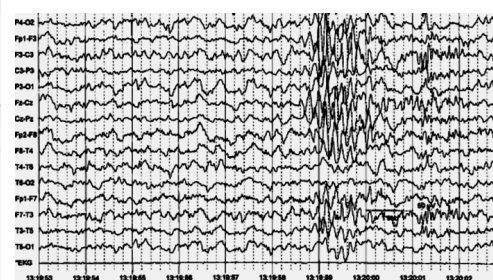
## Figures



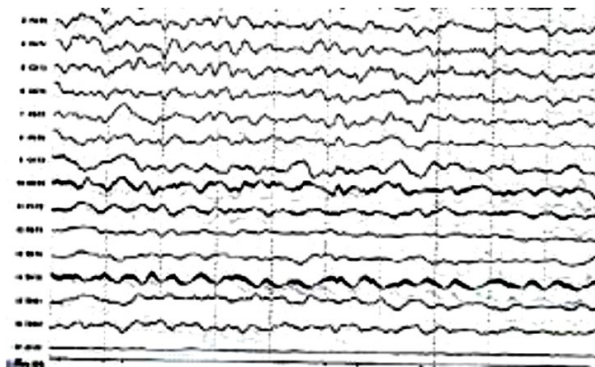
The discharging day of the patient after many seizures



epilepsy  
first EEG in 2013  
diagnosis confirmed



Typical absence epilepsy presenting  
in second EEG 2013



in 2015 the cerebral activities was low in this  
EEG examination

## Discussion

Epilepsy is a neurological mess resulting in excessive electric discharges, sudden, generally brief, in a cerebral cell group (neurons) characterized by a tendency to the recurrent crises no provoked that can gone from two to more on 24hours. (9, 10, 17, 19)

Epilepsy being a differential diagnosis of most neurological illnesses, to put it in evidence asks several investigating clinics as well as biologic exams; for our patient put aside epilepsy, malaria put problem in pick-up charge basing on parasitaemia. The definitive diagnosis of malaria in the endemic regions remains challenge in clinician's contest because there is an elevated rate of asymptomatic parasitaemia and limits facilitated diagnostic. (5)

The clinician feeling diagnosis problems has enormous problems also for management of crises owed to malaria, the first reason of the convulsive crises in emergency situation in our endemic and rural regions. These crises possessing refractory nature sometimes complicate initial pick-up charge of diazepam inducing occasionally respiratory depression.

(6)

The literature describe numerous risk factors whose malaria, can explained the intervening of epilepsy notably in tropical zone but evokes their influences anywhere for patient known epileptic. Observing malaria physiopathology, it would be origin of epilepsy and that for us; this mechanism would serve to unbalance or to maintain the unbalance of the epileptic patient either.

For Toro and Roman, among cerebral lesions describe are noted a serious vasculopathy, the generalized hemorrhages, and astroglial reactions (malarial granuloma of Durck).<sup>(15)</sup> Probably another mechanism is ischemia; indeed, it is suggested that the sequestration of red blood cell that contain parasites contributes to hypoxia, stirring an ischemia. This sequestration being multiple factor, red blood cell and tablets blood leads to micro capillary mechanical obstruction, in particular cerebral, with edema, hemorrhagic necrosis and tissues anoxia.<sup>(9,10,11,12,18)</sup> Anoxia, being to the basis of intervening of different crises causing some new ischemic lesions and to unbalance of the epileptic patient. All these lesions could be potential epileptic focus.

Neurotoxic<sup>(3,8)</sup> and immunological effects through anti- calcium channels antibodies<sup>(7)</sup> are implicated in neuropathology. The genetic factor intervention was also mentioned,<sup>(16)</sup> notably for convulsive crises.

## Conclusion

This survey brings out that malaria seems to be a frequent complication of the epileptic patient in our environment. Epilepsy being favored and maintain by several regional pathologies. Malaria is a major base of complication, of which neurological polymorphous types and intervening to the unbalance of important pathologies whose epilepsy. The rural physician limited to investigating means, are confronted to these types of reality in our regions. He will have in idea this attitude in the offing to bring an adequate pick-up charge to our epileptic patients. The survey brings a new vision of crises for epileptic patients in tropical zone. It would be important to achieve other studies in order to better quantify the part of convulsions owed to cerebral malaria in relation to simple malaria in the unbalance sense of epileptic patient.

## Conflict of Interest

The author declare of new conflict of interest.

## References

1. Arthur M, Sarah GS, Grace N, Justus B et Philip JR. Predictors of anti-convulsant treatment failure in children presenting with malaria and prolonged seizures in Kampala, Uganda. *Malaria Journal* 2009, 8:145
2. De Bittencourt PRM, Adamolekun B, Bharucha N, et al. Epilepsy in the tropics : I. Epidemiology, socioeconomic risk factors, and etiology. *Epilepsia* 1996 ; 37 : 1121-7.
3. Dobbie M, Crawley J, Waruiru C, Marsh K, Surtees R. Cerebrospinal fluid studies in children with cerebral malaria : an excitotoxic mechanism? *Am J Trop Med Hyg* 2000 ; 62 : 284-90
4. Dumas M, Leger JM, Pestre-Alexandre M. Manifestations neurologiques et psychiatriques des parasitoses. Congrès de psychiatrie et de neurologie de langue française, session LXXXIV, 23-27 juin, Le Mans (France). Paris : Masson, 1986.
5. Gretchen LB, Malcolm EM, Peter WK, Karl BS, Yamikani FC, et al. Blantyre Malaria Project Epilepsy Study (BMPES) of neurological outcomes in retinopathy-positive paediatric cerebral malaria survivors: a prospective cohort study. *Lancet Neurol* 2010; 9: 1173-81
6. Idro R, Aketch S, Gwer S, Newton CR, Maitland K: Research priorities in the management of severe *Plasmodium falciparum* malaria in children. *Ann Trop Med Parasitol* 2006, 100:95-108.
7. Lang B, Newbold CI, Williams G, Peshu N, Marsh K, Newton CR. Antibodies to voltage-gated calcium channels in children with *falciparum* malaria. *J Infect Dis* 2005; 191 : 117-21.
8. Medana IM, Hien TT, Day NP, et al. The clinical significance of cerebrospinal fluid levels of kynurenine pathway metabolites and lactate in severe malaria. *J Infect Dis* 2002; 185: 650-6.
9. Ngoungou EB, Dulac O, Poudiougou B, et al. Epilepsy as a consequence of cerebral malaria in area in which malaria is endemic in Mali, West Africa. *Epilepsia* 2006; 47: 873-9.
10. Ngoungou EB, Koko J, Druet-Cabanac M, et al. Cerebral malaria and sequelar epilepsy: First matched case-control study in Gabon. *Epilepsia* 2006; 47: 2147-53.

11. Newton CR, Krishna S. Severe falciparum malaria in children: current understanding of pathophysiology and supportive treatment. *Pharmacol Ther* 1998; 79: 1-53.
12. Newton CRJC, Hien TT, White N. Neurological aspects of Tropical disease-Cerebral Malaria. *J Neurol Neurosurg Psychiatry* 2000; 69: 433-41.
13. Preux PM, Druet-Cabanac M, Debrock C, Tapie P, Dumas M, Comité de recherche et le Comité de recherche sur l'épilepsie de l'institut d'Épidémiologie neurologique et de Neurologie tropicale de Limoges. Questionnaire d'investigation de l'épilepsie dans les pays tropicaux. *Bull Soc Pathol Exot* 2000; 93: 276-8.
14. Preux PM, Druet-Cabanac M. Epidemiology and etiology of epilepsy in sub-Saharan Africa. *Lancet Neurol* 2005; 4: 21-31.
15. Toro G, Roman G. Cerebral malaria. A disseminated vasculomyelinopathy. *Arch Neurol* 1978; 35: 271-5.
16. Versteeg AC, Carter JA, Dzombo J, Neville BG, Newton CR. Seizure disorders among relatives of Kenyan children with severe falciparum malaria. *Trop Med Int Health* 2003; 8: 12-6.
17. World Health Organization (WHO). Severe falciparum malaria. Communicable diseases cluster. *Trans R Soc Trop Med Hyg* 2000; 94 (Suppl. 1): 1-90.
18. [www.laconferencehippocrate.com/](http://www.laconferencehippocrate.com/) february 11, 2005
19. [www.who.int/malaria/fr/](http://www.who.int/malaria/fr/) november 25, 2015

**Citation:** Morisho M. "Therapeutic Attitude to the Seizures of an Epileptic Suffering of Malaria". *SVOA Paediatrics* 2022, 1:3, 86-89.

**Copyright:** © 2022 All rights reserved by Morisho M., et al. This is an open access article distributed under the Creative Commons Attribution License, which permits unrestricted use, distribution, and reproduction in any medium, provided the original work is properly cited.